

# Coronectomy: A Technique to Protect the Inferior Alveolar Nerve

*M. Anthony Pogrel, DDS, MD,\* J.S. Lee, DDS, MD, MS,† and D.F. Muff, DDS, MD‡*

**Purpose:** Damage to the inferior alveolar nerve when extracting lower third molars is often caused by the intimate relationship between the nerve and the roots of the teeth. The technique of coronectomy, or intentional root retention, may minimize this problem.

**Patients and Methods:** Forty-one patients underwent coronectomy on 50 lower third molars with follow-up of at least 6 months. The technique of coronectomy deliberately protected the lingual nerve as part of the surgical procedure. All roots were left at least 3 mm below the buccal and lingual plates of bone. All patients were radiographed preoperatively, immediately postoperatively, and after 6 months.

**Results:** There were no cases of inferior alveolar nerve-involved damage in this study of 41 patients who underwent 50 coronectomies. There was 1 case of transient lingual nerve involvement, probably from the use of the lingual retractor. One patient required subsequent removal of the roots of both lower third molars because of failure to heal, and 1 patient required subsequent removal of a root because of subsequent migration to the surface. Root migration was noted in approximately 30% of patients over a 6 month period.

**Conclusion:** Coronectomy appears to be a viable technique in those cases where removal of the whole tooth might put the inferior alveolar nerve at considerable risk of damage. The technique appears to be associated with a low incidence of complications, but subsequent migration of the roots may be an issue in the long term.

© 2004 American Association of Oral and Maxillofacial Surgeons  
*J Oral Maxillofac Surg* 62:1447-1452, 2004

The relationship between the roots of mandibular teeth and the inferior alveolar nerve can often be assessed radiographically, particularly with a panoramic radiograph.<sup>1-3</sup> Computed tomography scanning can be used to visualize the relationship in the third dimension.<sup>4,5</sup> With the combination of these techniques it can be ascertained which teeth may represent the greatest risk to the inferior alveolar nerve upon removal. The third molar is the tooth that is usually involved, but occasionally the second molar

and even the first molar roots can be in close relationship to the inferior alveolar nerve. The technique of coronectomy, or deliberate vital root retention, has been proposed as a means of removing the crown of a tooth but leaving the roots, which may be intimately related with the inferior alveolar nerve, untouched so that the possibility of nerve damage is reduced.<sup>6-11</sup>

## Patients and Methods

Forty-one patients underwent coronectomy as a procedure to remove the crown and upper third of the roots of a lower third molar to reduce the risk of damage to the inferior alveolar nerve. This technique was used when there was radiographic evidence of a close relationship between the roots of the tooth and the inferior alveolar nerve. Cases showing active infection or tooth mobility were excluded.

### SPECIFIC TECHNIQUE

The intention of coronectomy or deliberate root retention is that the part of the root intimately related to the inferior alveolar nerve is undisturbed. However,

Received from the Department of Oral and Maxillofacial Surgery, University of California, San Francisco, San Francisco, CA.

\*Professor and Chairman.

†Assistant Professor of Clinical Oral and Maxillofacial Surgery.

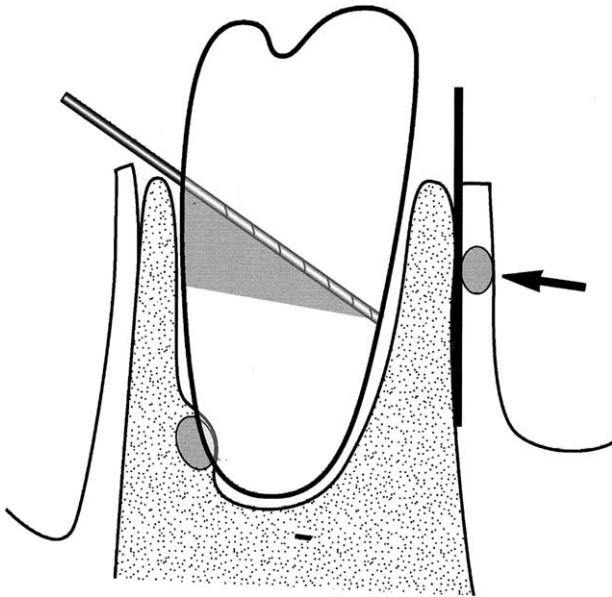
‡Assistant Clinical Professor.

Address correspondence and reprint requests to Dr Pogrel: Department of Oral and Maxillofacial Surgery, University of California San Francisco, Box 0440, 521 Parnassus Ave, San Francisco, CA 94143-0440; e-mail: map@itsa.ucsf.edu

© 2004 American Association of Oral and Maxillofacial Surgeons

0278-2391/04/6212-0002\$30.00/0

doi:10.1016/j.joms.2004.08.003



**FIGURE 1.** Diagram showing the technique for removal of the lower right third molar. Note angle of the bur at approximately 45° and lingual retractor protecting the lingual nerve (arrow). Shaded area of root on buccal side to be removed secondarily.

*Pogrel, Lee, and Muff. Coronectomy. J Oral Maxillofac Surg 2004.*

enough of the root must be removed below the crest of the lingual and buccal plates of bone to enable bone to form over the retained roots as part of the normal healing process. It was also felt to be important not to mobilize the roots because they might damage the nerve and then become mobile foreign bodies, and for this reason complete transection of the crown and roots of the tooth was felt to be necessary.

The technique used is as follows:

1. All patients were placed on appropriate preoperative prophylactic antibiotics.
2. A conventional buccal flap with releasing incision was raised, elevated, and retained with a Minnesota retractor.
3. A lingual flap was raised and the lingual tissues retracted and an appropriate lingual retractor, such as a Walter's lingual retractor,<sup>12</sup> was placed to protect the lingual nerve.
4. Using a 701-type fissure bur, the crown of the tooth was transected at an angle of approximately 45° (Fig 1). The crown was totally transected so that it could be removed with tissue forceps alone and did not need to be fractured off the roots. This minimizes the possibility of mobilizing the roots. However, the lingual retractor is essential during this technique because the lingual plate of bone can be inadvertently perforated (Fig 2), and otherwise the lingual nerve would be at risk.

Following removal of the crown of the tooth, the fissure bur is used to reduce the remaining root fragments so that the remaining roots are at least 3 mm below the crest of the lingual and buccal plates in all places (this involves removing the shaded portion in Fig 3).

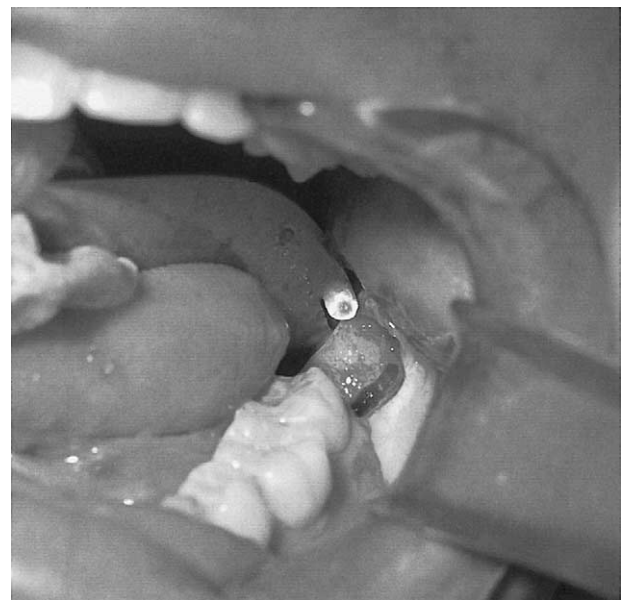
An alternative technique is to use a round bur from a superior aspect and remove the crown and superior part of the roots by drilling it away. In this case, only minimal lingual retraction may be required.

5. There is no attempt at root canal treatment or any other therapy to the exposed vital pulp of the tooth.
6. Following a periosteal release, a watertight primary closure of the socket is performed with 1 or more vertical mattress sutures.

Radiographs were taken preoperatively, immediately postoperatively, and 6 months postoperatively.

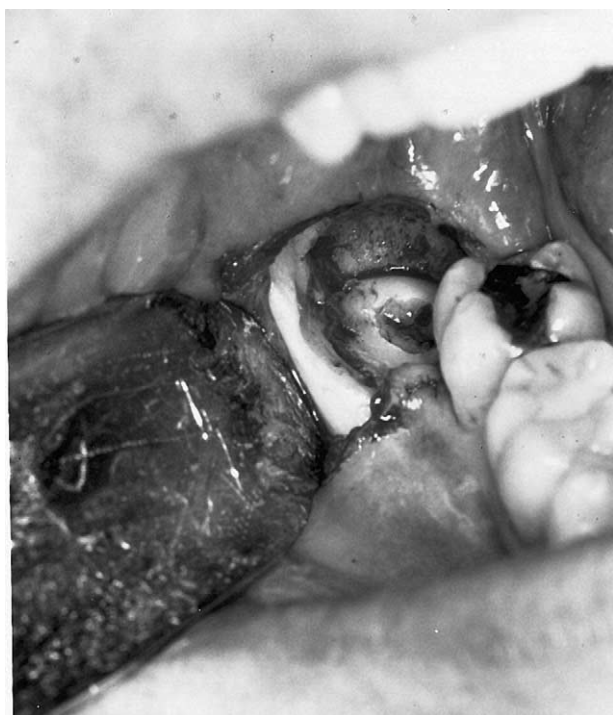
## Results

Forty-one patients were enrolled in this study, with a total of 50 lower third molars. Forty-eight sites healed primarily, but in 1 case the sockets on both sides opened and failed to close secondarily. In this case, the root fragments were later removed and found to be mobile. A typical preoperative and postoperative radiograph is shown in Figure 4. At the 6-month stage, most radiographs do appear to show



**FIGURE 2.** Drill marks through the lingual plate after sectioning the crown. The lingual nerve is protected by the lingual retractor.

*Pogrel, Lee, and Muff. Coronectomy. J Oral Maxillofac Surg 2004.*



**FIGURE 3.** Completed coronectomy on lower right third molar. Note retained roots are 3 mm below the crest of bone and exposed pulp is untreated.

*Pogrel, Lee, and Muff. Coronectomy. J Oral Maxillofac Surg 2004.*

bone formation having occurred superior to the retained root fragment (Fig 5). However, this was not confirmed clinically. Examination of immediate postoperative radiographs and radiographs taken at 6 months, however, do show that in 15 cases the root fragments have migrated by a typical distance of 2 to 3 mm (Fig 6). In all cases the root fragments moved further away from the inferior alveolar nerve, and intact bone could be visualized between the remaining root fragments and the inferior alveolar nerve. In only 1 case has a retained root had to be removed subsequently because of migration, and this case is illustrated in Figure 7. Residual root movement was unpredictable and Figure 8 shows a case of bilateral coronectomy where the left root migrated but the right one did not. There were no cases of inferior alveolar nerve involvement during the course of this study, but there was 1 case of mild, transient (5 days) lingual paresthesia, presumably from the lingual retraction.

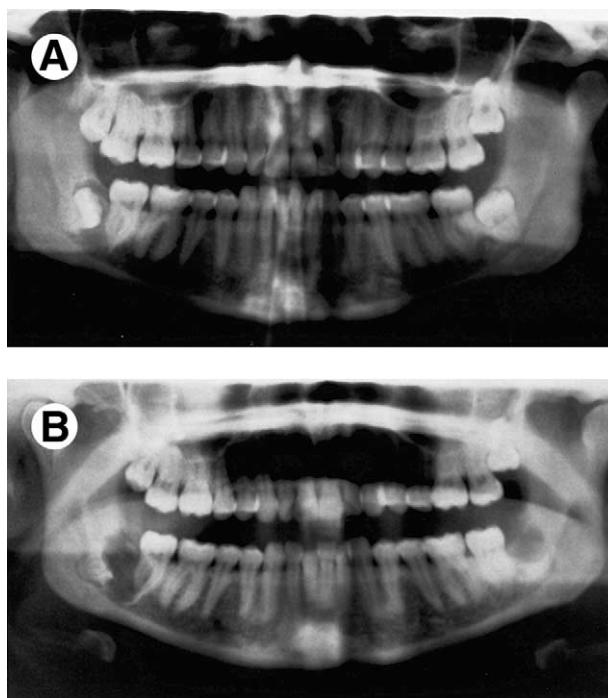
In summary, of 50 retained roots 3 (6%) have required subsequent removal and 15 (30%) have shown radiographic evidence of migration over the course of this study. However, the longest follow-up is 42 months and the mean follow-up period is 22 months; a longer follow-up period may show more residual roots requiring removal.

## Discussion

The issue of inferior alveolar nerve involvement during the removal of lower third molars is a clinical and medicolegal problem. Any technique that can reduce the possibility of this involvement is worthy of exploration. The technique of coronectomy, or deliberate root retention, has been studied intermittently in the past, but has no strong body of support.

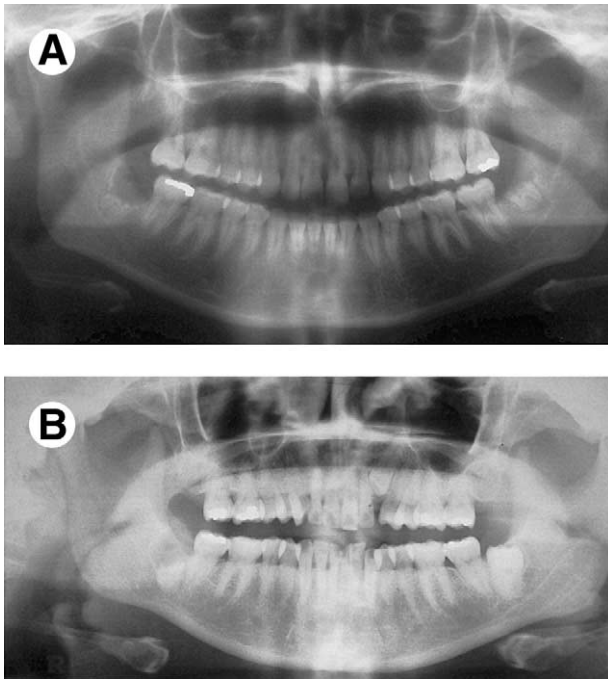
It does seem appropriate that if this technique is to be performed, the following rules appear sensible:

1. Teeth with active infection around them, particularly infection involving the root portion, should be excluded from this technique.
2. Teeth that are mobile should be excluded from this technique because it might be felt that the roots may act as a mobile foreign body and become a nidus for infection or migration.
3. Teeth that are horizontally impacted along the course of the inferior alveolar nerve may be unsuitable for this technique because sectioning of the tooth itself could endanger the nerve (see Fig 9). The technique is therefore better utilized for vertical, mesioangular, or distoangular impactions where the sectioning itself does not endanger the nerve.



**FIGURE 4.** A, Preoperative radiograph of bilaterally impacted lower third molars (lower right third molar had an associated cyst). B, Postoperative view showing retained root fragments.

*Pogrel, Lee, and Muff. Coronectomy. J Oral Maxillofac Surg 2004.*



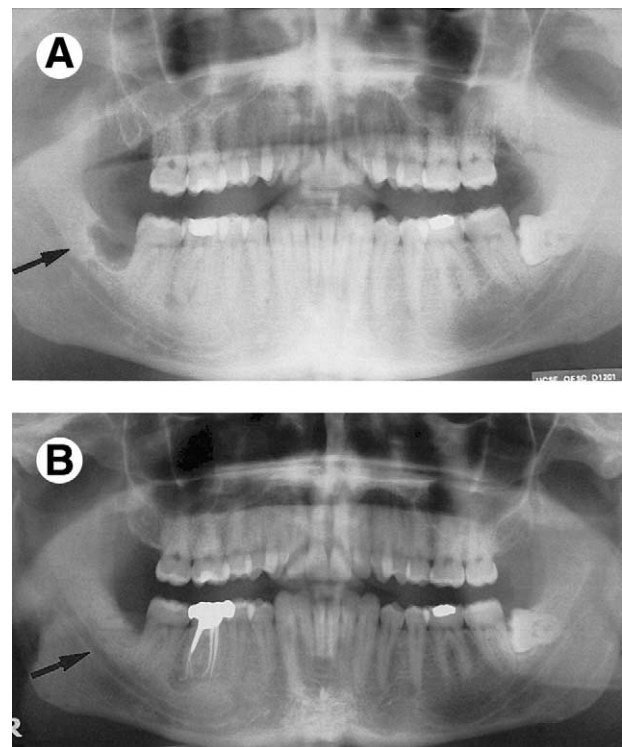
**FIGURE 5.** A, Radiograph of lower right third molar immediately postoperatively and B, radiograph 6 months following coronectomy showing bone formation over the retained root of lower right third molar.

*Pogrel, Lee, and Muff. Coronectomy. J Oral Maxillofac Surg 2004.*

4. There does not appear to be any need to treat the exposed pulp of the tooth and root treatment appears to be contraindicated.<sup>13-16</sup> Animal studies have shown that vital roots remain vital with minimal degenerative changes. Osteocementum usually extends to cover the roots.
5. The technique of leaving the retained root fragment at least 3 mm inferior to the crest of bone seems appropriate and does appear to encourage bone formation over the retained root fragment. This distance of 2 to 3 mm has been validated in animal studies.<sup>13-15</sup>
6. Late migration of the root fragment does appear to occur in some cases, but is unpredictable. However, in all cases the root fragments move into a safer position with regard to the nerve, and it can be envisaged that should removal ever become necessary the nerve would not then be at high risk. The authors are aware of anecdotal reports from colleagues of retained root fragments migrating right up to the surface of the mucosa and appearing through the mucosa and requiring removal. This happened only once in the present study, but at least the root fragments are mobile and easy to remove without complication and without risk to the nerve. It is possible that roots will migrate more

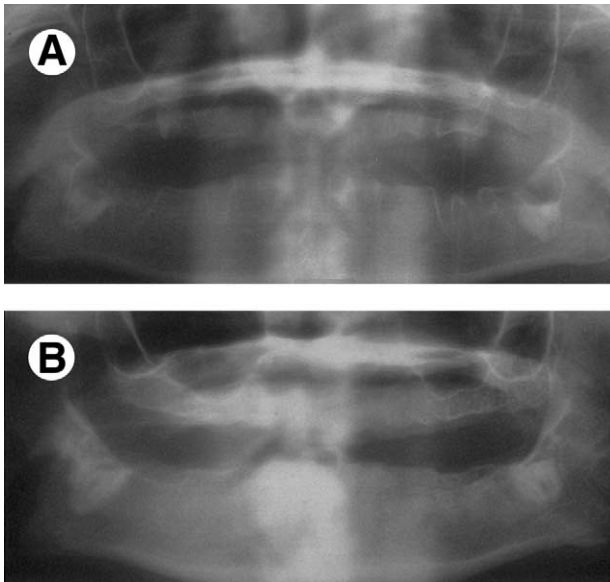
if they are mobilized in any way during the initial surgical procedure.

One difficulty with regard to a study such as this is the decision as to which patients are at risk and whom to perform this technique on. In the end it is a personal decision between the surgeon and the patient. Previous studies evaluating the risk of inferior alveolar nerve damage with third molar extraction have relied on either periapical or panorex radiographs.<sup>1-3</sup> Rood and Shehab<sup>3</sup> suggested that diversion of the inferior alveolar canal, darkening of the root interruption of the white line of the canal, narrowing of the canal, and deflection of the root were indicators of possible nerve injury. In their prospective study of 125 teeth with signs suggesting an increased risk of nerve involvement, 14% developed nerve injury. Similarly, Blaeser et al,<sup>2</sup> in their study, showed that when increased risk factors are shown on a panorex radiograph, the incidence of nerve involvement may rise from a background risk of 1% to between 1.7 and 12%. The advent of low dose cone beam computed tomography technology, which is now becoming readily available in a dental outpatient setting,<sup>17-19</sup> should provide a much more accurate prediction of the likelihood of nerve injury, and in cases where the pan-



**FIGURE 6.** A, Radiograph immediately after coronectomy. Retained apices on right (arrow). B, Radiograph 6 months postoperatively showing that roots have migrated 2 to 3 mm away from the inferior alveolar nerve (arrow).

*Pogrel, Lee, and Muff. Coronectomy. J Oral Maxillofac Surg 2004.*

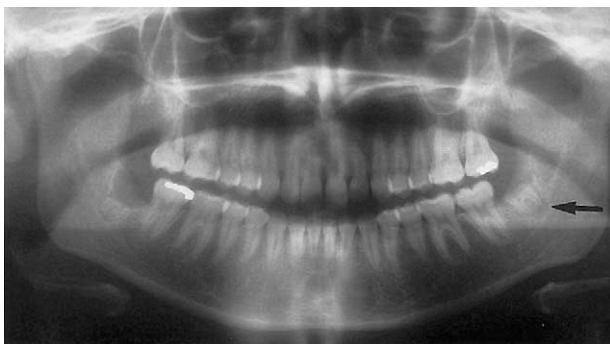

**FIGURE 7.** A, Radiograph immediately postoperatively showing position of retained root fragment. B, Appearance 6 months later as the roots of the lower right third molar erupted into the oral cavity, necessitating removal.

*Pogrel, Lee, and Muff. Coronectomy. J Oral Maxillofac Surg 2004.*

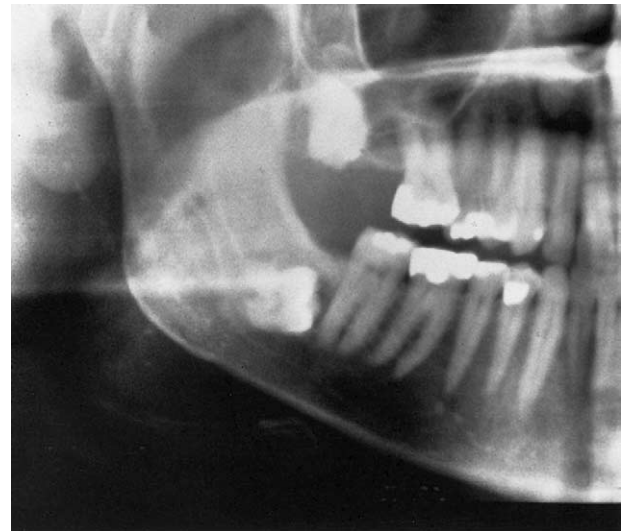
orex radiograph suggests an increased risk of nerve involvement, the use of cone beam computed tomography technology may be indicated to assess the exact relationship in 3 dimensions. When it is seen that there is truly an intimate anatomic relationship between the nerve and the tooth in 3 dimensions, coronectomy may be a useful option.

There are currently no standards regarding the timing and frequency of follow-up of patients having coronectomy. At the present time, we are taking radiographs immediately postoperatively and 6 months postoperatively. Later radiographs are taken if the patient becomes symptomatic. We would not advocate seeing the patient after 6 months unless he or she becomes symptomatic,



**FIGURE 8.** Appearance 3 months after bilateral coronectomy showing migration on the left side (arrow) but not on the right.

*Pogrel, Lee, and Muff. Coronectomy. J Oral Maxillofac Surg 2004.*



**FIGURE 9.** Radiograph of a horizontally impacted lower right third molar where coronectomy would be contraindicated because sectioning the crown would endanger the inferior alveolar nerve.

*Pogrel, Lee, and Muff. Coronectomy. J Oral Maxillofac Surg 2004.*

though for research purposes patients may need to be followed and radiographed for longer periods.

## References

1. Howe G, Poynton HG: Prevention of damage to the inferior alveolar nerve during the evaluation of mandibular third molars. *Br Dent J* 109:355, 1960
2. Blaeser BF, August MA, Donoff RB, et al: Panoramic radiographic risk factors for inferior alveolar nerve injury after third molar extraction. *J Oral Maxillofac Surg* 61:417, 2003
3. Rood JP, Shehab BA: The radiological prediction of inferior alveolar nerve injury during third molar surgery. *Br J Oral Maxillofac Surg* 28:20, 1990
4. Pawelzik J, Cohnen M, Willers R, et al: A comparison of conventional panoramic radiographs with volumetric computed tomography images in the preoperative assessment of impacted mandibular third molars. *J Oral Maxillofac Surg* 60:979, 2002
5. Freisfeld M, Drescher D, Kobe D, et al: Assessment of the space for the lower wisdom teeth. Panoramic radiography in comparison with computed tomography. *J Orofac Orthop* 59:17, 1998
6. Knutsson K, Lysell L, Rohlin M: Postoperative status after partial removal of the mandibular third molar. *Swed Dent J* 13:15, 1989
7. Freedman GL: Intentional partial odontectomy: Report of case. *J Oral Maxillofac Surg* 50:419, 1992
8. Freedman GL: Intentional partial odontectomy: Review of cases. *J Oral Maxillofac Surg* 55:524, 1997
9. Zola MB: Avoiding anesthesia by root retention. *J Oral Maxillofac Surg* 51:954, 1993
10. Alantar A, Roisin-Chausson MH, Commissionat Y, et al: Retention of third molar roots to prevent damage to the inferior alveolar nerve. *Oral Surg Oral Med Oral Pathol Oral Radiol Endod* 80:126, 1995
11. O'Riorden B: Uneasy lies the head that wears a crown. *Br J Oral Maxillofac Surg* 35:209, 1997
12. Walters H: Reducing lingual nerve damage in third molar surgery: A clinical audit of 1350 cases. *Br Dent J* 178:140, 1995
13. Johnson DL, Kelly JF, Flinton RJ, et al: Histologic evaluation of vital root retention. *J Oral Surg* 32:829, 1974

14. Whitaker DD, Shankle RJ: A study of the histologic reaction of submerged root segments. *Oral Surg Oral Med Oral Pathol* 37:919, 1974
15. Plata RL, Kelln EE, Linda L: Intentional retention of vital submerged roots in dogs. *Oral Surg Oral Med Oral Pathol* 42:100, 1976
16. Cook RT, Hutchens LH, Burkes EJ: Periodontal osseous defects associated with vitally submerged roots. *J Periodontol* 48:249, 1977
17. Danforth RA, Peck J, Hall P: Cone beam volume tomography: An imaging option for diagnosis of complex mandibular third molar anatomical relationships. *J Calif Dent Assoc* 31:847, 2003
18. Hatcher DC, Dial C, Mayorga C: Cone beam CT for pre-surgical assessment of implant sites. *J Calif Dent Assoc* 31:825, 2003
19. Danforth RA: Cone beam volume tomography: A new digital imaging option for dentistry. *J Calif Dent Assoc* 31:814, 2003