



David H Felix



Jane Luker



Crispian Scully

This series provides an overview of current thinking in the more relevant areas of Oral Medicine, for primary care practitioners.

The series gives the detail necessary to assist the primary dental clinical team caring for patients with oral complaints that may be seen in general dental practice. Space precludes inclusion of illustrations of uncommon or rare disorders.

Approaching the subject mainly by the symptomatic approach, as it largely relates to the presenting complaint, was considered to be a more helpful approach for GDPs rather than taking a diagnostic category approach. The clinical aspects of the relevant disorders are discussed, including a brief overview of the aetiology, detail on the clinical features and how the diagnosis is made, along with guidance on management and when to refer, in addition to relevant websites which offer further detail.

# Oral Medicine: 13. Lumps and Swellings: Jaws

Specialist referral may be indicated if the Practitioner feels:

- The diagnosis is unclear;
- A serious diagnosis is possible;
- Systemic disease may be present;
- Unclear as to investigations indicated;
- Complex investigations unavailable in primary care are indicated;
- Unclear as to treatment indicated;
- Treatment is complex;
- Treatment requires agents not readily available;
- Unclear as to the prognosis;
- The patient wishes this.

## Disorders in the jaws

Many diseases of, or in, the jaws present asymptotically, as *radiolucencies*, *radio-opacities* or with mixed appearances on radiographs. Other presentations are as *swellings*, *pain* or sometimes *fracture* or *disturbance of tooth eruption* (displaced, missing or loose teeth). Swellings that appear to originate from the jaws may arise

**David H Felix**, BDS, MB ChB, FDS RCS(Eng), FDS RCPS(Glasg), FDS RCS(Ed), FRCP(Edin), Postgraduate Dental Dean, NHS Education for Scotland, **Jane Luker**, BDS, PhD, FDS RCS, DDR RCR, Consultant and Senior Lecturer, University Hospitals Bristol NHS Foundation Trust, Bristol, **Professor Crispian Scully**, CBE, MD, PhD, MDS, MRCS, BSc, FDS RCS, FDS RCPS, FFD RCSI, FDS RCSE, FRCPath, FMedSci, FHEA, FUCL, DSc, DChD, DMed(HC), Dr HC, Emeritus Professor, University College London, Hon Consultant UCLH and HCA, London, UK.

from subcutaneous tissues or bones. The mnemonic MINT aids diagnosis:

**M**alformations, eg tori and fibro-osseous lesions.

**I**nflammatory conditions, eg odontogenic infections, osteomyelitis, actinomycosis, tuberculosis, or syphilis.

**N**eoplasms and cysts (see below).

**T**rauma causing subperiosteal haematomas.

Investigations largely involve imaging, and serum calcium, phosphate, and alkaline phosphatase levels but histopathology is almost invariably required.

### Pseudo-diseases

Some jaw conditions are 'pseudo-diseases', including: unerupted teeth, tori (Figures 1–3), bone marrow defects, traumatic bone cyst, Stafne bone defect (static bone cyst), osteosclerosis, pseudocyst of maxillary sinus, or sub-pontic osseous hyperplasia.

A number of bone diseases may also affect the jaws.

### Non-neoplastic diseases

- *Arteriovenous malformations.*

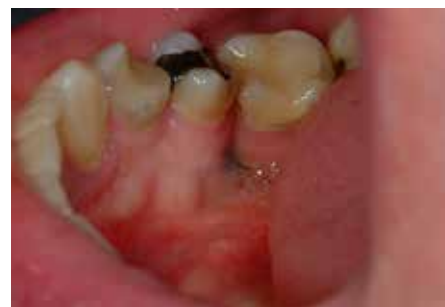

Figure 1. Torus mandibularis.

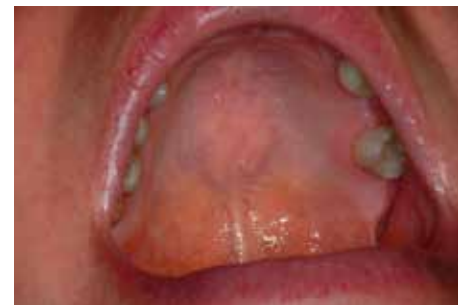

Figure 2. Torus palatinus.

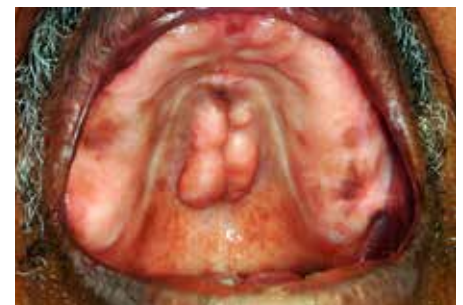

Figure 3. Torus palatinus.

- *Central giant cell lesion.*
- *Fibro-osseous lesions.*
- *Infections* (eg osteomyelitis).
- *Metabolic bone disorders* (eg osteomalacia, hyperparathyroidism).
- *Osteonecrosis.* Osteoradionecrosis (ORN) and bisphosphonate-related osteochemonecrosis of the jaws (BRONJ) are uncommon complications of radiation therapy of head and neck tumours, and bisphosphonate use (especially when given intravenously), respectively. The bone repair response is impaired by these therapies, and surgical interventions (eg tooth extraction) may precipitate the osteonecrosis. Early findings on DPT and CT are sclerosis commonly affecting the alveolar margin,

thickening of lamina dura and poor healing or non-healing of extraction sockets. When established, osteonecrosis can be demonstrated on plain radiography and CT as mixed sclerosis and lysis, sequestra, bone fragmentation, soft-tissue swelling and pathological fracture.

■ **Osteopetrosis.** A rare syndrome caused by osteoclast defects, this presents with excessive bone calcification, causing a marble like radio-opacity of the skeleton, and multiple fractures. Complications may also include jaw osteomyelitis, especially in the mandible (in 10%), anaemia, hepatomegaly, and cranial nerve compression. Investigations include radiography and blood tests (low blood calcium, and often raised serum phosphatase). Management with vitamin D (calcitriol), gamma interferon, erythropoietin and corticosteroids may help.

**Neoplastic disorders**

■ **Bone neoplasms** (Table 1).

■ **Ewing sarcoma.** This is a rare malignant round-cell tumour of young males mainly, affecting bones and soft tissues, presenting as a radiolucent lesion with a lamellated or 'onion skin' type of periosteal reaction. It is positive for CD99 (Cluster of Differentiation 99) marker. As many as 30% have metastasized by the time of presentation. Chemotherapy gives a five-year survival for localized disease up to 80% but only one third of this if metastasized.

■ **Langerhans' cell histiocytoses (LCH)** or granulomatosis. Histiocytic disorders are divided into:

- (1) dendritic cell histiocytosis;
- (2) erythrophagocytic macrophage disorders; and
- (3) malignant histiocytosis.

LCH belongs in the first group and encompasses a number of rare diseases associated with a reactive increase in bone marrow-derived Langerhans cells (histiocytes – activated dendritic cells and macrophages) in the bone marrow, and sometimes in skin and other organs, they can behave like malignant diseases. Major categories include:

- **Eosinophilic granuloma.** Solitary, indolent and chronic, bone involvement.

- **Hand-Schuller-Christian disease.**

An intermediate form with multiple bone involvement, with or without skin involvement, characterized by multifocal, chronic involvement – classically the triad of diabetes insipidus, proptosis and lytic bone lesions.

- **Letterer-Siwe disease.** Acute fulminant, disseminated multiple organ involvement with bone and liver lesions.

■ **Leukaemias.** Any of the five leukocyte types can be affected by malignant change-leukaemia. The malignant leukocytes are dysfunctional (predisposing the patient to infections), and crowd other cells out of the bone marrow, so that frequently not enough normal blood cells are made. This leads to anaemia, because red cell production is impaired, and to excessive bleeding and bruising as platelets are impaired. Patients with leukaemia present therefore with anaemia, bruising and bleeding and liability to infections. Jaw involvement may include pain and swelling, or sensory disturbances. Imaging may confirm osteolytic lesions; expanded, coarse marrow spaces and trabeculae; alveolar bone destruction; loss of lamina dura and border of developmental dental crypts; and a periosteal reaction with an 'onion skin' effect.

■ **Myelodysplastic Syndrome (MDS).**

Diseases also characterized by abnormal bone marrow cell production and not enough normal blood cells are made, leading to anaemia, infection, excessive bleeding and bruising. MDS are, in essence, pre-leukaemia and leukaemia may result.

■ **Myeloproliferative disorders (MPD).** Diseases characterized by overproduction of precursor (immature form) marrow cells.

■ **Aplastic anaemia.** Associated with loss of cell precursors (usually erythrocytes) due to stem cell defects or injuries to the marrow environment.

■ **Lymphomas.** Malignant diseases of lymphocytes, lymphomas and other cancers that spread into the bone marrow can affect cell production. Clinical presentation includes ill-defined radiolucencies in bone.

■ **Metastases.** The most frequent sites of primary neoplasms resulting in metastases are kidney, lung, breast, colon, prostate and stomach. Metastases to the jaws are rare, usually to the posterior mandible, and typically manifest with pain and swelling, or sensory disturbances. Not uncommon are loosening of teeth, pathologic jaw fracture, or intraosseous lesions with lytic, ill-defined radiolucencies.

■ **Plasma cell disorders.** These conditions (eg multiple myeloma) associated with overproduction of a B lymphocyte clone and its antibody, may affect the jaws. Radiographic findings include: sharply defined radiolucencies, usually of many bones; absence of marginal hyperostosis or opaque lining.

**Fibro-osseous lesions**

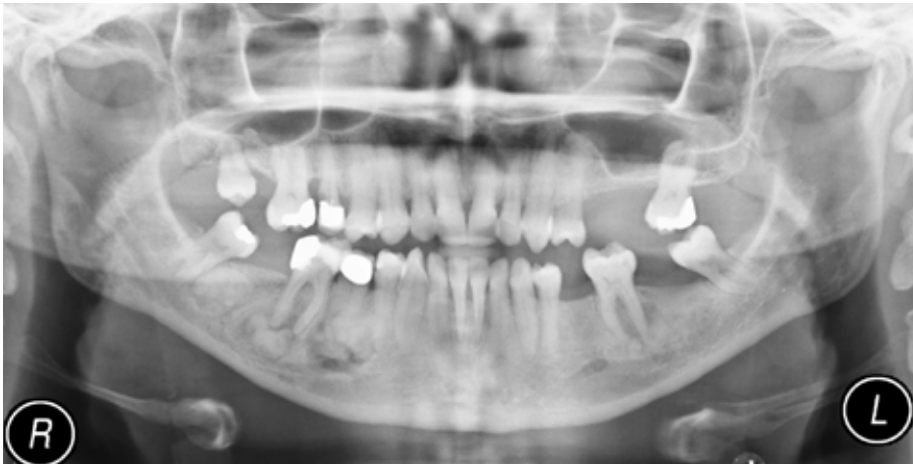Fibro-osseous lesions are a group of conditions characterized by replacement of normal bone by a

Benign	Malignant
Chondroma	Chondrosarcoma
Osteoblastoma	Osteosarcoma
Osteochondroma	
Osteoma	

**Table 1.** Bone neoplasms.

■ Cemento-osseous dysplasia
■ Cherubism
■ Fibrous dysplasia
■ Hypercementosis
■ Ossifying fibroma
■ Paget's disease of bone

**Table 2.** Fibro-osseous dysplasia.



**Figure 4.** Osseous dysplasia florid type. DPT showing multiple periapical radiolucencies with central opacities of similar density to bone/cementum. Teeth vital.

proliferating fibrous stroma which forms varying amounts of woven bone spicules and cementum-like material (Table 2).

#### Cemento-osseous dysplasia

Cemento-osseous dysplasia (COD), periapical cemental or cemento-osseous dysplasia (PCD) or cementoma is an older term)

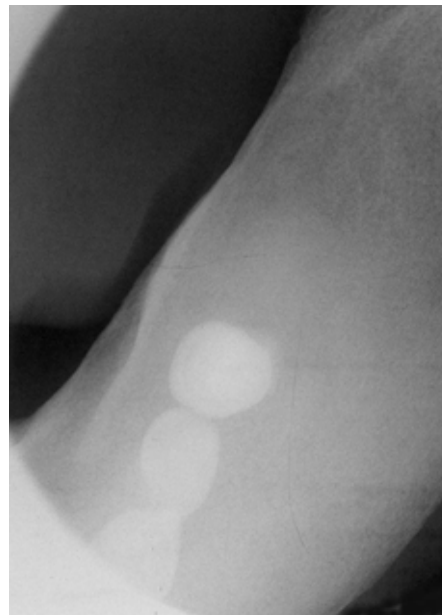
Cemento-osseous dysplasia is a fibro-osseous lesion common in black females during fourth and fifth decades, presenting with radiolucent and radio-opaque lesions at the apices of vital teeth (periapical type), which may be isolated (focal) or multi-quadrant (florid) (Figure 4). Lesions usually involve the mandibular anterior teeth, start as well-circumscribed radiolucent lesions and progressively become radio-opaque centrally, although a thin radiolucent margin is usually visible (helpful in distinguishing from enostosis [idiopathic osteosclerosis]). The lesions are asymptomatic, usually incidental radiographic findings, and the related teeth are vital. Florid COD is probably a widespread form, also occurring mainly in black females but usually affecting three or four quadrants. Bone expansion may occur, and the lesions may present with pain. Bone cysts may develop, and there is a liability to osteomyelitis. Sometimes COD occurs as isolated lesions unassociated with teeth (focal cemento-osseous dysplasia).

COD is self-limiting, so treatment is best limited to symptomatic

relief of active infection and localized sequestration. In some cases of florid COD, surgical removal may be required.

#### Cherubism

The name for this comes from the appearance of angelic putti (chubby boys) in Renaissance art, misnamed by



**Figure 5.** Lower occlusal view showing expansion of the mandible with loss of corticomedullary differentiation and a homogeneous bone pattern (ground glass) associated with fibrous dysplasia.

some as cherubs. The mandible in particular is replaced with excessive fibrous tissue which usually resolves as the child matures. Rarely it causes premature loss of primary and uneruption of permanent teeth. Though sometimes named familial fibrous dysplasia of the jaws, cherubism is an autosomal dominant condition involving the SH3BP2 gene and has little in common with fibrous dysplasia.

#### Fibrous dysplasia

Fibrous dysplasia (FD) is a self-limiting, fibro-osseous lesion caused by mutation in the gene encoding G protein (GNAS1). FD usually affects only one bone (monostotic: about 70%) but occasionally several bones (polyostotic). Maxillofacial fibrous dysplasia may occur anywhere in the jaws but is essentially monostotic and typically affects the maxilla in young people, although it sometimes affects adjacent bones (*craniofacial fibrous dysplasia*), but rarely crosses the midline. CT can best assess the extent in the facial skeleton.

*McCune-Albright's syndrome* is FD bone lesions with skin pigmentation and endocrinopathy (precocious puberty in females and hyperthyroidism in males).

Bone enlarges in FD but the morphology is preserved, distinguishing FD from a neoplasm. FD lesions vary from radiolucent to radio-opaque, often a 'ground-glass appearance' (Figure 5) with ill-defined margins – a feature helpful to distinguish it from other lesions. Typically, no treatment is needed. Bisphosphonates can help and surgery may be indicated if there is major deformity or pressure on nerves.

#### Hypercementosis

Hypercementosis is increased deposition of cementum on roots, caused by local trauma, inflammation, Paget's disease, or may occur idiopathically.

#### Ossifying fibroma (Cemento-ossifying fibroma)

Ossifying fibroma is a usually benign, slow-growing, painless bone neoplasm, typically monostotic and seen in the third and fourth decades in the posterior mandible as a radiolucent, radio-opaque, or mixed opacity and which has a fibro-osseous microscopic appearance.



The advertisement features a dark blue background. At the top left is the Southern Implants logo, a stylized 'S' with horizontal lines, above the text 'SOUTHERNIMPLANTS'. The main headline reads 'Co-Axis angled implants for simple restorations' in large white font. In the center is a detailed 3D cutaway illustration of a dental implant, showing its threaded body and a wider, flared top section with a textured surface. At the bottom, the Southern Implants logo is repeated, with the tagline 'Expanding Proven Concepts' below it. Three small inset images at the very bottom show different views of the implant: a side view, a top-down view, and a perspective view.

Ossifying fibroma and focal COD are not easily differentiated histopathologically. Juvenile ossifying fibroma is an aggressive variant with a rapid growth pattern seen mainly in boys aged under 15 years.

Traditionally, the initial treatment has been simple curettage. More definitive resection has been reserved for recurrent disease.

#### **Paget's disease of bone**

Paget's disease of bone (PDB) is a progressive fibro-osseous disease affecting bone and cementum, characterized by disorganization of osteoclastogenesis (osteoclast formation) – a process dependent on two cytokines, macrophage colony stimulating factor (M-CSF) and receptor activator of nuclear factor kappa-B ligand (RANKL), which induce gene expression changes, presumably by inducing transcription factors. The tumour necrosis factor (TNF) receptor superfamily activate nuclear factor kappa-B (NF- $\kappa$ B), and RANK (for receptor activator of NF- kappa B), which is involved in osteoclastogenesis.

Seen mainly in males over 55 years of age, there is a strong genetic component; 15–20% have a first-degree relative with PDB. Genes involved include the sequestosome1 gene (SQSTM1).

In PDB, bone remodelling is disrupted, and an anarchic alternation of bone resorption and apposition results in mosaic-like 'reversal lines'. Most patients are asymptomatic. A minority of patients with Paget's disease experience a variety of symptoms, including bone pain secondary osteoarthritis, bone deformity and neurological complications due to compression of nerves.

In early lesions, bone destruction predominates (osteolytic stage) and there is bowing of the long bones, especially the tibia, pathological fractures, broadening/flattening of the chest and spinal deformity. The increased bone vascularity can lead to high output cardiac failure.

Later, as disease activity declines, bone apposition increases (osteosclerotic stage) and bones enlarge, with progressive thickening (between these phases is a mixed phase). PDB is typically polyostotic and may affect skull, skull base, sphenoid, orbital and frontal bones. The maxilla often enlarges, particularly in the molar region, with widening of the alveolar ridge. In early lesions, large irregular areas of relative radiolucency (osteoporosis circumscripta) are seen, but later there is increased radio-opacity, with appearance of 'cotton wool' pattern. Constriction of skull foramina may cause cranial neuropathies. The dense bone and hypercementosis makes tooth extraction difficult, and there is also a liability to haemorrhage and infection.

Diagnosis supported by imaging, biochemistry and histopathology. Bone scintiscanning shows localized areas of high uptake. Plasma alkaline phosphatase and urine hydroxyproline levels increase with little or no changes in serum calcium or phosphate levels. Bisphosphonates are used in the treatment of PDB but calcitonin may also help.