

Orofacial Disease: Update for the Dental Clinical Team: 4. Red, Brown, Black and Bluish Lesions

Crispian Scully and Stephen Porter

Abstract: This article discusses coloured lesions of the orofacial region.

Dent Update 1999; **26**: 169-173

Clinical Relevance: Red lesions may signify dysplastic as well as inflammatory conditions. Hyperpigmented lesions, unless confidently diagnosed as amalgam tattoos, should also be taken seriously

velvety red plaque typically seen on the soft palate or ventrum of the tongue/floor of mouth of elderly men (Figure 1). It is usually level with or depressed below surrounding mucosa, and sometimes is associated with white patches—speckled leukoplakia or erythroleukoplakia.

Virtually every case of erythroplasia has areas of dysplasia, carcinoma *in situ*, or invasive carcinoma. Carcinomas are seen 17 times more frequently in erythroplasia than in leukoplakia and erythroplasia is therefore the most potentially malignant of all oral mucosal lesions—but erythroplasia is far less common than leukoplakia.

Diagnosis and Management

Clinically it is important to differentiate erythroplasia from inflammatory and atrophic lesions, such as those seen in deficiency anaemias, geographic tongue, lichen planus. Biopsy is indicated. Treatment is by scalpel or laser excision but the prognosis is often poor

Mucositis

Mucositis is common after irradiation of tumours of the head and neck, if the radiation field involves the oral mucosa. Arising within 3 weeks of the irradiation,

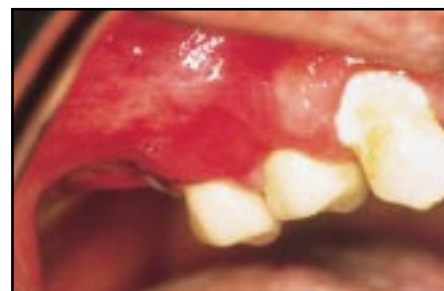

Figure 1. Erythroplasia.

Most red lesions are inflammatory in origin but it is important to appreciate that others are associated with mucosal atrophy. Erythroplasia is one of the more important, since it is often dysplastic. Other causes of red lesions include burns, telangiectasia (after irradiation; in hereditary haemorrhagic telangiectasia; or scleroderma), haemangioma, purpura, or neoplasms. Generalized mucosal erythema may be caused by inflammatory lesions or mucosal atrophy. Central cyanosis produces a blue-red discoloration.

The most usual cause of brown oral mucosal pigmentation is ethnic origin. Localized brown, blue or black hyperpigmentation may be caused by amalgam tattoo, naevus, Kaposi's sarcoma, or malignant melanoma. Generalized hyperpigmentation may be caused by localized irritation (e.g. smoking), drugs such as antimalarials, Addison's disease, or other rare causes.

The first article in this series presented several general observations on diagnosis

and treatment which should be borne in mind in relation to this article.

RED LESIONS

While most red lesions are inflammatory in origin, it is important to appreciate that others are due to burns, telangiectasia (after irradiation; in hereditary haemorrhagic telangiectasia; or scleroderma), haemangiomas, purpura, neoplasms, or associated with mucosal atrophy; see Table 1. Erythroplasia is one of the more important red lesions to be considered. Generalized mucosal erythema may be caused by inflammatory lesions or mucosal atrophy. Central cyanosis produces a blue-red discoloration.

Erythroplasia (Erythroplakia)

Erythroplasia is a rare condition mainly of elderly men, defined as 'any lesion of the oral mucosa that presents as bright red velvety plaques which cannot be characterized clinically or pathologically as any other recognizable condition'.

Aetiology

The aetiology is unclear.

Clinical Features

Erythroplasia is an uncommon, painless,

Crispian Scully, PhD, MD, MDS, FDS RCPS, FFD RCSI, FDS RCS, FDS RCSE, FRCPath, FMedSci, Professor, and Stephen Porter, PhD, MD, FDS RCSE, FDS RCS, Professor, Eastman Dental Institute for Oral Health Care Sciences and International Centre for Excellence in Dentistry, University of London.

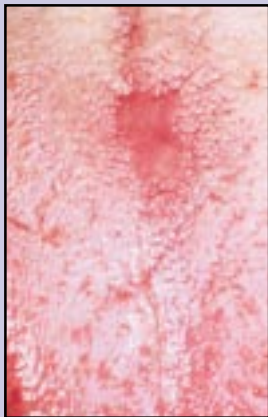

Figure 2. Candidosis; median rhomboid glossitis.

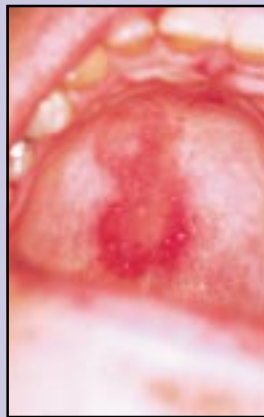


Figure 3. Candidosis; erythematous lesion in palate.

there is painful generalized erythema, and sometimes ulceration. There is no specific treatment but oral hygiene should be improved and analgesics given.

Erythematous Candidosis

Candidosis may cause a sore red mouth, and is especially seen on the tongue of patients taking broad-spectrum antimicrobials. Erythematous candidosis, especially on the palate or tongue, may also be a feature of HIV disease (see *Dent Update* 1999; 26: 73-80).

Median rhomboid glossitis is a painless red patch occurring in the middle of the dorsum in the posterior area of the anterior two-thirds of the tongue. Some patients have lesions in the centre of the dorsum

of the tongue and palate (kissing lesions) (Figures 2 and 3).

Chronic Atrophic Candidosis (Denture-induced Stomatitis)

Chronic atrophic candidosis is a painless candidal infection of the denture and denture-bearing mucosa (this will be discussed further in a later article).

Purpura

Purpura (see Table 2) is bleeding into the skin and mucosa, usually because of trauma, suction or a blood platelet defect or deficiency.

Aetiology

Trauma, such as that caused by the vomiting in bulimics, or suction and trauma in performing fellatio are not uncommon causes. Old people may suffer from senile purpura, and corticosteroids may also produce purpura. Idiopathic (autoimmune) platelet deficiency, sometimes seen in HIV disease, infectious mononucleosis or rubella, is the other main cause. Blood blisters may also arise in the palate, especially, for no apparent reason—this is known as angina bullosa haemorrhagica (see below).

Clinical Features

Red or brown pinpoint lesions (petechiae) or diffuse bruising (ecchymoses) are seen mainly at sites of trauma (Figure 4). Occasional small traumatic petechiae at the occlusal line are seen in otherwise healthy patients. Palatal petechiae may be seen after trauma and in:

- HIV disease;
- infectious mononucleosis;
- rubella;
- thrombocytopenia;
- performing fellatio.

Diagnosis and Management

The diagnosis is mainly clinical. Petechiae and ecchymoses do not blanch on pressure (*cf.* haemangioma). It may be necessary to take a blood and platelet count and assess haemostatic function. Treatment is of the underlying cause.

Localized Oral Purpura

Blood blisters in the mouth are not uncommon in elderly people.

Aetiology

Unclear. No bleeding tendency appears to underlie this condition. Corticosteroid inhalers may sometimes predispose.

Clinical Features

Blood blisters are seen in the mouth or pharynx, mainly on the soft palate (sometimes termed angina bullosa haemorrhagica) and occasionally on the lateral border of the tongue in elderly people. There is rapid onset, with breakdown in a day or two to a large round ulcer (Figures 5 and 6).

Diagnosis and Management

It is necessary to differentiate this condition from pemphigoid and other vesiculobullous disorders, trauma, and purpura. Confirm that haemostasis is normal first and then perform biopsy to exclude pemphigoid if that is likely.

There is no specific treatment other than reassurance. The blisters should be carefully burst. Topical analgesics may provide symptomatic relief.

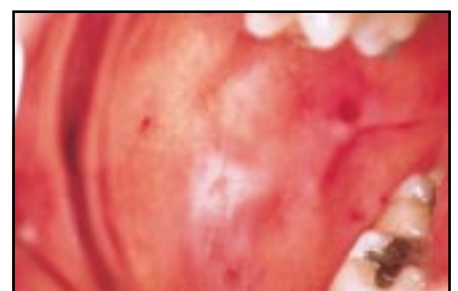

Figure 4. Purpura.

Localized red patches:

- Denture-induced stomatitis
- Geographic tongue
- Lichen planus
- Erythroplasia
- Purpura
- Telangiectases
- Angiomas
- Kaposi's sarcoma
- Burns
- Lupus erythematosus
- Avitaminosis B₁₂
- Drugs

Generalized redness:

- Candidosis
- Avitaminosis B complex
- Irradiation mucositis
- Mucosal atrophy
- Polycythaemia

Table 1. Causes of oral red areas

<p>Trauma and suction</p> <p>Platelet disorders:</p> <ul style="list-style-type: none"> ● Autoimmune thrombocytopenia ● Bone marrow disorders: aplasia, leukaemia <p>Infections</p> <ul style="list-style-type: none"> ● Infectious mononucleosis ● Rubella ● HIV infection <p>Localized oral purpura (angina bullosa haemorrhagica)</p> <p>Vascular disorders</p> <p>Amyloidosis</p>
--

Table 2. Causes of oral purpura.

Haemangiomas

Aetiology

Haemangiomas are uncommon, benign lesions of developmental origin—hamartomas.

Clinical Features

Most haemangiomas are seen in infancy. They appear most often on the tongue or lip, as painless reddish, bluish or purplish soft lesions (Figure 7). The characteristic feature is that they blanch on pressure, or contain blood.

Diagnosis and Management

Diagnosis is clinical.

Some 50% of those present in childhood

regress spontaneously. Haemangiomas may not need treatment but if they do for aesthetic or functional reasons, laser or cryosurgery or injection of sclerosing agents are effective. Very large haemangiomas may need to be treated by the surgeon with embolization (sclerosal or, rarely, arterial)—but only if bleeding is troublesome.

Lymphangioma

Lymphangioma is a rare hamartoma or benign neoplasm of lymphatic channels, seen especially in the lip or tongue. Although typically a colourless, sometimes finely nodular, soft mass, bleeding into the lymphatic spaces causes sudden purplish discoloration.

Management is by excision biopsy.

Kaposi's Sarcoma

This has been described in an earlier article, and will be discussed further at a later date.

BROWN OR BLACK PIGMENTATION

There are many causes of hyperpigmented oral lesions (these are summarized in Table 3).

Racial Pigmentation

The most usual cause of brown oral mucosal pigmentation is natural ethnic pigmentation, in Blacks, Asians and people of Mediterranean descent. The pigmentation is usually symmetrically distributed over the gingiva and palatal mucosa (Figure 8), though patches may be seen elsewhere. Pigmentation, if first noted by the patient in adult life, may incorrectly be assumed to be acquired.

Pigmented Naevi

Aetiology

These lesions are genetic in origin.

Clinical Features

Pigmented naevi are seen particularly on the vermilion border of the lip and on the palate. They are usually asymptomatic brown or bluish macules, usually less than 1 cm across, and do not change rapidly in size or colour.

Management

Excision biopsy is recommended, mainly for cosmetic reasons, to exclude malignancy, and because of the malignant potential of some—particularly the junctional naevus. Referral to a specialist may be necessary.

Amalgam and graphite tattoos

Amalgam or graphite incorporated into a wound may cause a tattoo. The features of these lesions are summarized in Table 4.

Aetiology

Amalgam particles or dust can become incorporated in healing wounds after tooth extraction or apicectomy or beneath mucosa. Graphite may be introduced through accidents involving lead pencils.

Clinical Features

Amalgam tattoos are common causes of asymptomatic blue-black pigmented macules, usually seen in the mandibular gingiva or at least close to the teeth (Figure 9), in the floor of mouth, or in the scar of an apicectomy where there has been a retrograde root filling.

Diagnosis and Management

The diagnosis is usually obvious from the location and clinical appearance. Radiopacities may or may not be seen on radiography. Biopsy may occasionally be indicated to exclude a naevus or melanoma but otherwise these lesions are innocuous.

Addison's Disease

Addison's disease (adrenocortical hypofunction; Table 5) is a rare disease, seen typically in young or middle-aged women, due to damage to the adrenal cortex. It results in hypotension and a feedback pituitary overproduction of adrenocorticotrophic hormone (ACTH)

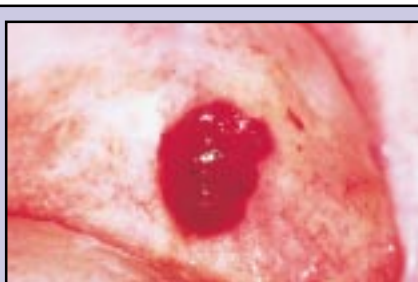

Figure 5. Angina bullosa haemorrhagica.

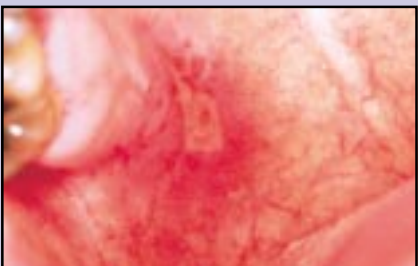

Figure 6. Angina bullosa haemorrhagica.

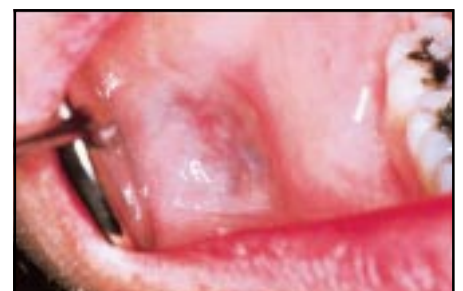

Figure 7. Haemangioma.

Localized:

- Amalgam tattoo
- Naevus
- Kaposi's sarcoma
- Malignant melanoma
- Pigmentary incontinence
- Peutz-Jegher's syndrome

Generalized:

- Racial
- Localized irritation, e.g. smoking
- Drugs, e.g. antimalarials
- Addison's disease
- Other rare causes

Table 3. Causes of hyperpigmentation.

which produces hyperpigmentation of skin and mucosae.

Aetiology

Addison's disease is usually an autoimmune disease. Other causes include tuberculosis, carcinomatosis and histoplasmosis.

Clinical Features

Hyperpigmentation is generalized and brown, but is most obvious in areas that are normally pigmented, such as:

- areolae of nipples;
- genitalia;
- skin flexures;
- sites of trauma.

The oral mucosa may show patchy brown hyperpigmentation (Figure 10).

Other features of Addison's disease include:

- weakness;
- anorexia;
- weight loss;
- low blood pressure;
- collapse under stress.

Nelson's syndrome is similar to Addison's disease, but is iatrogenic and results from

Aetiology:

- Particles or dust incorporated beneath mucosa or in wounds after extraction or apicectomy or accident

Clinical features:

- Black or bluish-black small pigmented area

Incidence:

- Common in adults mainly

Management:

- May need to excise to exclude melanoma microscopically

Table 4. Amalgam and graphite tattoos.

adrenalectomy in the management of breast cancer.

Diagnosis and Management

It may be necessary to differentiate from racial, drug-induced, and other causes of hyperpigmentation, and to establish the cause of the adrenal hypofunction. Blood pressure, plasma electrolyte and cortisol levels and response to ACTH stimulation (Synacthen test) should be assessed, and thus a specialist referral is indicated.

Addison's disease is treated by replacement therapy (fludrocortisone and glucocorticoids).

Drug-induced Hyperpigmentation

A variety of drugs can cause orofacial hyperpigmentation, and often by unknown mechanisms:

- heavy metals (e.g. lead) cause pigmented lines because of sulphide deposits in gingival pockets;
- antimalarial agents;
- busulphan;
- cisplatin;
- phenothiazines;
- zidovudine;
- minocycline;
- oral contraceptives.

Diagnosis is usually from a history of exposure to the drug. Treatment is to stop the drug if possible.

Malignant Melanoma

Melanoma is a rare malignant neoplasm of melanocytes, with a poor prognosis.

Aetiology

Malignant melanoma may arise in apparently normal mucosa of a pre-existent pigmented naevus, usually in the palate. The incidence of extra-oral melanoma is increasing as a result of increased sun exposure.

Clinical Features

Melanoma typically appears as a heavily pigmented (occasionally non-pigmented) macule or, later, nodule and ulceration, usually in the palate. Spread is to regional lymph nodes and then the bloodstream.

Features of a hyperpigmented lesion that are suggestive of malignancy include:

- rapid increase in size;

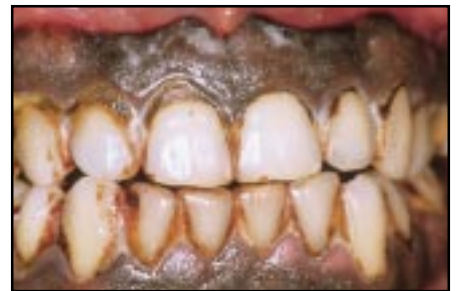

Figure 8. Racial pigmentation.

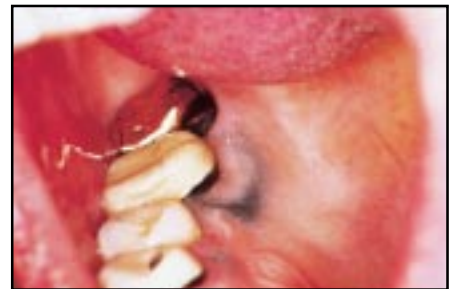

Figure 9. Amalgam tattoo.

- change in colour;
- ulceration;
- pain;
- occurrence of satellite pigmented spots.

Management

The consensus of opinion is that lesions suspected of being malignant melanomas should *not* be biopsied until the time of definitive operation but the prognosis is poor

Aetiology:

- Adrenocortical destruction and subsequent increased release of pituitary adrenocorticotrophic hormone (ACTH)

Clinical features:

- Hyperpigmentation, especially in sites usually pigmented or traumatized
- Oral: brown pigmentation of gingiva, occlusal line and elsewhere
- Cutaneous: hyperpigmentation of areolae and genitals, in flexures, and at sites of trauma

Incidence:

- Rare; mainly seen in young or middle-aged women

Management:

- Blood pressure; plasma electrolyte and cortisol levels and response to ACTH stimulation (Synacthen test).
- Idiopathic (autoimmune) Addison's disease: replacement therapy (fludrocortisone and glucocorticoids)
- Others: treat cause, give replacement therapy

Table 5. Addison's disease (hypoadrenocorticism).

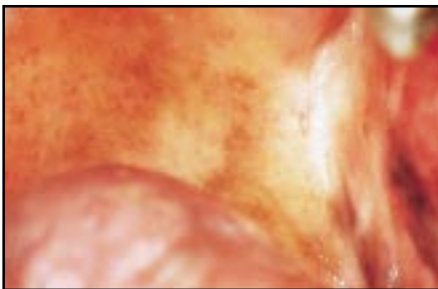


Figure 10. Hyperpigmentation in Addison's disease.

unless treatment is exceptionally early. Specialist referral is thus usually indicated.

Further Reading

- Burton J, Scully C. The lips. In: Champion RH, Burton J, Burns DA, Breathnach SM, eds. *Textbook of Dermatology*, 6th ed. Oxford: Blackwells, 1998; pp.3125-3148.
- Eveson JW, Scully C. *Colour Atlas of Oral Pathology*. London: Mosby-Wolfe, 1995.
- Jones JH, Mason DK. *Oral Manifestations of Systemic Disease*, 2nd ed. London: Baillière, 1980
- Kaban LB, Mulliken JB. Vascular anomalies of the maxillofacial region. *J Oral Maxillofac Surg* 1986; **44**: 203-213.

- Lamey P-J, Carmichael F, Scully C. Oral pigmentation, Addison's disease and the results of screening for adreno-cortical insufficiency. *Br Dent J* 1985; **158**: 297-298.
- Millard HD, Mason DK, eds. *Perspectives on 1993 World Workshop on Oral Medicine*. University of Michigan, 1995.
- Moyer GN, Terzhalmy GT, O'Brian JT. Nelson's syndrome: another condition associated with mucocutaneous hyperpigmentation. *J Oral Med* 1985; **1**: 13-17.
- Scully C. *Handbook of Oral Diseases*. London: Martin Dunitz, 1999.
- Scully C, Cawson RA. *Medical Problems in Dentistry*, 4th edition. Oxford: Butterworth-Heinemann, 1998.
- Scully C, Flint S, Porter S. *Oral Diseases*. London: Martin Dunitz, 1996.
- Scully C, Welbury R. *Colour Atlas of Oral Disease in Children and Adolescents*. London: Mosby-Wolfe, 1994.
- Scully C. The pathology of orofacial disease. In: Barnes IE, Walls AWG, eds. *Gerodontology*. Oxford: Wright, 1994; pp.29-41.
- Scully C, Porter SR. Oral mucosal disease: a decade of new entities, aetiologies and associations. *Int Dent J* 1994; **44**: 33-43.
- Scully C. Diagnosis and diagnostic procedures: general and soft tissue diagnosis. In: *Pathways in Practice*. London: Faculty of General Dental Practice, Royal College of Surgeons of England, 1993; pp.25-33.
- Scully C. Inflammatory disorders of the oral

- mucosa. In: English GM, ed. *Otolaryngology*. Philadelphia: Lippincott, 1993; pp.1-28.
- Scully C. Prevention of oral mucosal disease. In: Murray JJ, ed. *Prevention of Oral and Dental Disease*, 3rd ed. Oxford: Oxford University Press, 1995; pp.160-172.
- Scully C. The oral cavity. In: Champion RH, Burton J, Ebling FJG, eds. *Textbook of Dermatology*, 5th ed. Oxford: Blackwells, 1991; pp.2689-2769.
- Scully C. The oral cavity. In: Champion RH, Burton J, Burns DA, Breathnach SM, eds. *Textbook of Dermatology*, 6th ed. Oxford: Blackwells, 1998; pp.3047-3124.
- Scully C, El-Kabir M, Samaranyake LP. Candida and oral candidosis. *Crit Rev Oral Biol Med* 1994; **5**: 124-158.
- Stal S, Hamilton S, Spira M. Haemangioma, lymphangioma and vascular malformations of the head and neck. *Otolaryngol Clin North Am* 1986; **19**: 769-796.
- Stephenson P, Lamey P-J, Scully C *et al*. Angina bullosa haemorrhagica: clinical and laboratory features in 30 patients. *Oral Surg Oral Med Oral Pathol* 1987; **63**: 560-565.
- Stephenson P, Scully C, Prime SS *et al*. Angina bullosa haemorrhagica: lesional immunostaining and haematological findings. *Br J Oral Maxillofac Surg* 1987; **25**: 488-491.
- van der Waal RI, Snow GB, Karim AB *et al*. Primary malignancy melanoma of the oral cavity: a review of eight cases. *Br Dent J* 1994; **176**: 185-188.

Book Review

The Preservation and Restoration of Tooth Structure. By Graham J. Mount and W. R. Hume. Mosby-Wolfe Medical Communications, London. (280pp., £49.95, £85 plus CD-Rom).

There has long been a need for a book of 'Operative Dentistry' of this type. Traditionally, textbooks dealing with the treatment of dental caries have been mechanistic and oversimplified with the result that they become redundant soon after the dental student has gained basic operative skills. This new text begins from a refreshingly biological basis and, even within the introduction, challenges dogmatic tenets. The beauty of this book is its ability to be used at different levels. It will take the role of an instruction book for the early undergraduate but contains background and clinical knowledge that will be indispensable for Finals. It is, however, unique in that it is also entirely appropriate for use by postgraduate students at all sorts of levels (e.g. DGDP/MGDS/MSc/MRD).

The main authors are highly respected. Both are Australian with one an academic and the other a practitioner. The eminently

readable textbook is a composite of practical and theoretical knowledge. It is filled with common sense backed up by scientific evidence. There is a sensible progression from the basic sciences of tooth structure, disease initiation and progression to clinical intervention. The scope of clinical intervention is enormous including prevention, endodontology, fixed prosthodontics, relevant periodontology and occlusion, and the restoration of aesthetics. Incorporated in the clinical section are excellent chapters that review the key clinical properties of individual restorative materials and the concepts of dentine bonding of glass-ionomer, composite and amalgam.

At each stage, traditional and newer, equally anecdotal, concepts are challenged. This is most notable in the chapters on 'Pulp protection during and after restoration', which supports the decreased use of setting CaOH as a base and 'Basic principles for restorative dentistry', which comprehensively argues against the routine use of dentine pins in cuspal replacement. Believers in the infallibility of dentine-bonding systems will not accept the authors' caution in recommending their use. The

authors, however, present cogent arguments for the use of glass-ionomers to prevent bacterial leakage and to act as a dentine replacement under composite restorations. The intention to maintain the maximum amount of original tooth tissue, whatever restoration is being considered, runs through the book and should be commended.

Chapter 11 is one of the most contentious in that it proposes an alternative to the 100-year-old Black's Classification of Cavities. The logic in the proposed classification is clear and useful. However, there appears to be a genetic predisposition to Black's Classification (and cavity form) and I would be surprised if the new classification was widely used — despite its advantages.

This is a wonderful book. It is well illustrated, well written and thought provoking. There is also an accompanying CD-Rom, that was not available to me to review but the quality of the book is such that it stands alone. I recommend it to everybody who puts bur to tooth.

C. C. Youngson
Senior Lecturer in Restorative
Dentistry
Leeds Dental Institute