



Nicolaos Pigadas

Richard Oliver

# Common Facial Fractures: 1. Aetiology and Presentation

**Abstract:** Fractures of the facial bones are common and, in the West, usually occur as a result of interpersonal violence. Patients may attend dentists in the first instance as derangement of occlusion and other oral symptoms are common.

**Clinical Relevance:** As patients with facial bone fractures may attend their dentist in the first instance, dentists should be confident in recognizing the signs and symptoms of facial fractures.

**Dent Update 2006; 33: 347-356**

Fractures of the facial bones are very common. In the UK, patients with facial fractures account for 4% of all Accident and Emergency Department attendances in one week. It is not uncommon for patients to present to their general dental practitioner (GDP) following a modestly traumatic incident, often because their occlusion is deranged as a result of an associated fracture. The most likely injuries that may present to the GDP are those with minimal signs and symptoms, such as fractures to the mandibular condyles or minimally displaced fractures of the mandibular body and fractures of the zygoma.

## Aetiology

The more common causes of facial fractures are summarized in Table

**Nicolaos Pigadas**, FDS RCS, FRCS Ed, FRCS(OMFS) Specialist Registrar, Maxillofacial Unit, Manchester Royal Infirmary, Manchester M13 9WL and **Richard Oliver**, PhD, FDS(OS) RCPS, Senior Lecturer in Oral and Maxillofacial Surgery, School of Dentistry, The University of Manchester, Higher Cambridge Street, Manchester M15 6FH, UK.

1. Particularly in the developed Western world, the aetiology is largely due to interpersonal violence, most commonly fuelled by alcohol consumption. In most developing countries, however, the aetiology is commonly related to road traffic accidents (RTAs) as road use legislation may not be strict and seat belts may rarely be worn. Since the introduction of compulsory seat-belt legislation in the UK in 1983, the incidence of facial fractures resulting from RTAs has reduced significantly. Less commonly, facial injuries can occur during sports, particularly contact sports such as rugby. Pathological fractures are relatively uncommon but may be seen in association with oral malignancy both pre- and post- treatment (Figures 1 and 2) and usually occur in the mandible. Related to pathological fractures are iatrogenic causes, often as a result of treatment of pathology such as large mandibular cysts (Figure 3).

## Classification

A classification must be easy to use and have both therapeutic and prognostic value. There have been several classifications of the fractures of the facial skeleton but none appears to be entirely satisfactory. For the present series of

### Aetiology of facial fractures

- Interpersonal violence
- Road traffic accidents
- Sports injuries
- Recreational injuries and falls
- Work related/ industrial injuries
- Pathological
- Iatrogenic

### Associated factors

- Alcohol
- Drugs

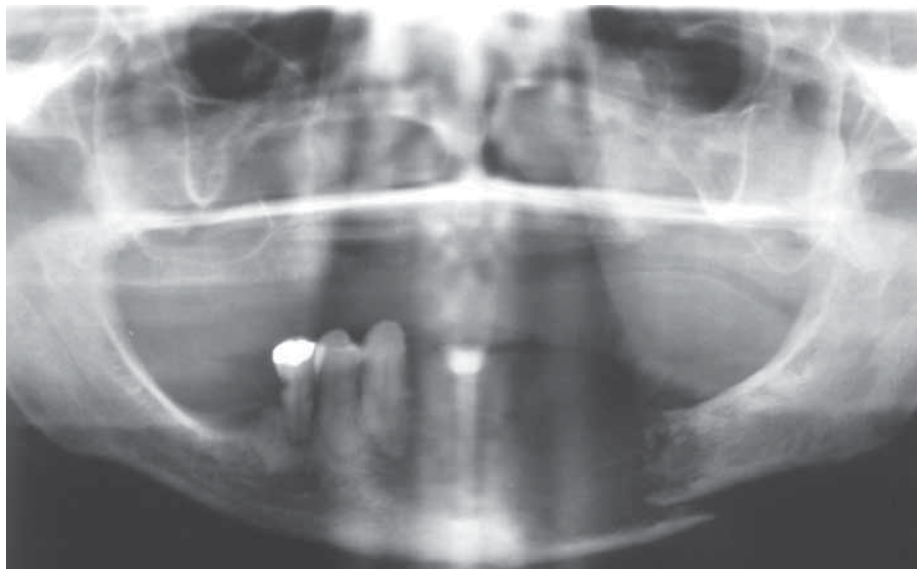
**Table 1.** The more common causes of facial fractures.

papers, we will divide the hard tissue facial injuries into:

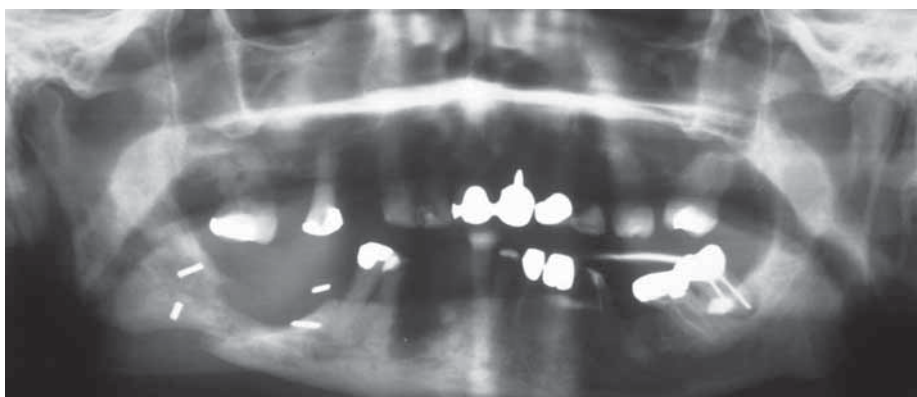
- Dentoalveolar injuries;
- Mandibular fractures; and
- Middle/upper facial third fractures.

### Dentoalveolar injuries

These are injuries affecting the teeth and/or their supporting structures and can be further subdivided into injuries to the hard dental tissues and pulp, periodontal tissues, supporting bone, and gingivae and oral mucosa.



**Figure 1.** Pathological fracture of the left mandibular body resulting from extensive bone invasion by squamous cell carcinoma.



**Figure 2.** Pathological fracture of the right mandibular body in an area of osteoradionecrosis in a patient treated some 20 years previously for oral cancer with radioactive implants into his tongue.

### Mandibular fractures

Bony injuries of the lower jaw can be classified according to the anatomical site (Figure 4) into fractures of:

- Condyle (Figure 4a) which can be further subdivided into:

- Intracapsular and
- Extracapsular (fractures of the condylar neck and subcondylar).

Apart from the direction of the fracture line, the displacement and dislocation of the fragments in relation to the glenoid fossa are very important. The commonest displacement is antero-medial resulting from the direction of pull of the lateral pterygoid muscle (Figures 5, 6).

- Coronoid process (Figure 4b); and
- Ramus (Figure 4c): these both being

uncommon fracture sites;

- Angle (Figure 4d): fractures between the anterior border of the masseter muscle and the mandibular angle;
- Body (Figure 4e): fractures of the premolar and molar area with a posterior limit of the anterior border of the masseter muscle;
- Parasymphysis (Figure 4f): fractures of the area between the canine and the midline;
- Symphysis (Figure 4g): midline fractures.

From a biomechanical point of view, mandibular fractures are divided into:

- Favourable, when the adjacent muscle pull tends to keep the fracture reduced; and
- Unfavourable, when the muscle pull

tends to distract the fragments. A typical example of unfavourable fracture is the bilateral fracture of the atrophic mandible. The anterior segment becomes grossly displaced downwards under the traction of the digastric and mylohyoid muscles ('bucket handle' displacement, Figure 7).

### Middle and upper facial third fractures

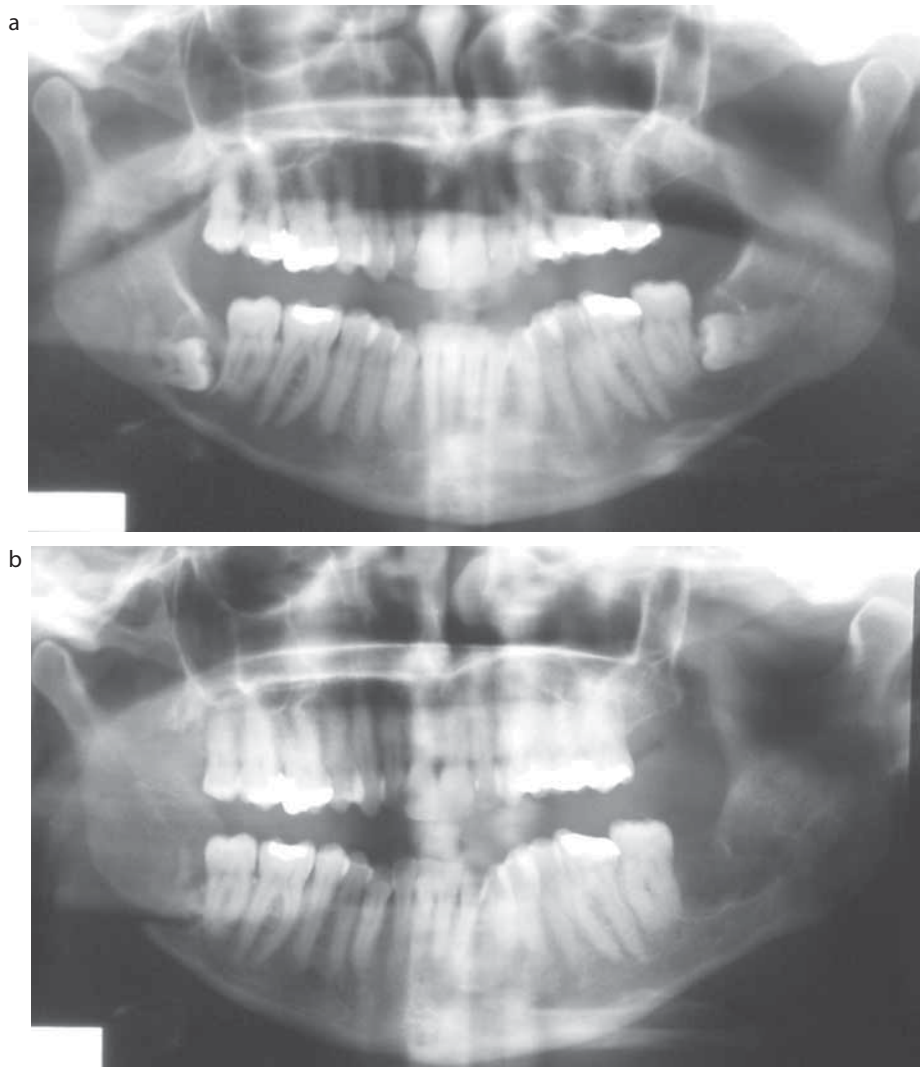
A broad spectrum of injuries can be seen in this anatomical area and are usually caused by major trauma, so it is less likely that the dentist will have to diagnose such injuries. Details are included here largely for information:

- Zygomatic complex: fractures disrupt the articulations of the zygoma with the adjacent facial skeleton (zygomatico-frontal, zygomatico-sphenoid, infraorbital rim, zygomatico-maxillary buttress and zygomaticotemporal sutures) (Figure 8). It is important to realize that these injuries involve, to various degrees, the orbital floor and lateral wall, as well as the maxillary sinus. Fractures of the zygomatic arch may occur in isolation and could possibly be classified as separate injuries since their clinical presentation, management and outcome are different.

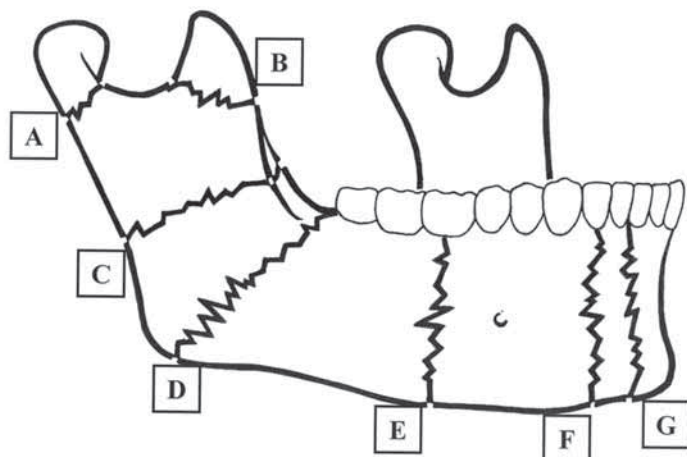
- Orbit: the orbit is commonly involved in mid and upper facial skeleton fractures. Orbital injuries, mainly blow out (away from the orbit) fractures of the floor and medial wall can occur in isolation. Blow in (towards the orbit) fractures are more rarely seen.

- Le Fort fractures: the Le Fort classification of mid facial fractures (Figure 9) is the result of experimental trauma studies in cadavers by René Le Fort at the turn of the 20th century. Maxillary fractures commonly occur at multiple levels, are asymmetric and comminuted and not frequently seen in their typical Le Fort patterns described below. In all cases, midline separation of the maxilla is possible (Figure 10).

- Le Fort I (low level sub-zygomatic or Guerin): the Le Fort I fracture line is horizontal, above the level of the nasal floor. It extends backwards through the pterygoid plates and medially along the lateral nasal wall. The nasal septum is also fractured (Figure 9a).
- Le Fort II (sub-zygomatic or pyramidal): this fracture line runs from the nasal bones downwards and



**Figure 3.** Pathological fracture of the right angle of the mandible following surgical removal of the deeply impacted  $\bar{8}$  and the associated cyst.



**Figure 4.** Sites of fractures of the mandible: (A) condyle; (B) coronoid; (C) ramus; (D) angle; (E) body; (F) parasymphysis; (G) symphysis.

laterally. It crosses the frontal process of the maxilla, the lacrimal bones, the infra-orbital rims, the lateral walls of the maxillary antra and the pterygoid plates. The nasal septum is again fractured (Figure 9b).

- Le Fort III (supra-zygomatic): this fracture runs from near the frontonasal suture backwards involving the full thickness of the ethmoid bone. The fracture line continues laterally below the optic foramina into the posterior limit of the inferior orbital fissures and backwards again across the pterygomaxillary fissures and through the roots of the pterygoid plates. The lateral orbital wall and zygomatic complexes are also fractured and thus the whole of the mid facial skeleton becomes detached from the skull base (Figure 9c).

- Nasal: fractures usually involve the nasal bones and the frontal process of the maxilla unilaterally or bilaterally. The nasal septal cartilage can be dislocated and/or fractured as well as the vomer.
- Naso-ethmoid complex: in more serious injuries, apart from the above mentioned structures, the lacrimal and ethmoid bones are fractured, commonly comminuted. Here again, attention should be paid to the involvement of the orbit, the medial wall of which is fractured.

■ Craniofacial: these injuries are divided into:

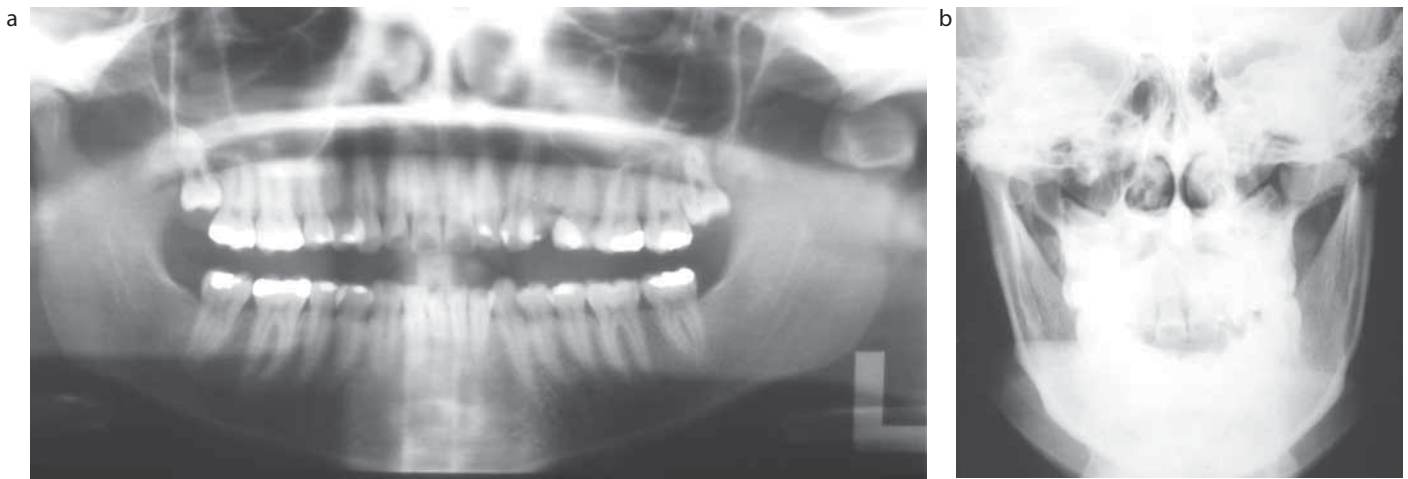- Central which involve the skull base adjacent to the frontal, ethmoid and sphenoid sinuses; and
- Lateral which involve the frontal bone/sinus and the orbital roof.

In relation to the overlying tissues, fractures of the facial skeleton can also be described as:

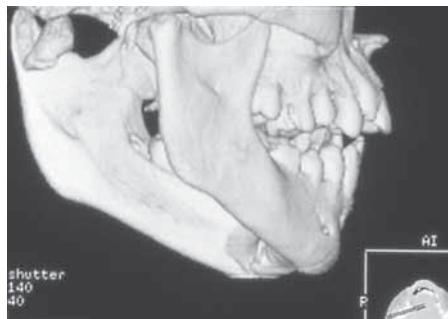
- Closed; and
- Open or Compound.

Fractures of the tooth bearing portions of the jaws are nearly always compound into the mouth and those of the middle third can also be open into the nose and the paranasal sinuses. The overlying skin or oral mucosa might be lacerated, making some typical closed injuries, such as fractures of the edentulous mandible and the mandibular condyle, open. Open injuries with considerable defect in the overlying

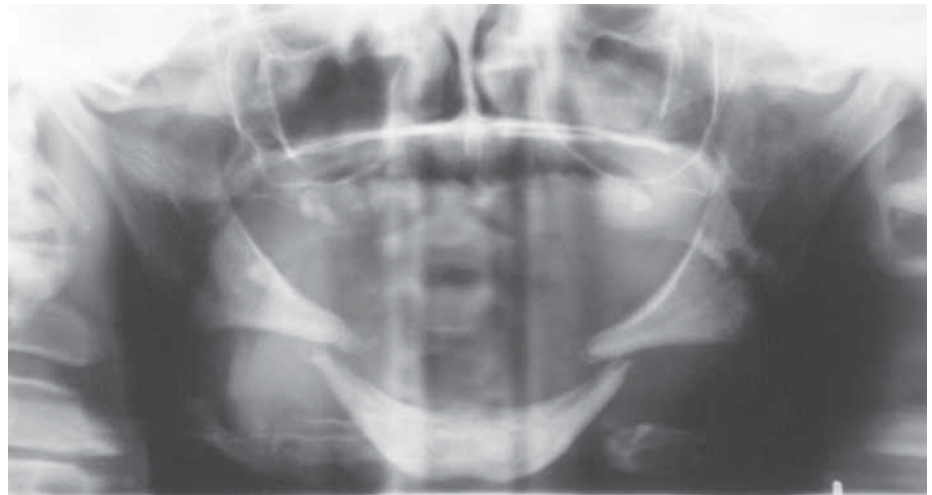



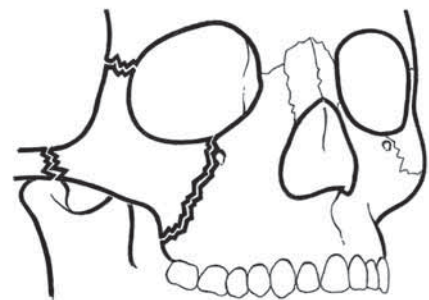
**Figure 5.** OPG (a) and PA mandible (b) x-rays showing a left condylar fracture. The condyle is dislocated and displaced anteriorly and medially.



**Figure 6.** CT scan 3D reconstruction. There are bilateral fracture dislocations of the mandibular condyles which are displaced anteriorly and medially.



**Figure 7.** Bilateral body fractures of an atrophic edentulous mandible with gross 'bucket handle' deformity.



**Figure 8.** Typical pattern of zygomatic complex fracture.

soft tissues are described as 'Complicated'.

Fractures are also defined as:

- Displaced or Undisplaced;
- Complete or Incomplete.

A type of incomplete fracture seen in children is the greenstick. The bone is buckled or bent with one of the cortices only fractured. Fractures of the facial bones

in children are, however, uncommon and, if they do present, a careful history is of utmost importance and non-accidental injury should always be borne in mind.

■ Single or Multiple, depending on the number of fracture lines on the same bone.

In the mandible, combination of direct and indirect force produces bilateral fractures and common combinations are fractures of the angle and contralateral condyle or canine region. Patients sustaining injuries after a fall on the chin may present with fractures of the symphysis and both condyles ('guardsman's fracture'). Severe injuries can involve several facial bones, as seen in panfacial fractures.

■ Comminuted: these are injuries where two or more fracture lines communicate with each other.

■ Defect: in these injuries the severity of impact has caused a defect in the fractured bone.

### Presentation

Maxillofacial trauma patients may present with life threatening conditions and, as for every trauma patient, initial assessment and resuscitation would be carried out simultaneously on presentation in Accident and Emergency with the key aim of preserving life. This follows the standard sequence of the Advanced Trauma and Life Support (ATLS) primary survey which considers five key areas in the following order: Airway and cervical spine support, Breathing, Circulation and haemorrhage control,

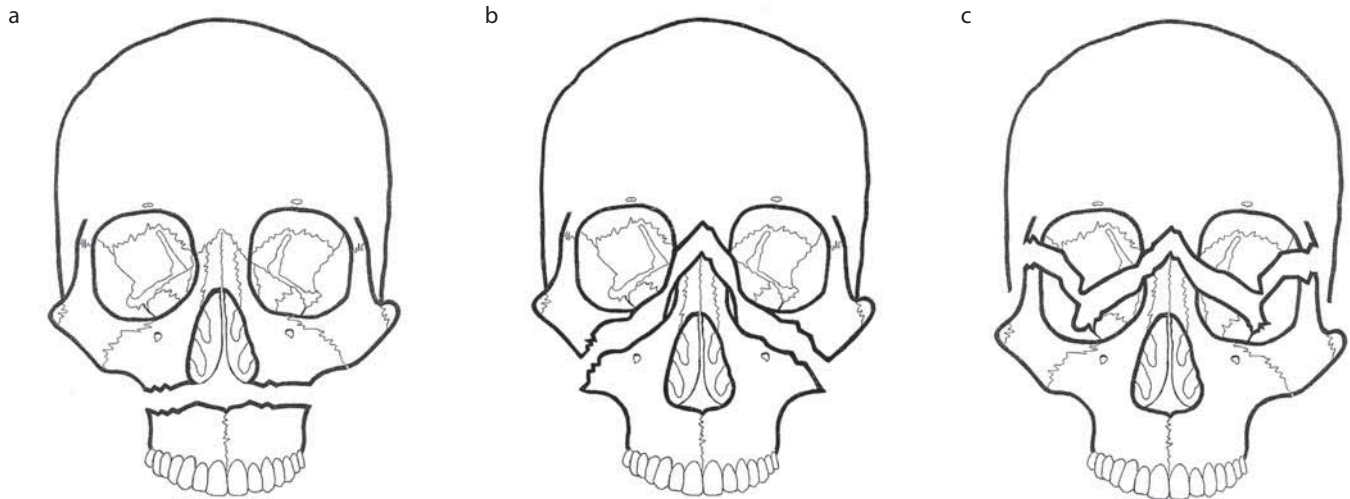


Figure 9. Le Fort I (a), Le Fort II (b) and Le Fort III (c) fracture lines.

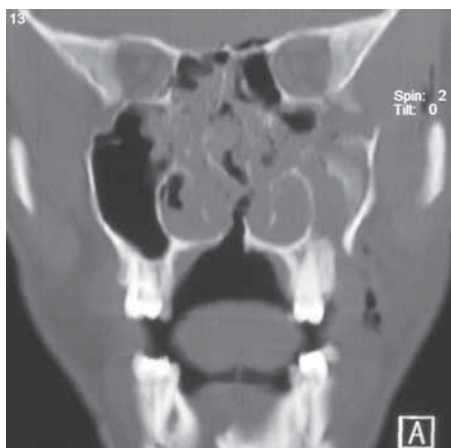


Figure 10. Coronal reconstruction of CT scan of the facial bones showing midline separation of the maxillae.

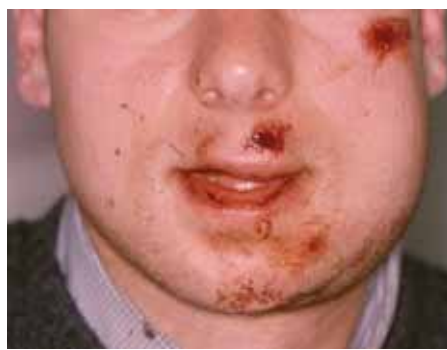

Figure 11. Left facial swelling due to fracture of the mandibular angle. Upper lip swelling and multiple abrasions are also present.

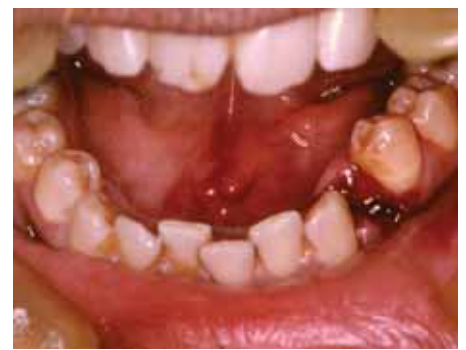

Figure 12. Step deformity, gingival laceration and sublingual haematoma due to a mandibular fracture between  $\bar{3}$  and  $\bar{4}$ .

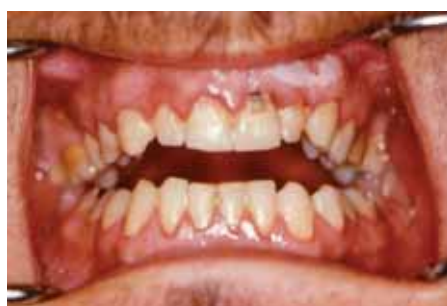

Figure 13. Open bite as a result of bilateral fractures of the mandibular condyles.

Dysfunction of the central nervous system, Exposure and environmental control (ABCDE).

Information regarding the mechanism of injury should be collected and carefully documented, together with the patient's symptoms, in the patient's notes.

Clinical examination of a patient who has experienced trauma starts with inspection and continues with palpation of the injured area. It should be systematic with the following areas being assessed:

- Scalp;
- Base of skull;
- Face.

**Scalp**

It must be examined for lacerations, swelling, bruising and areas of depression.

**Base of skull**

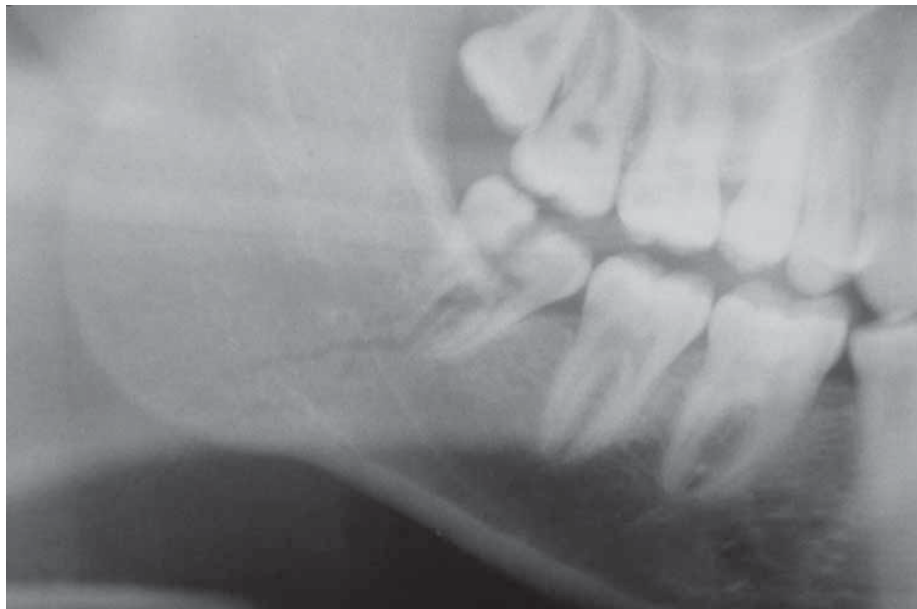Externally, it extends from the mastoid process to the orbit. Accompanying injuries of this area may present with bilateral periorbital haematomas, subconjunctival haemorrhage without posterior limit, haemotympanum, cerebrospinal fluid rhinorrhoea and otorrhoea and post-auricular bruising (Battle's sign). The latter takes several hours

to develop and can be confused with haematoma resulting from fractures of the mandibular condyle.

**Face**

Examination must include the status of the cranial nerves, the eyes, the facial soft and hard tissues, the ears and the nasal and oral cavities. In general, fractures present with pain, swelling and bruising, deformity, mobility, loss of function of the injured area and symptoms and signs of associated injuries (eg sensory loss).

Soft tissue injuries accompanying facial fractures vary from minor contusions and abrasions to extensive tissue loss, as seen in gunshot wounds. Commonly, the area overlying the fracture line is swollen, bruised and tender to palpation (Figure 11). In severe mid-facial and panfacial injuries, gross swelling of the soft tissues gives rise to a characteristic



**Figure 14.** Fracture of the right mandibular angle. The fracture line goes through the socket of 8 which is longitudinally split.

'moon face' appearance. Under these circumstances, assessment of deformity and palpation of possible steps at the fracture site is very difficult.

The specific symptoms and signs of the various facial fractures will be further discussed according to the site.

#### Mandibular fractures

Extra-oral examination should look for the following:

- Impaired inferior dental nerve sensation (anaesthesia, hypoaesthesia or paraesthesia) which is common in fractures of the mandibular angle, molar and premolar area.
- Deformity in the bone contour of the mandible which can be felt if the soft tissue swelling allows palpation of the fracture area.
- Unnatural mobility and bony crepitus which may be felt on bimanual palpation. In case of unexpected mobility, the possibility of more than one fracture in the mandible is high.
- Limitation of mandibular movements: depending on the site and degree of displacement of the fractures, there is inability to close the mouth with dribbling of blood-stained saliva or trismus or just pain during opening, protrusion and

lateral excursions. Deviation from the midline during mandibular movements is not uncommon.

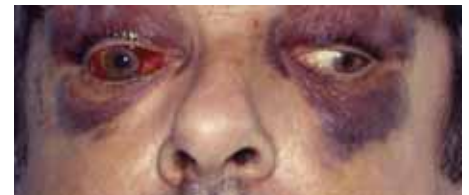- Bleeding from the ear is sometimes seen in association with condylar fractures and is due to laceration of the external auditory meatus.

Intra-orally, bruising (buccal or lingual) and gingival lacerations are common findings. The presence of sublingual haematoma is almost pathognomonic of mandibular fractures (Figure 12). Derangement of the occlusion is common and the type of malocclusion depends on the site and degree of displacement of the fracture. In displaced fractures of the condylar area, there is usually loss of posterior height, with premature contact of the ipsilateral molars classically resulting in an anterior open bite (Figure 13). Dento-alveolar injuries are commonly seen and teeth at the fracture site may split causing considerable discomfort (Figure 14).

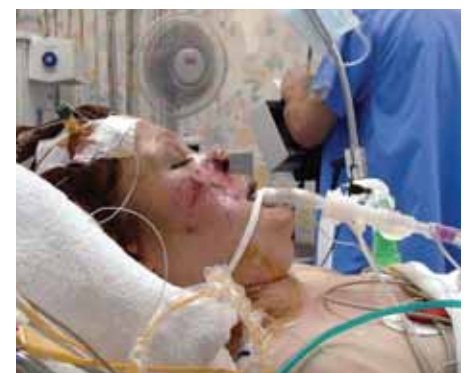#### Middle and upper third fractures

Although most of these fractures are outwith the remit of the GDP, some of the signs are worthy of note.

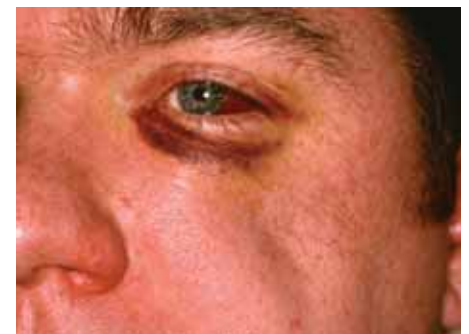The most common nerve injury in mid facial fractures is neuropraxia



**Figure 15.** Bilateral periorbital bruising. Proptosis, subconjunctival haemorrhage and ophthalmoplegia are also present on the right side.



**Figure 16.** Mid facial fracture (Le Fort) showing classic dish-face deformity due to the posterior displacement of the maxilla. (Courtesy of Professor Paul Coulthard.)

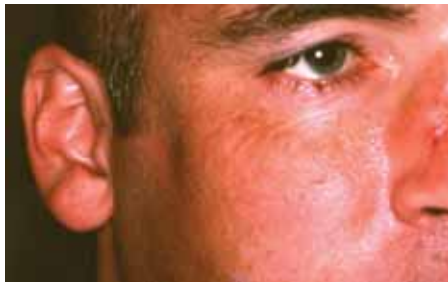

**Figure 17.** Flattening of the zygomatic area, periorbital bruising and subconjunctival haemorrhage. This is a typical presentation of a zygomatic complex fracture.

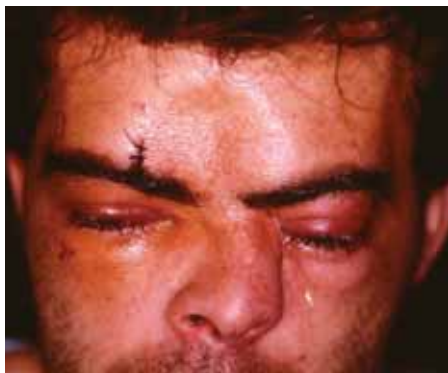(mild, usually temporary) or neurotmesis (complete nerve division) of the infra-orbital nerve resulting in altered sensation of the cheek, nose, upper lip and anterior maxillary teeth.

The vast majority of middle and upper facial third injuries involve, to various degrees, the orbit. Periorbital bruising and swelling are almost always present and subconjunctival haemorrhage is common (Figure 15). The position of the globe (eye ball) may be altered; the





**Figure 18.** Depression due to a fracture of the right zygomatic arch.



**Figure 19.** Grossly displaced fracture of the nasoethmoid complex and frontal bone.

most usual finding on initial assessment is proptosis (protrusion of the eye) due to swelling of the orbital tissues. Enophthalmos (recession of the eyeball in the orbit) usually develops at a later stage. The globe may also be displaced downwards (hypoglobus). Eye injuries and a decrease in visual acuity should be assessed by an ophthalmologist without any delay.

Diplopia (double vision) is a common complaint in facial trauma with

orbital involvement. Excluding central nervous system injuries, diplopia is usually caused by interference with the action of the extra-ocular muscles. The lacrimal system may also be injured, giving rise to epiphora (watering of the eyes).

Postero-inferior displacement of maxillary fractures results in a characteristic dish face deformity, with lengthening of the face (Figure 16). Flattening of the cheek bone only is seen in fractures of the zygomatic complex (Figures 17, 18). Deviation/depression of the nose bridge is seen in fractures of the nasal bones but, if there is depression of the frontonasal angle as well, a nasoethmoid complex injury should be suspected (Figure 19). Comminution of this area also produces telescoping of the nose bridge with elevation of the nasal tip. If the soft tissue swelling and surgical emphysema seen shortly after the injury allow palpation of the facial skeleton, step deformities can be palpated.

Limitation of mandibular excursions may be seen in fractures of the zygomatic complex and, in particular, of the arch because medial displacement of the fractured bone obstructs the movements of the coronoid process, although associated muscle injuries can have the same effect.

Epistaxis is very common. Cerebrospinal fluid (CSF) leak is present if there is involvement of the anterior cranial fossa. Clinically, mixture of CSF (clear) and blood produces a tramline discharge from the nose.

Intra-oral bruising, mainly along the upper buccal sulcus, is common in mid facial injuries, but mucosal lacerations are

not seen often. Separation of the maxillae (palatal split) may be seen in Le Fort fractures (Figure 9) and clinically presents with palatal haematoma or laceration. In these cases, spreading or compression of the posterior dento-alveolar segments will reveal mobility. The most common type of malocclusion seen in maxillary injuries is open bite due to unilateral or bilateral posterior premature contacts. Dento-alveolar injuries may be present. In Le Fort I fractures, there is a cracked pot sound on percussion of the upper teeth.

## Summary

Patients who have experienced trauma to the facial region may have injuries beyond those of the teeth. The GDP is well placed to identify facial fractures and ensure patients are referred for the appropriate treatment. The management of these injuries will be outlined in the next paper.

## Suggested reading

1. Hutchison IL, Magennis P, Shepherd JP, Brown AE. The BAOMS United Kingdom Survey of Facial Injuries Part 1: Aetiology and the association with alcohol consumption. *Br J Oral Maxillofac Surg* 1998; **36**: 3–13.
2. Banks P, Brown A. *Fractures of the Facial Skeleton*. Oxford: Wright, 2001.
3. Booth PW, Schendel SA, Hausamen JE. *Maxillofacial Surgery*. London: Churchill Livingstone, 1999.
4. *Maxillofacial Trauma Guidelines*. British Association of Oral and Maxillofacial Surgeons: [www.baoms.org.uk](http://www.baoms.org.uk)

## Abstract

**HOW MANY ROOT CANALS DO YOU FIND?** Effect of magnification on locating the MB2 canal in maxillary molars. LJ Buhrlay, MJ Barrows, EA BeGole, CS Wenckus. *Journal of Endodontics* 2002; **28**: 324–327.

Most practitioners know that there is probably a fourth canal in an upper first permanent molar, denoted as the MB2 and lying in the mesio-buccal root, yet few actually find it regularly. Indeed, in Britain, where the NHS fee is per tooth rather than

per canal, there may be a major disincentive to searching for the fourth canal, even though failure to shape, clean and fill it may lead to problems with the root canal treatment.

This interesting piece of research documented 312 root treatments of upper molar teeth to ascertain whether magnification helped in locating the MB2 canal. Without magnification, the MB2 canal was found in 17.2% of cases. Using dental loupes this increased to 62.5%, whilst the

result using a surgical microscope was 71.1%. The difference between loupes and microscopes was not found to be significantly different, unlike the relative costs of these two appliances.

The authors conclude that, with a three-fold increase in detection rate of the MB2 canal, more emphasis should be placed on the use of magnification in root canal treatments.

**Peter Carrotte**  
Glasgow Dental School