



Nicolaos Pigadas

Richard Oliver

# Common Facial Fractures: 2. Management

**Abstract:** This, the second of three articles, highlights the management of facial fractures and the GDP's role in this.

**Clinical Relevance:** For patients who present to dental practice with facial fractures, it is important that the dentist is able to inform the patient of his/her likely management in hospital.

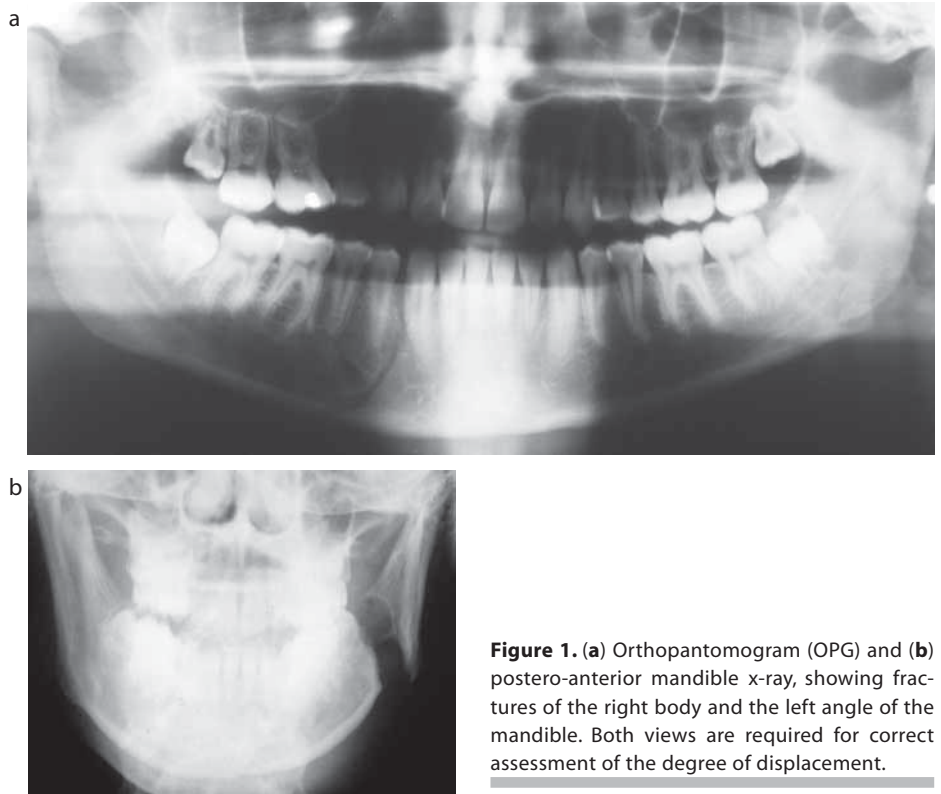**Dent Update 2006; 33: 413-420**

In the previous paper, we outlined the cause and presentation of common facial fractures which may be encountered by GDPs. In this paper, we present a brief overview of the management of such fractures. While the GDP will not be involved with the treatment of patients with facial fractures, they should be able to outline the likely treatment their patients will receive on referral to hospital.

## Management by the GDP

If a patient presents with dental and/or facial trauma, a thorough examination of the patient should be undertaken, as outlined in the first paper in this series. If a fracture is even suspected, the patient should be referred for the appropriate investigations and

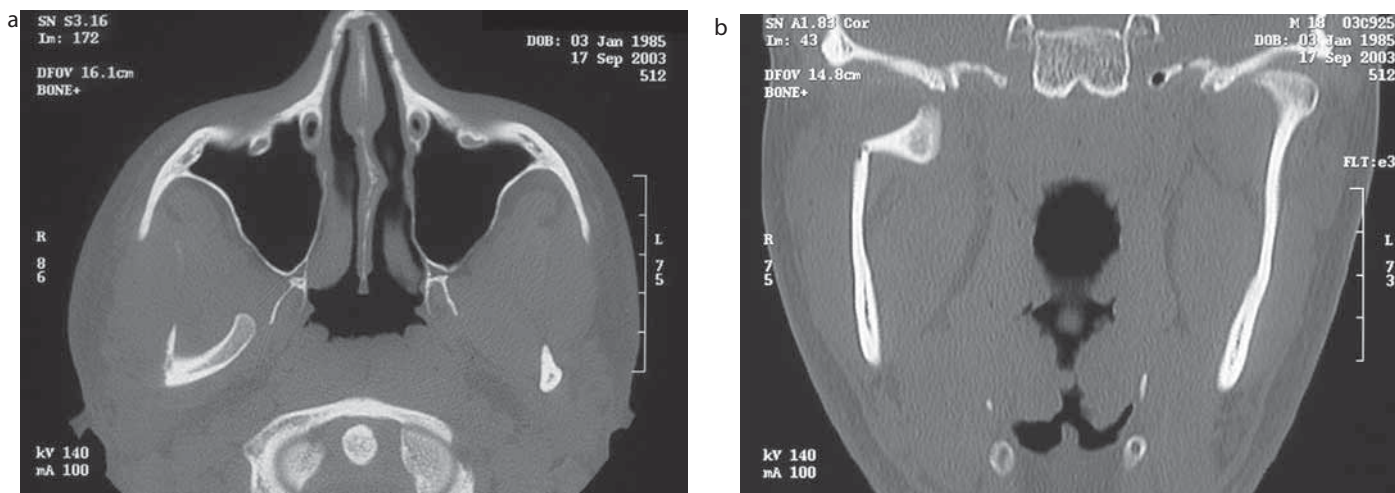
**Nicolaos Pigadas**, FDS RCS, FRCS Ed, FRCS(OMFS) Specialist Registrar, Maxillofacial Unit, Manchester Royal Infirmary, Manchester M13 9WL and **Richard Oliver**, PhD, FDS(OS) RCPS, Senior Lecturer in Oral and Maxillofacial Surgery, School of Dentistry, The University of Manchester, Higher Cambridge Street, Manchester M15 6FH, UK.



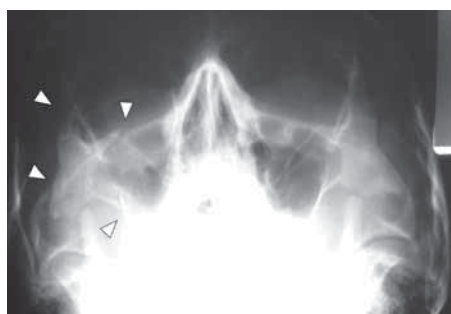**Figure 1.** (a) Orthopantomogram (OPG) and (b) postero-anterior mandible x-ray, showing fractures of the right body and the left angle of the mandible. Both views are required for correct assessment of the degree of displacement.

management. The patient should be sent to the Accident and Emergency department of the nearest hospital. It is also a courtesy to contact the hospital prior to this. It is

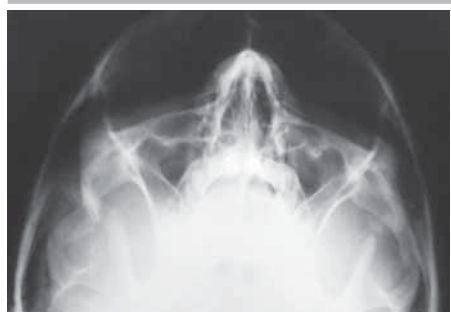probably most useful to speak to the on-call maxillofacial senior house officer as he/she will inevitably be called upon to see the patient.



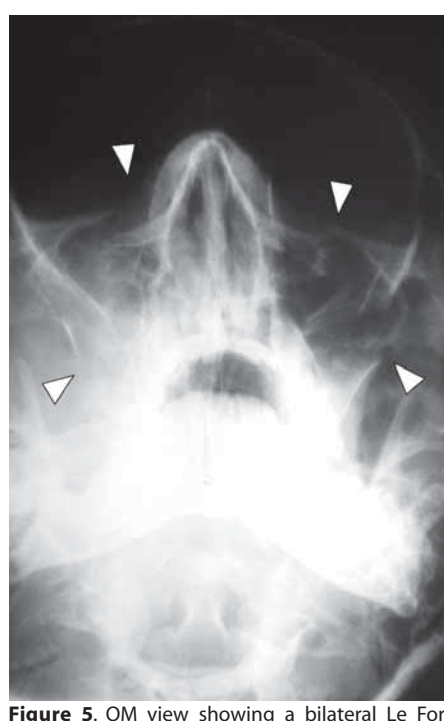
**Figure 2.** CT scan of the mandibular condyles (a: axial, b: coronal reconstruction) showing a fracture dislocation of the right mandibular condyle.



**Figure 3.** OM view showing a fracture of the right zygomatic complex. The fracture lines are indicated with arrows.



**Figure 4.** OM view showing a fracture of the right zygomatic arch.



**Figure 5.** OM view showing a bilateral Le Fort II fracture. The fracture lines are indicated with arrows.

### General hospital management

On arrival at hospital, once all life-threatening injuries have been dealt with and the patient is stable, more detailed investigation of the maxillofacial injuries can be undertaken and a treatment plan devised. Completion of all the investigations required to decide on the treatment plan may take some

time so, in the meantime, it is important to ensure that pain control is effective and that broad spectrum antibiotics are prescribed to prevent infection of the fracture site(s), since facial fractures are nearly always compound into the mouth and/or the nose and the paranasal sinuses. Patients with mid facial injuries are also advised to avoid blowing their noses in order to avoid surgical emphysema (ie

air trapped in the soft tissues). If fracture treatment is to be delayed, soft tissue injuries (lacerations) are debrided and closed as soon as possible.

### Investigations

As part of the primary survey, suspected head and cervical spine injuries will be investigated with skull and cervical spine radiographs and sometimes CT scans. Chest radiographs will also be carried out to assess chest injuries and suspected inhalation of foreign bodies, as in the case of missing teeth.

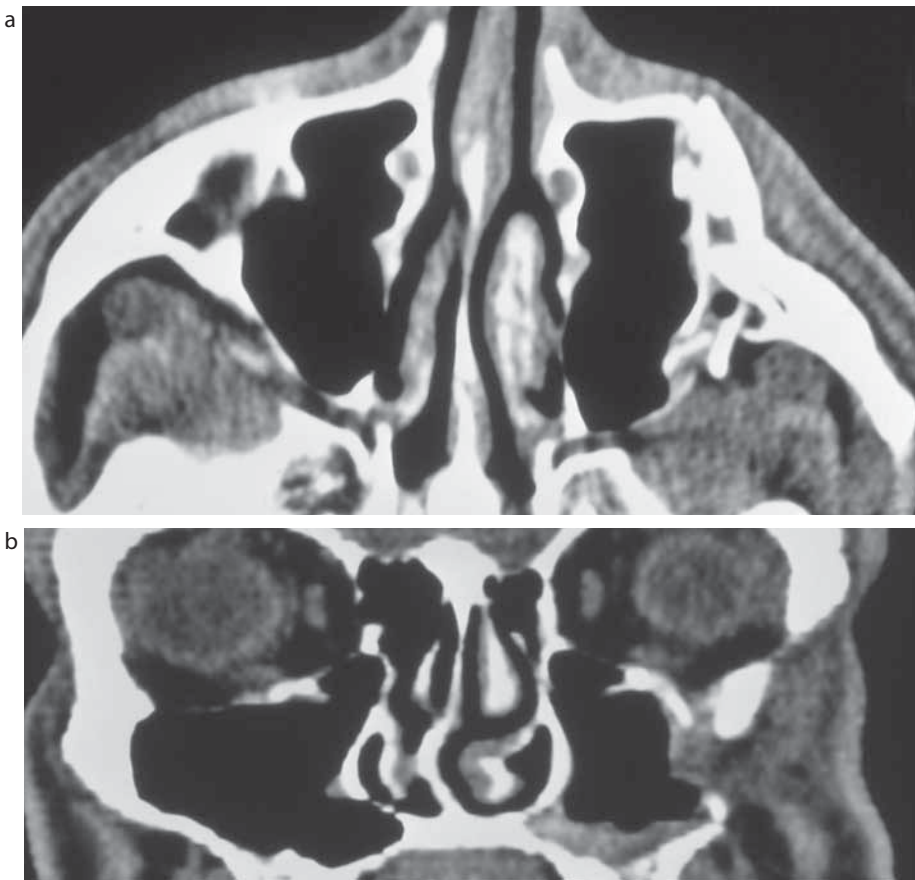
Patients with injuries confined to the face and/or fit to undergo further radiological investigations will have the following radiographs taken, depending upon the clinical findings and suspected fracture sites:

- Mandibular fractures
- Middle third injuries

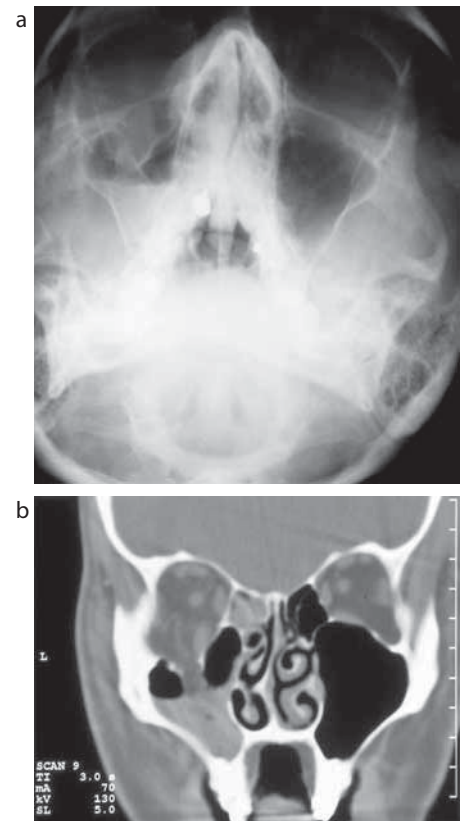
The general rule is that fractures should be imaged in at least two planes, preferably at right angles to one another.

### Mandibular fractures

An orthopantomogram (OPG) and a postero-anterior (PA) mandible x-ray show the vast majority of fractures in two planes (Figure 1). If facilities for OPG are not available, then lateral oblique radiographs should be taken. Intra-oral views (lower occlusals and periapical x-rays of traumatized teeth) may occasionally be required. CT imaging of



**Figure 6.** CT scan of the facial bones (**a**: axial, **b**: coronal reconstruction) showing a grossly displaced fracture of the left zygomatic complex.



**Figure 7.** OM view showing two typical features of orbital floor fractures: hanging drop sign and maxillary sinus fluid level, (**a**, right side). Direct coronal CT scan of the same injury (**b**).

mandibular fractures is very rarely needed but is useful for displaced condylar fractures that require surgical intervention (Figure 2).

#### Middle third injuries

Initial radiographic assessment includes occipitomental views (OM 10° and 30°) (Figures 3, 4 and 5) and a lateral view of the facial bones. Submentovertex (SMV) views are occasionally taken for the assessment of complex zygomatic arch fractures. CT imaging is often needed for midfacial injuries owing to their complexity and has become an essential investigation in the management of complex zygomatic/orbital injuries (Figure 6). Direct coronal CT imaging is advantageous for the assessment of orbital floor fractures (Figure 7), but not always possible. As in the lower facial third, intra-oral views (upper occlusals and

periapical x-rays of traumatized teeth) are sometimes needed.

Some complex injuries may be better visualized with three-dimensional CT (Figure 8). Magnetic resonance imaging has only limited application in specific areas, such as craniofacial, orbital and temporomandibular joint injuries.

#### Definitive treatment

The aim of the treatment is restoration and preservation of the pre-injury bony and soft tissue contour, occlusion and function (including the function of any motor and sensory nerve involved).

Patients with undisplaced and stable fractures and patients unfit for surgery are more appropriately treated conservatively. Pain control, prevention of infection, soft diet and nutritional support are all that are needed. Frequent

follow up assessments should be carried out to ensure that healing is progressing uneventfully.

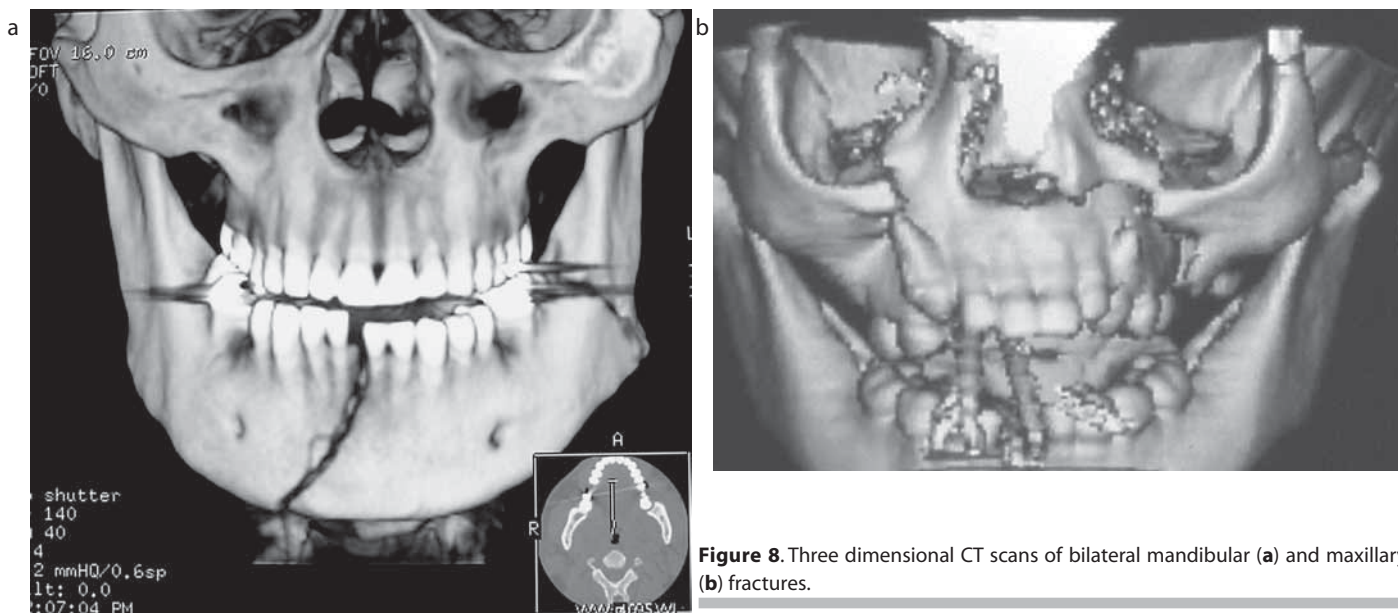
When surgical intervention is indicated, treatment, as for every fracture, has three stages:

- Reduction;
- Immobilization; and
- Rehabilitation.

The reduction and immobilization method applied for a certain type of injury cannot be standardized since it depends on several factors, such as the type of injury, coexisting injuries, pre-existing medical conditions, resources and expertise available. In the UK, the majority of facial fractures are treated with the patient under a general anaesthetic.

#### Reduction

For the facial skeleton and, in particular, for the tooth-bearing parts of



**Figure 8.** Three dimensional CT scans of bilateral mandibular (a) and maxillary (b) fractures.

the jaws, reduction must be anatomically precise. It can be closed, when the fracture is manipulated into position, or open, when the fracture is exposed through appropriately placed incisions and reduction is carried out under direct vision.

**Immobilization and fixation**

There may be several techniques used, depending on the clinical indication and often a combination of these techniques is used:

- Indirect fixation with intermaxillary fixation (IMF)

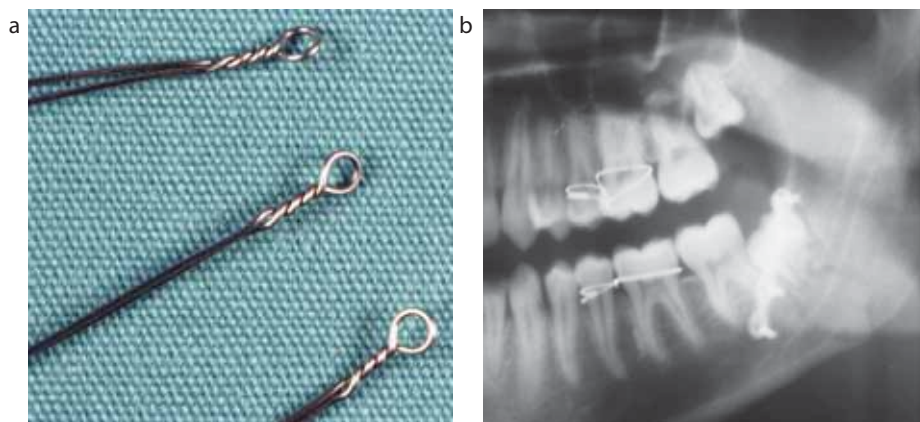
This can be employed in combination with closed reduction of mandibular fractures and, for many years, was the mainstay of mandibular fracture treatment. It is more commonly used these days to assist reduction intra-operatively when open reduction is carried out. The traditional techniques for the dentate patient are inter-dental eyelet wires with intermaxillary wires (Figure 9), direct intermaxillary dental wiring, and arch bars with intermaxillary wires or the elastic bands which are used for orthodontic traction (Figures 10, 11). A large number of other intermaxillary fixation methods have been suggested as an alternative in order to decrease the operation time and lower the risk of needle-stick injury. These include specialized intra-oral bone screws (Figure

12), *Rapid IMF* (Figure 13) and orthodontic brackets. Since these components are often left *in situ* post-operatively in case further rigid or elastic IMF is required, GDPs may encounter them if their patients attend during this period. Particularly with devices that are wired to the teeth, understandably, oral hygiene can be difficult so, during and certainly on their removal, the GDP may be required to assist in the patient's oral hygiene. Cap splints are another traditional method of treatment for jaw fractures but are rarely indicated in contemporary trauma management (Figures 14, 15). When intermaxillary fixation is required for the partially edentulous or edentulous

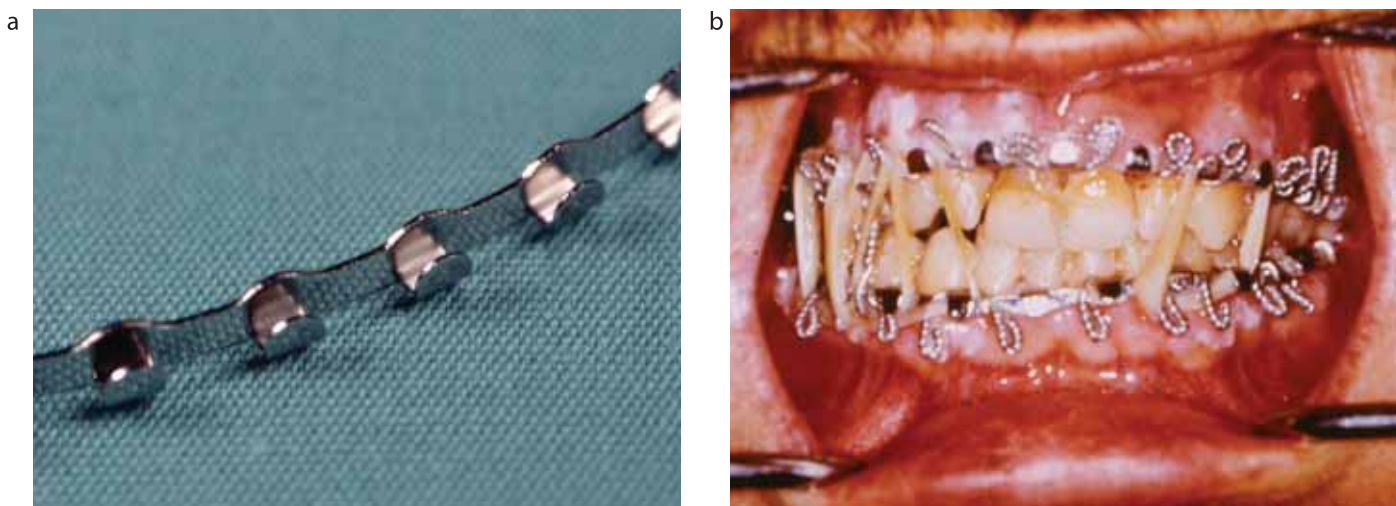
patient, Gunning type splints may be fabricated following dental model surgery at the maxillofacial laboratory (Figure 16).

■ Osteosynthesis

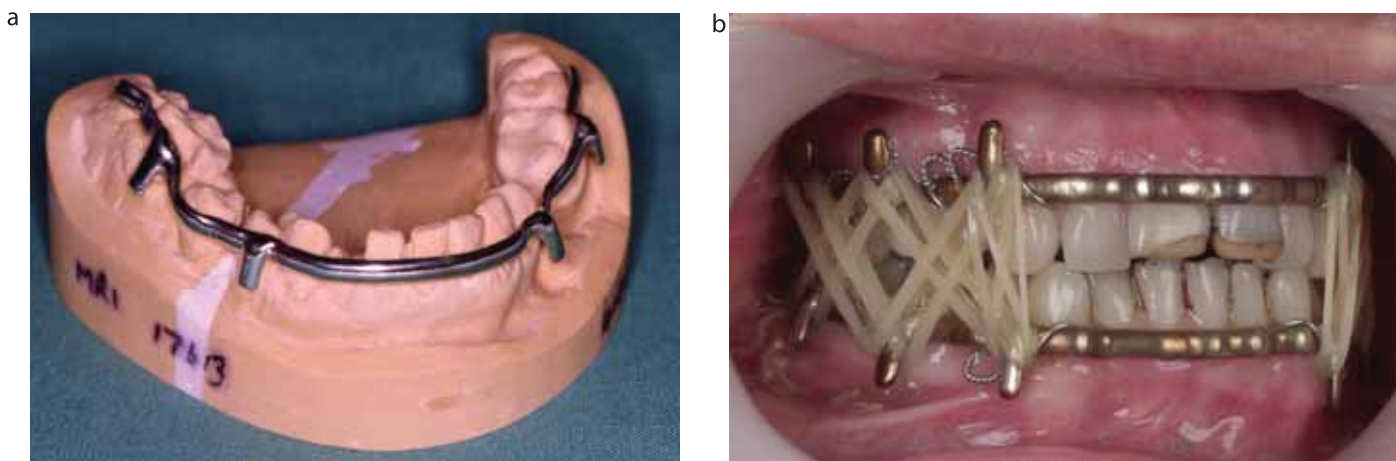
This method, carried out with bone plates and screws (Figure 17), is most commonly known as internal fixation, and is used following open reduction of facial fractures. It has become the gold standard in modern maxillofacial trauma surgery (Figure 18). The majority of surgeons use titanium systems, but the more recently introduced resorbable systems (Figure 17b) are becoming popular; however, to attain a similar strength to the titanium varieties, they are necessarily more bulky. All the



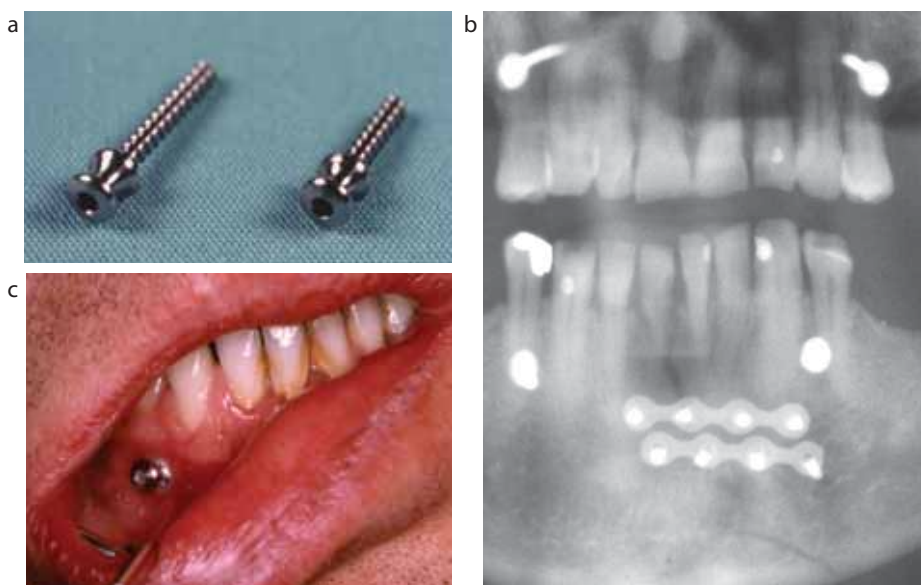
**Figure 9.** Interdental eyelet wires (a) and postoperative radiograph of a fractured mandible showing eyelet wires placed on |56 and |56 (b).



**Figure 10.** Erich pattern arch bar (a). (b) Intermaxillary traction with elastics on upper and lower arch bars.



**Figure 11.** Custom made lower arch bar (a) and intermaxillary elastic traction (b).

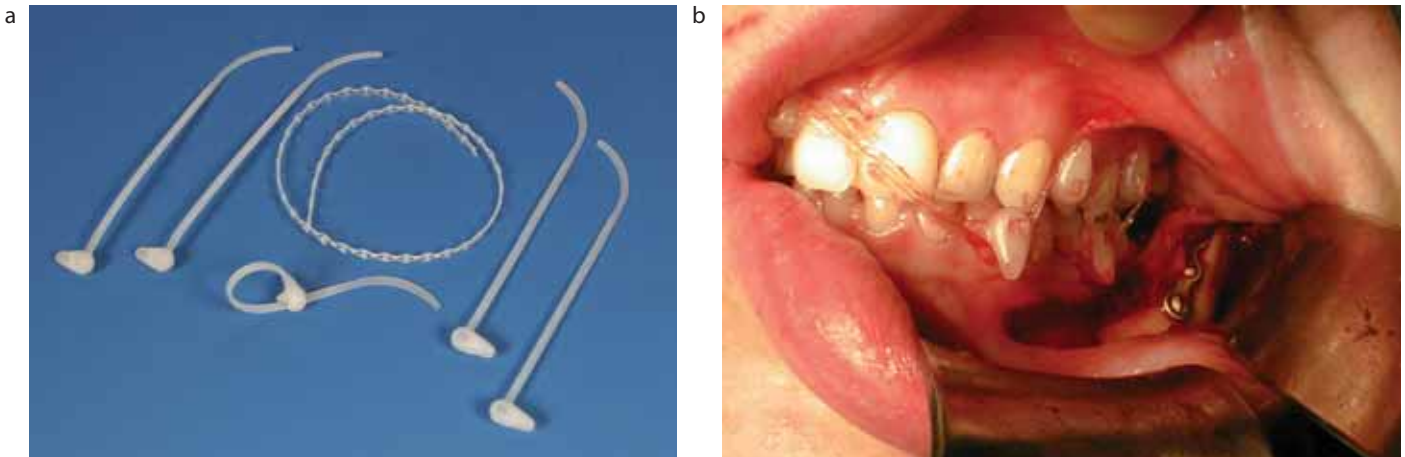


**Figure 12.** Intra-oral bone (capstan) screws for intermaxillary fixation (a, b). These are placed between canine and 1st premolar teeth on each quadrant (c).

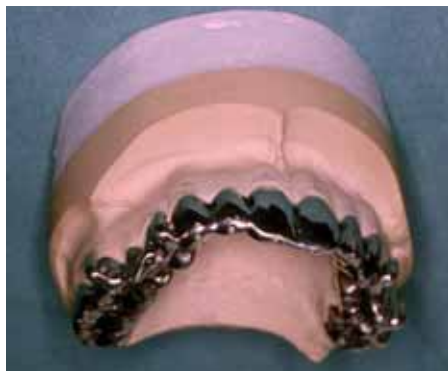plating systems currently in use provide adequate rigidity across the fracture line, and intermaxillary fixation is not necessary for the postoperative period. The patient's airway is therefore free so that he/she can have a satisfactory function and maintain oral hygiene. It is the usual intention that such plates remain in place indefinitely. They are often palpable beneath the mucosa and sometimes perforate through the mucosa, requiring their removal.

■ Wiring techniques

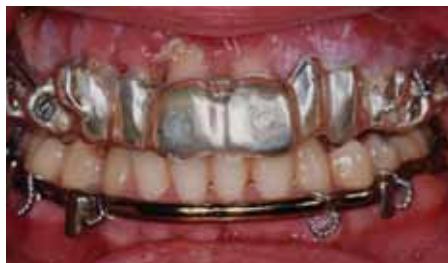These were in common use before the bone plating systems became widely available and are still occasionally indicated. Most of the techniques use soft stainless steel wires. It is worth mentioning the methods of transosseous wiring for osteosynthesis (Figure 19) and of internal suspension. The latter is used mainly for fixation of mid facial fractures. Stable areas of the facial



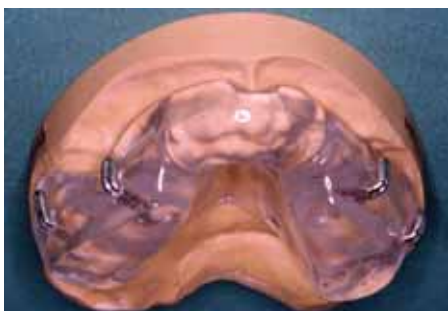**Figure 13.** Rapid IMF (Zygomatics Ltd). This system employs flexible plastic oral anchorage ties which are passed under the dental contact points. Intermaxillary traction is carried out with the use of elastic chain.



**Figure 14.** Upper silver cap splint.



**Figure 15.** Upper silver cap splint and lower custom made arch bar used for intra-operative intermaxillary fixation. The indication for the cap splint in this case is the extensive upper dento-alveolar injury.



**Figure 16.** Upper Gunning type splint.

skeleton above the fracture level are used as anchorage points and the suspension wire is usually connected to an arch bar or cap splint (Figure 20).

■ External fixation

This is another traditional method of fixation still used today on rare occasions (Figure 21). The main indications are extensively comminuted, grossly infected or pathological fractures with bone loss.

With regards to the timing of the surgical repair of facial fractures, the aim is to carry out treatment as soon as possible. Apart from patient comfort, early intervention appears to reduce the risk of secondary infection and have better structural and functional outcomes. The best time for reduction and fixation of the several types of injuries is not well defined in the literature. General medical and surgical conditions and, in particular, head injury may delay treatment of the fractures. For mid facial injuries, the time that the soft tissue swelling takes to settle, and the time required for completion of the preoperative investigations, usually prolongs the time between injury and surgery. In any case, delays over two weeks allow initial healing to progress and fracture reduction becomes difficult, often compromising the end result.

**Trauma in children and elderly patients**

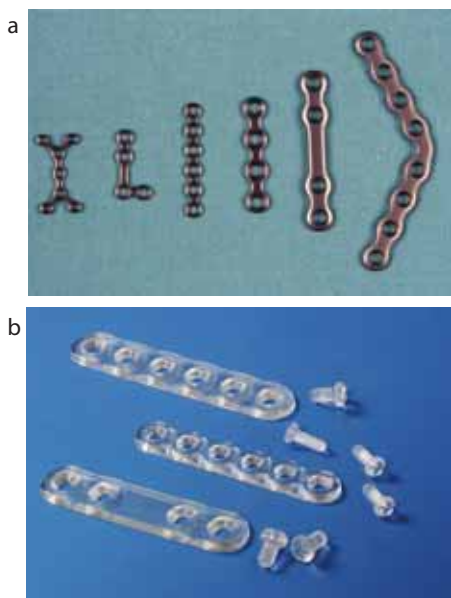
Such patients require special considerations. Children should be treated as soon as possible because of the speed of the healing process in this age group. Application of IMF is often problematic

in the primary and mixed dentition and devices such as cap splints may be indicated. When internal fixation is used the site of placement and the appropriate size of plates and screws should be carefully chosen to avoid iatrogenic injuries to the teeth. The majority of the plates have to be removed at a second stage to avoid any interference with growth. Following mandibular fractures, early mobilization should be strongly encouraged to prevent late complications from the temporomandibular joints, namely ankylosis or growth disturbances.

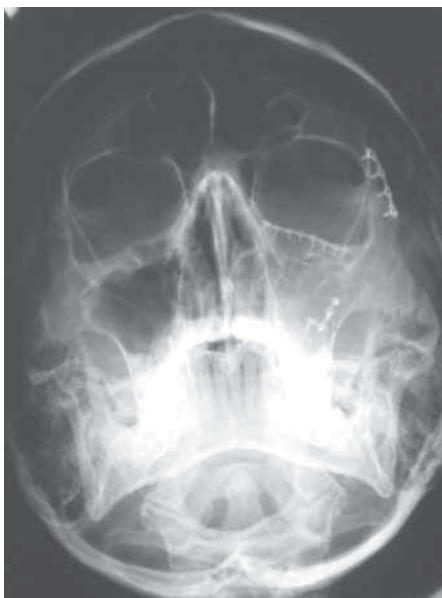Elderly patients with edentulous, especially atrophic jaws, can be very challenging to treat. This population has an increased number of risk factors for poor healing. Open reduction and direct osteosynthesis remains the method of choice. Every effort is made to maintain the blood supply of the fragments. For the edentulous mandible, when practically possible, the fixation plates are placed above the periosteum, which is where the predominant blood supply arises in edentulous mandibles. In addition, bone grafting may be needed to assist healing of fractures in atrophic areas of the mandible.

**Teeth in fractures**

Healthy teeth in the line of the fracture are generally left as they will help stabilize the fracture reduction. However, if they are fractured and/or dislocated, there



**Figure 17.** Titanium bone plates (a), KLS Martin LP) and biodegradable plates and screws (b), Inion Ltd) for osteosynthesis.

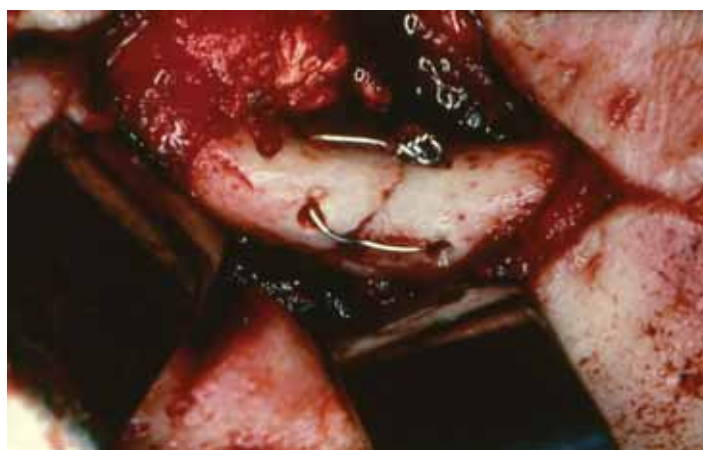

**Figure 18.** Precise anatomical repair of a left zygomatic complex fracture treated with open reduction and internal fixation (OM view).

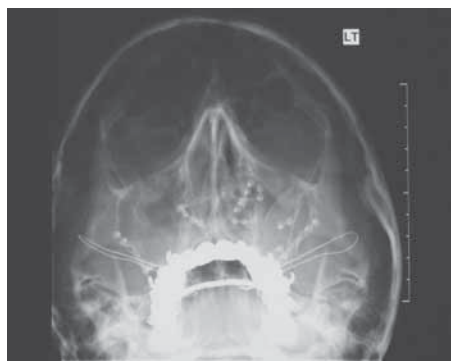After the fixation, patients generally have surprisingly little pain and oral analgesia is usually adequate. Prevention of infection requires a short course of antibiotics and, in addition, for fractures of the jaws, high levels of oral hygiene. Depending on the fracture site and the treatment method, liquidized or soft diet is advised in order to reduce the loads in the healing area for a period of four to six weeks.

### Summary

Most facial fractures are treated promptly and, whenever possible, using an open reduction and internal fixation technique. Many of the devices used either for intra-operative IMF or post-operative IMF may be left in the mouth for up to six weeks after the operation and may be encountered by GDPs.



**Figure 19.** Osteosynthesis with transosseous wire.



**Figure 20.** Internal suspension used to supplement the internal fixation for a grossly comminuted maxillary fracture. The suspension wires are passed over the intact zygomatic arches and are connected to an upper cap splint.

are associated chronic infections, such as periapical and pericoronitis, or the fracture is neglected with signs of infection, then they are usually removed. Consideration should be given to the removal of grossly carious and periodontally involved teeth and their extraction during surgery

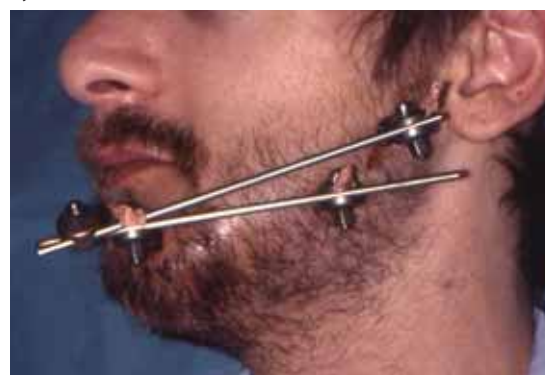is discussed with the patient preoperatively.

### Postoperative period

Following surgical repair of the facial fractures, every measure to deal with potential complications, as described in the next paper, should be taken. Attention must be paid to the principles of pain and infection control and the maintenance of adequate nutritional intake.

### Suggested reading

Pigadas N, Oliver R. Common facial fractures: 1. Aetiology and Presentation. *Dent Update* 2006; **33**: 347–356.  
 Banks P, Brown A. *Fractures of the Facial Skeleton*. Oxford: Wright, 2001.  
 Booth PW, Schendel SA, Hausamen JE. *Maxillofacial Surgery*. London: Churchill Livingstone, 1999.  
 British Association of Oral and Maxillofacial Surgeons. *Maxillofacial Trauma Guidelines*. Available at: [www.baoms.org.uk](http://www.baoms.org.uk)  
 Andreasen JO, Andreasen FM, Bakland LK, Flores MT. *Traumatic Dental Injuries: A Manual* 2nd edn. Oxford: Blackwell, 2003.



**Figure 21.** External fixation used for the treatment of an infected fracture of the mandible.