



Nick Malden

Anna D'Costa e Rego

Coronectomy of a Third Molar with Cyst Lining Enucleation in the Management of a Dentigerous Cyst

Abstract: A dentigerous cyst was treated with enucleation and coronectomy of the associated tooth to minimize the risk of inferior alveolar nerve damage, resulting from direct surgical trauma or indirectly from intra-operative or post-operative jaw fracture. Radiographic monitoring over 33 months confirmed migration of the roots through healed bone and progressive obliteration of the residual pulp canal chamber. These observations are not associated with failure of the technique but are, in fact, commonly observed in successful cases of coronectomy. A brief discussion of the risks versus benefits of this treatment modality is presented with reference to the literature available.

Clinical Relevance: In selected cases, coronectomy with cyst enucleation as a one stage procedure may reduce the risk of perioperative nerve damage.

Dent Update 2010; 37: 622–624

Contemporary management of cysts of the jaws includes marsupialization, decompression and enucleation.^{1,2} In the case of the dentigerous cyst associated with an ectopic lower third molar, the tooth may be closely associated with the inferior dental canal. The treatment modality selected will carry a variable risk of damage to the inferior dental nerve as a result of direct trauma or, indirectly, as a complication of post-operative infection or iatrogenic/pathological jaw fracture. Conventional enucleation with total tooth removal would carry the highest risk of direct or indirect trauma. Marsupialization and decompression will reduce both bone removal requirements and stress across the jaw peri/post-operatively and, with good patient compliance, these

treatment modalities have a low post-operative infection rate.² However, these procedures usually require a second operation in the event that the involved tooth is not brought into a functional position. All three above procedures allow for histological sampling of the cyst lining, but only enucleation will allow examination of the entire cyst lining. The technique of coronectomy has been described independently as a treatment option in the management of diseased lower third molars.^{3,4} The long-term fate of root apices and retained roots left *in situ* following trauma have been studied in the animal model and it would appear that vital pulp remnants within undisturbed apical fragments do not usually suffer necrosis.⁵ The blood supply is maintained from both the apical and remaining periodontal soft tissues. One factor which may reduce the incidence of pulp death is owing to the sectioned pulp remnant being more able to expand in the event of inflammation. Should the apical pulp remnant be 'extracted' at the time of coronectomy then the empty canal has been observed to fill with periodontal ligament-like tissue

which, by laying down cementum, eventually can lead to canal obliteration.⁶ These mechanisms may explain the low incidence of post-operative infection associated with the remaining apical root fragments following vital coronectomy procedures.⁷ It should be remembered, however, that any loosening of the apical portion of root can only disrupt the already compromised blood supply. Certainly, in the case of traumatic injuries of teeth, it is well recognized that the subluxed tooth has a poorer prognosis than a fractured off root portion left *in situ*.⁸ A technique is now described where an elective coronectomy with cyst lining enucleation was performed in an attempt to reduce the risk of nerve damage, and as a planned one stage curative surgical procedure.

Case report

A 37-year-old man was referred to the Department of Oral Surgery for removal of retained roots, namely UR2, UL6 and LR6. On examination the patient also had a complaint of recurrent swelling in his

Nick Malden, BDS, FDS RCP&S(Glas), Consultant in Oral Surgery and **Anna Avis D'Costa e Rego**, BDS, Senior House Officer Oral Surgery, Combined Department of Oral and Maxillofacial Surgery and Oral Medicine, Edinburgh Dental Institute and St John's Hospital, Livingston, UK.



Figure 1. Diagnostic radiograph showing unilocular cystic lesion associated with ectopic lower third molar.

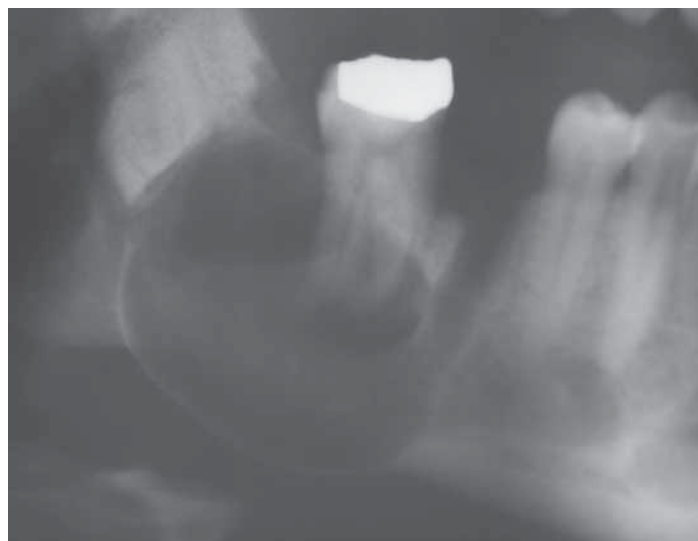


Figure 2. Post-operative view demonstrating undisplaced retained roots of ectopic lower third molar with evidence of bony access distal to LR7 to facilitate coronectomy.

lower right face. Clinical examination demonstrated retained roots, as charted, but also bony expansion in the right posterior mandibular region. No other associated symptoms or signs were noted. An orthopantomogram revealed an ectopic lower right third molar with an associated well demarcated unilocular radiolucency suggestive of a cystic lesion. The lesion appeared to extend anteriorly to the lower right first molar region, distally up into the ascending ramus of the mandible, with associated bony expansion at the inferior margin of the mandible (Figure 1). A close association of the ectopic third molar with the inferior dental canal was noted, so too were radiolucent areas indicative of thin or absent bone both buccally and lingually. A keratocyst or odontogenic tumour could not be ruled out at this stage.

Following discussion with the patient, management under day bed general anaesthesia was agreed. The patient was consented for cyst enucleation and tooth removal or coronectomy of the lower right ectopic third molar, as well as removal of retained roots of UR2, UL6 and LR6. The patient was informed of the risks of the procedure, namely, the possibility of sensory nerve damage with fracture of the mandible, also of the possible necessity of a second procedure being required. Also, if at operation the appearance was indicative of a keratocyst or tumour, then a biopsy

only would be performed and consideration given to marsupialization and/or delay of definitive treatment. At operation, access was gained distally to the LR7 via a conventional buccal muco-periosteal flap, bone removal was performed to enter what was evidently a cyst cavity and the crown of the lower right third molar visualized. The fluid cyst contents clinically supported a diagnosis of a dentigerous cyst. Coronectomy was performed via partial sectioning with a straight fissure bur in a straight handpiece, followed by the use of a Couplan's chisel rotated in the cut, a technique described by O'Riordan.³ This technique was employed to minimize the stress to and within the bone, the crown fracture being effected by concentrating the stress to within the ectopic tooth. It is accepted that careful sectioning through the whole extent of the tooth would reduce the likelihood of stress still further,⁹ however, owing to the proximity of the inferior dental canal, the former technique was employed. Perioperative/post-operative antibiotics were given in this case. The cyst lining was enucleated and sent for histopathological analysis with the crown of the tooth. The retained roots of the three erupted teeth were carefully removed to avoid undue stress to the mandible. Primary wound closure was achieved. The patient was advised to restrict to a soft diet and to avoid other stress to the lower jaw in the

post-operative period.

Follow-up was noted to be relatively trouble-free and at one month there was no pain, paraesthesia or other complaints. Histopathological diagnosis confirmed the lesion to be a dentigerous cyst. A post-operative orthopantomograph was obtained at one month (Figure 2) and further radiographs obtained at 13 months (Figure 3) and 33 months post-operatively (Figure 4). They revealed complete bony healing but noteworthy also was the continuing migration of the retained roots. Over the 33 month review period, migration of 7 mm anteriorly and 4 mm superiorly from the inferior dental canal was observed. The patient was symptom-free at last verbal contact (telephone contact at 3½ years post-operatively) but has failed to attend any further review appointments.

Discussion

Dentigerous cysts may be managed generally in three ways, enucleation with removal of the tooth, marsupialization as an initial procedure with possible removal of the tooth at a later date. Cyst decompression is another option, useful in larger cysts, again with requirement for a second definitive procedure. In the case presented, a cyst of approximately 4 cm diameter was considered amenable to enucleation.

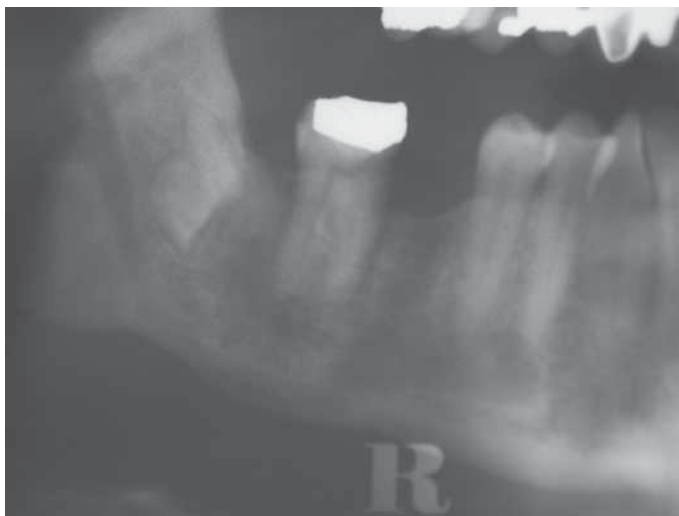


Figure 3. Post-operative review radiograph at 13 months demonstrating good bony healing and migration of retained roots antero-superiorly away from the inferior dental canal.

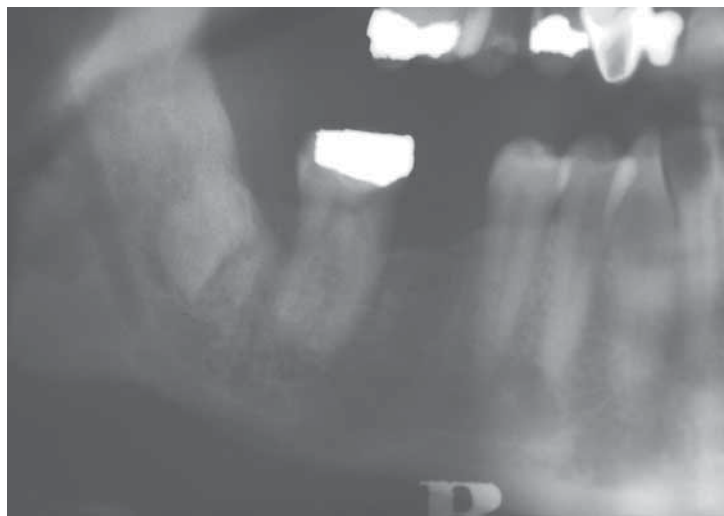

Figure 4. Further post-operative radiograph at 33 months demonstrating further favourable migration of the roots of the lower third molar with signs of partial obliteration residual pulp chamber.

However, complete removal of the ectopic tooth was considered to carry a moderate to high risk of inferior dental nerve damage. An elective coronectomy was therefore planned with complete enucleation of the cyst lining. The aim was to reduce the risk of inferior dental nerve damage, either through direct trauma or indirectly as a result of iatrogenic or post-operative mandibular fracture. A relatively common result of coronectomy was noted in the follow-up and this was migration of retained roots at an estimated rate of 0.2mm per month over a 33-month period. Radiographic signs of progressive pulp chamber obliteration were also observed. Although the root fragments were in a more favourable position for surgical removal, a second procedure has so far not been required.

Conclusion

In support of the combination treatment of coronectomy with enucleation in the management of the dentigerous cyst, the following are presented as advantages over other treatment options:

- A single procedure;
- Reduced risk of nerve damage;
- Reduced need for patient compliance in home care and follow-up;
- The entire cyst lining is made available for histopathology examination.

The disadvantages of this treatment modality include:

- Early or late post-operative infective complications necessitating a second procedure to remove the retained root portion;
- Problems resulting from the continued migration of the root portion such as intra-oral exposure, again necessitating a second surgical procedure.

It is proposed that this treatment modality should be considered as an option when discussing the management of cysts associated with ectopic teeth.

References

1. Motamedi MH, Talesh KT. Management of extensive dentigerous cysts. *Br Dent J* 2005; **198**: 203–206.
2. Enislidis G, Fock N, Sulzbacher I, Ewers R. Conservative treatment of large cystic lesions of the mandible: a prospective study of the effect of decompression. *Br J Oral Maxillofac Surg* 2004; **42**: 546–550.
3. O’Riordan BC. Coronectomy (intentional partial odontectomy of lower third molars). *Oral Surg Oral Med Oral Pathol Oral Radiol Endod* 2004; **98**: 274–280.
4. Renton T, Hankins M, Sproate C, McGurk M. A randomised controlled clinical trial to compare the incidence of injury to the inferior alveolar nerve

as a result of coronectomy and removal of mandibular third molars. *Br J Oral Maxillofac Surg* 2005; **43**: 7–12.

5. Cook RT, Hutchens LH, Burkes EJ. Periodontal osseous defects associated with vitally submerged roots. *J Periodontol* 1977; **48**: 249–260.
6. Hitchcock R, Ellis E 3rd, Cox CF. Intentional vital root transaction: a 52-week histopathological study in *Macaca mulatta*. *Oral Surg Oral Med Oral Pathol* 1985; **60**: 2–14.
7. Freedman GL. Intentional partial odontectomy: review of cases. *J Oral Maxillofac Surg* 1997; **55**: 524–526.
8. Andreasen O, Andreasen FH, Cvek M. Root fractures. In: *Traumatic Injuries to the Teeth* 4th edn. Andreasen JO, Andreasen FM, Anderson L, eds. Oxford: Blackwell Publishing, 2007: p358.
9. Pogrel MA, Lee JS, Muff DF. Coronectomy: a technique to protect the inferior alveolar nerve. *J Oral Maxillofac Surg* 2004; **62**: 1447–1452.

CPD ANSWERS October 2010

- | | |
|------------|------------|
| 1. B, D | 6. C, D |
| 2. A, B, D | 7. B, C, D |
| 3. A, C, D | 8. A |
| 4. A, C | 9. D |
| 5. A, C | 10. C |