



Ricardo I Mohammed-Ali

Jeremy Collyer and Montey Garg

# Osteomyelitis of the Mandible Secondary to Pericoronitis of an Impacted Third Molar

**Abstract:** Impacted third molars are a common reason for referral to the hospital dental service. Third molar impaction can be complicated by infection. We present two cases of osteomyelitis of the mandible developing secondary to pericoronitis of partially erupted lower third molars. One of the cases reported was recently diagnosed and treated while the other was diagnosed and treated 20 years ago. The most commonly reported pathology associated with impacted lower third molars is pericoronitis. Osteomyelitis of the mandible secondary to pericoronitis is rare.

**Clinical Relevance:** It is helpful if dental practitioners are able to distinguish between the cases of pericoronitis that need emergency referral to hospital and the cases that can be managed in practice and referred to an outpatient clinic.

**Dent Update 2010; 37: 106–108**

## Case report 1

A 22-year-old medically fit and well female was seen as a routine referral. She had been referred by her dentist eight weeks previously. The referral described partially erupted lower third molars with a diagnosis of pericoronitis of her lower left third molar at the time of the referral. In the period between the referral and being seen at our outpatient clinic, she received two courses of antibiotics for infection.

At our outpatient clinic, she presented with a left masseteric swelling, trismus and pus draining from her lower



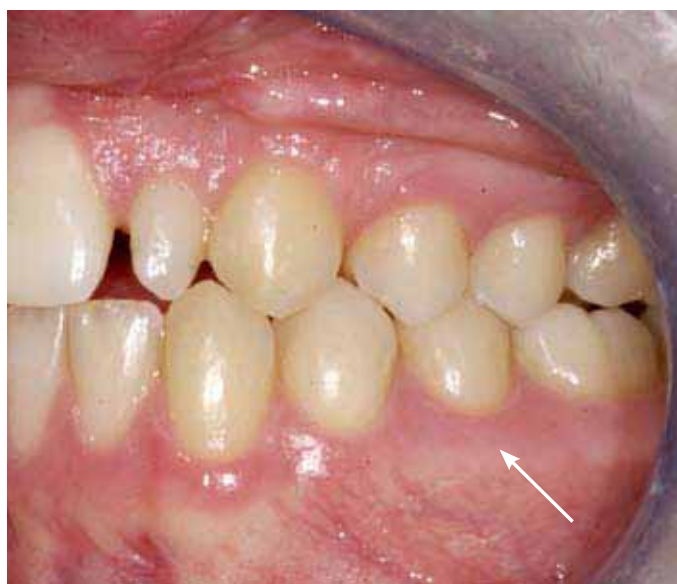**Figure 1.** OPG showing an ill-defined radiolucency associated with the left mandibular ramus and an impacted lower left third molar (white arrow).

**Ricardo I Mohammed-Ali**, DDS, MBBS, MRCS (Eng), MFDS (Eng), Specialist Registrar, Department of Oral and Maxillofacial Surgery, Sheffield Teaching Hospitals, Sheffield, **Jeremy Collyer**, FDS RCS, FRCS, Consultant, Oral and Maxillofacial Surgeon and **Montey Garg**, BDS, Senior House Officer, Department of Oral and Maxillofacial Surgery, Queen Victoria Hospital NHS Foundation Trust, East Grinstead RH19 3DZ, UK.

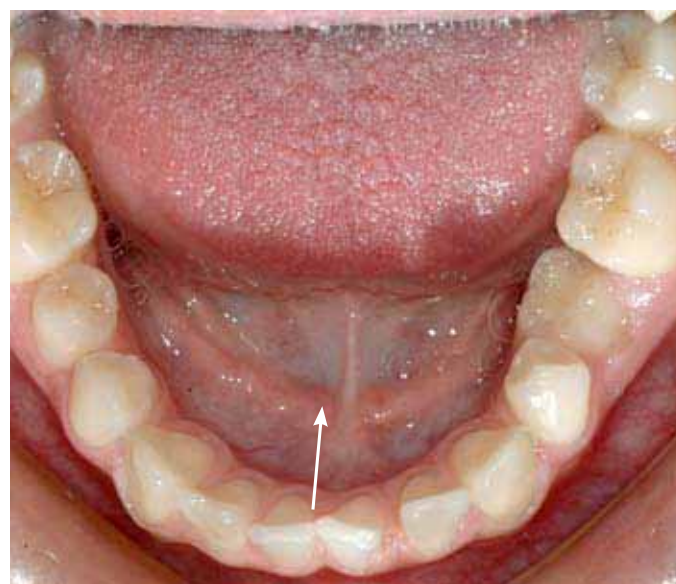
left third molar. Her inferior alveolar nerve function was normal on both sides. She was not systemically unwell at the time of presentation. Her full blood count and inflammatory markers were all within normal limits. An OPG showed an ill-defined radiolucency associated with the left mandibular ramus and an impacted lower left third

molar (Figure 1).

She was admitted to hospital directly from clinic and had emergency extraction of her lower left and upper left third molars. She also had exploration and drainage of the left submasseteric space. The mandible in the left third molar region had a moth-eaten appearance, highly suspicious of



**Figure 2.** CT scan of the left hemi-mandible showing lytic changes in the cortical bone (white arrow).



**Figure 3.** CT reconstruction of the left hemi-mandible showing lytic changes in the cortical bone (white arrow).

osteomyelitis.

Biopsies were sent for histopathological investigations and an urgent CT scan was requested. The CT of the mandible showed a lytic lesion of the ramus of the left hemi-mandible with deterioration of both inner and outer cortical plates (Figures 2 and 3). There was an ill-defined soft tissue density within the medullary cavity with pockets. Involucrum was seen along the lateral and posterior aspects of the ramus. There was noticeable swelling and thickening of the soft tissue on either side of the ramus as well as oedema of the masseter. The condyle and temporomandibular joint were unaffected.

The patient was discharged on oral clindamycin at a dose of 300 mg, 4 times a day for a month. On reviewing her six weeks following treatment, she was recovering well. Her mouth opening had improved significantly and she had no inferior dental nerve anaesthesia.

The report of the biopsy sample showed bone contaminated demineralized sections with trabeculae of woven bone of reactive appearance. In places, the medullary tissue was infiltrated by chronic inflammatory cells. Soft tissue sent with the specimen

showed fibrous connective tissue containing bundles of striated muscle showing reactive changes. There was also an area containing chronic inflammatory cells. The histopathology was highly suggestive of osteomyelitis.

### Case report 2

A 21-year-old medically fit and well female was referred by her dentist with a four week history of a swelling to the right side of the mandible in the region of the parotid gland. The dentist was uncertain about the source of this swelling at the time of referral. Three months prior to the swelling the patient had had a lower third molar extracted under local anaesthetic.

The patient was seen as an emergency and admitted to hospital. On examination, she had a tender swelling over the whole ramus of the mandible on the right side. She had trismus between the incisors to 12 mm. No cervical lymphadenopathy was found and she remained afebrile and systemically well. Her white cell count was raised to  $12.6 \times 10^3$  per microlitre and her ESR was 28.

Radiological examination revealed evidence of periosteal new bone on the lateral aspect of the ascending

ramus of the right side of the mandible. On the OPG film there was a lack of definition of the anterior border of the right ramus and the appearances were considered to be consistent with an osteomyelitis arising from the socket on the lower right third molar. A technetium bone scan showed increased activity in the right ramus of the mandible extending down from the condyle to the symphysis mentis. The appearance was in keeping with the initial diagnosis of osteomyelitis.

The patient was put on a course of ampicillin and metronidazole, with opiates being required to quell the severe pain from which she was suffering. Her antibiotics were changed to oxytetracycline and, over a two-week period, she symptomatically improved and her white cell count dropped, however, her ESR increased. The condition improved and she was discharged and followed up in clinic.

She failed to attend several clinic appointments and was admitted four months later with a recurrence of the right-sided mandibular swelling. A bone scan and further radiographs revealed that the sclerosing osteomyelitis had flared up again. She was treated conservatively and once again improved. The treatment option of long term tetracycline was

discussed with her with the need for compliance being stressed as failure to do so would have resulted in aggressive surgical debridement of the infected bone. Fourteen months after initial diagnosis, an extensive decortication of the right ramus and body of the mandible was carried out. Gentamicin beads were placed in the wound and she was put on a course of clindamycin and metronidazole for one month. A histology report confirmed the diagnosis of osteomyelitis of the mandible.

Following this the patient was treated with repeated courses of antibiotics and had multiple acute episodes. Approximately 10 years after the initial diagnosis, she had the remaining right hemi-mandible resected and an iliac crest bone graft. The bone graft failed and several months following this she had the sequestrum removed from the right-side mandible and reconstruction with a DCIA free flap. She is presently doing well.

## Discussion

Third molar impaction is one of the commonest reasons for referral to hospital dental services. Complications of third molar impaction include pericoronitis, caries, resorption and periodontal problems.<sup>1,2</sup>

Pericoronitis is the most commonly stated clinical indication for removal of an impacted third molar. Von Wowern found 10% of a sample of 130 students followed over four years developed pericoronitis.<sup>3</sup> Richardson noted that, in 76 subjects with 112 teeth, 17 lower third molars in nine subjects were removed for recurrent episodes of pericoronitis.<sup>4</sup> Pericoronitis typically occurs in young adults, presenting shortly after the eruption of the mandibular third molars. It presents as a tender swelling of the retromolar pad. Sometimes there may be ulceration from continuous trauma from the opposing maxillary molars. Pus, pain, trismus and foul taste are the common clinical features. Other clinical features include cervical lymphadenopathy, fever, leukocytosis, and malaise.<sup>5</sup>

Osteomyelitis of the body, ramus and condyle developing as a

result of odontogenic infections have been reported by Thoma.<sup>6</sup> Following review of the literature, only two cases of osteomyelitis of the mandible secondary to pericoronitis was found. This was osteomyelitis of the coronoid process in a 16-year-old<sup>7</sup> and a case of chronic osteomyelitis with proliferative periostitis affecting the mandible of a 12-year-old patient secondary to an unerupted lower third molar.<sup>8</sup> In 1961, Killey and Kay discussed the submasseteric abscess as a severe complication following dental infection and the idea of a low grade osteomyelitis developing as a result of the continued presence of a sub-periosteal abscess compressed against compact bone. They also reported osteoporotic changes and bone destruction of the ramus of the mandible occurring beneath a submasseteric abscess.<sup>9</sup>

Most of the recently reported cases of osteonecrosis of the mandible are associated with the nitrogen-containing bisphosphonates, pamidronate and zoledronic acid therapy. Bisphosphonates are strong osteoclast inhibitors that are used in the treatment of tumours with bony metastasis.

Classically, patients with osteomyelitis of the mandible experience pain, swelling over the affected side of the face, trismus and regional lymphadenopathy. The patient may be pyrexial but not usually systemically unwell. If there is involvement of the inferior dental canal, then there may be loss of sensation of the lower lip and chin. The extent of clinical features depends on the virulence of the infecting agent and immune status of the patient.

Radiographic changes may appear normal within the first three weeks of infection and become evident only after 30% of bone loss. The radiograph of Case 1 clearly shows an area of ill-defined radiolucency of the left mandibular ramus. This should have been interpreted as an aggressive infection and not as a routine referral. Radionuclear and gallium scans can be used to detect early disease activity. CT scans show bony and soft tissue involvement and are useful in the diagnosis of osteomyelitis of the mandible. The 3D reconstruction of the mandible from the CT scan of our patient clearly defines the osteomyelitic changes.

Treatment involves early diagnosis, clearing of the infected bone and surrounding infection and antimicrobial therapy.

## References

1. Stanley HR, Alattar M, Collett WK, Stringfellow HR Jr, Spiegel EH. Pathological sequelae of 'neglected' impacted third molars *J Oral Pathol* 1988; **17**: 113–117.
2. Van der Linden W, Cleaton-Jones P, Lownie M. Diseases and lesions associated with third molars. Review of 1001 cases. *Oral Surg Oral Med Oral Pathol Oral Radiol Endod* 1995; **79**: 142–145.
3. Von Wowern NV, Nielsen HO. The fate of impacted lower third molars after the age of 20. *Int J Oral Maxillofacial Surg* 1989; **18**: 277–280.
4. Richardson ME. Changes in lower third molar position in the young adult. *Am J Orthod Dentofac Orthop* 1992; **102**: 320–327.
5. Mohammed-Ali RI, McGurk M. Atypical fulminating dental infections. *Dent Update* 2008; **35**: 420–424.
6. Thoma KH. *Oral Surgery* 2 4th edn. St Louis: Mosby, 1983: pp.603, 671.
7. Reck SF, Fielding AF, Hess DS. Osteomyelitis of the coronoid process secondary to chronic mandibular third molar pericoronitis. *J Oral Maxillofac Surg* 1991; **49**: 89–90.
8. Tong AC, Ng IO, Yeung KM. Osteomyelitis with proliferative periostitis: an unusual case. *Oral Surg Oral Med Oral Pathol Oral Radiol Endod* 2006; **102**: 14.
9. Killey HC, Kay LW. The surgical problem of submasseteric abscess. *Br J Oral Surg* 1961; **1**: 55–62.

## CPD ANSWERS January/February 2010

- |            |            |
|------------|------------|
| 1. B       | 2. A, B, D |
| 3. B, C    | 4. A, C    |
| 5. A, C, D | 6. A, B, D |
| 7. C, D    | 8. A, B, D |
| 9. A       | 10. B, D   |