

## Case Report

### USE OF BUCCAL PAD OF FAT OROANTRAL FISTULA REPAIR

Tariq Javed<sup>1</sup>, Qurat ul Ain<sup>2</sup>, Faryal Saeed Abdal<sup>3</sup>

<sup>1</sup>Senior Registrar, Deptt. of Oral and Maxillofacial Surgery, UMDC, Faisalabad.

<sup>2</sup>Chief Fental Technologist, Deptt. of Prosthodontics, UMDC, Faisalabad.

<sup>3</sup>Senior Registrar, Deptt. of Oral and Maxillofacial Surgery, UMDC, Faisalabad.

#### ABSTRACT

There are many causes of oroantral fistulas but the extraction of a maxillary molar or premolar is most common cause. The other reasons could be trauma, malignant tumors, osteomyelitis, or syphilis<sup>1</sup>. When the primary fistula repair fails to heal spontaneously during first three weeks of surgery, a secondary repair may be indicated. Many techniques have been advocated for closure of fistulas like Killey & Keys (1969), Tideman et al (1986), and FGYEDI (1977). And some traditional methods of repair include buccal advancement flaps, palatal rotation and palatal transposition flaps, tongue flaps, and naso-labial flaps<sup>2</sup>. The most common technique is trapdoor technique<sup>3</sup>. The aim of this report is reporting clinical case of closing oroantral fistula through buccal fat pad.

#### CASE REPORT

A 36-year-old male patient was referred to the Dental Section of UMDC for management of oroantral fistula. Patient reported a past history of upper right first molar extraction 7 months back with a subsequent oroantral fistula formation. He had undergone several operations for fistula repair but no one succeeded.

The clinical examination revealed a fistula (1 cm diameter) at the depth of upper right first molar extraction socket. There was infection in it and patient had been using gauze to cover the opening. Panoramic x-ray did not reveal any tooth or any root in sinus.

Antibiotics and anti-inflammatory drugs were advised for 7 days along with nasal decongestant drops. At the end of medical treatment, the patient's complaints had decreased, but the dimensions of the fistula remained unchanged. Subsequently, the patient underwent a surgery to close the oroantral fistula under local anesthesia.

Starting the surgery, under local anesthesia following aseptic measures, the buccal flap

was done with a freer elevator close to the maxillary wall until the buccal fat pad was found. Then it was dissected and moved into the defect, a mild suction was started with aspirator beak, which enabled the fat elevation up to the oral cavity. The buccal fat pad was gently stuck by tissue forcep and gripped up to the fault.

After completely covering the bone defect, the buccal pad of fat was stitched to the palatal mucosa with 3.0 vicryl suture. At this moment, a buccal advancement flap was also sutured with palatal mucosa to cover the buccal fat pad. After the surgery, the patient was medicated and instructed aiming at preventing increase or decrease in maxillary sinus pressure. Patient was instructed not to blow the nose, avoid sneezing and sucking on a straw or cigarette. The postsurgical phase had no complications, and a mild loss of vestibular depth was observed.

#### DISCUSSION

The primary closure of oroantral fistulas in 48 hours presents a 90 to 95% success rate<sup>4,5</sup> but the success rate decreases after that. It is essential that the sinusitis is treated first. In case of sinusitis, the failure rate further increases. Several authors demonstrated that a three-day exposure of maxillary sinus presents a pathology through radiographic evidence.<sup>5,6</sup> The buccal pad of fat may be

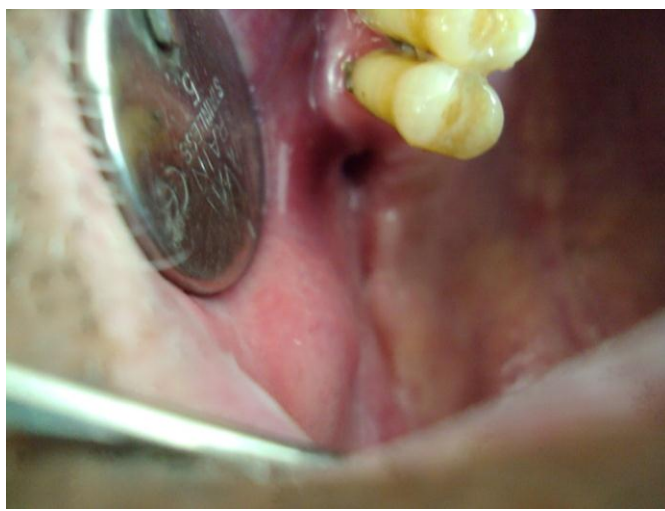-----  
Corresponding Author:

Dr. Tariq Javed,

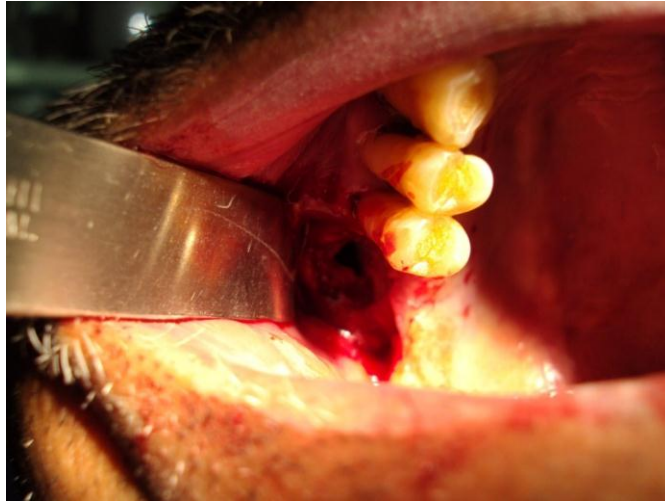
86-C, University Town, Faisalabad.

Email: dr tariq nmc@hotmail.com.  
-----

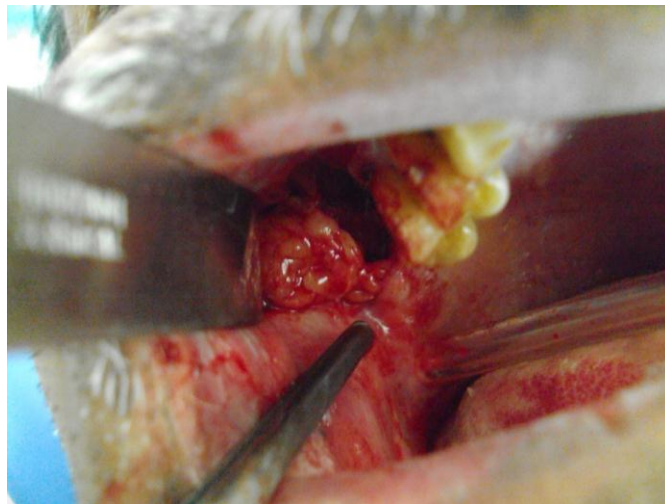
was elevated, the borders of the fistula were subperiostally incised and oroantral fistula was exposed. The posterior superior elevation



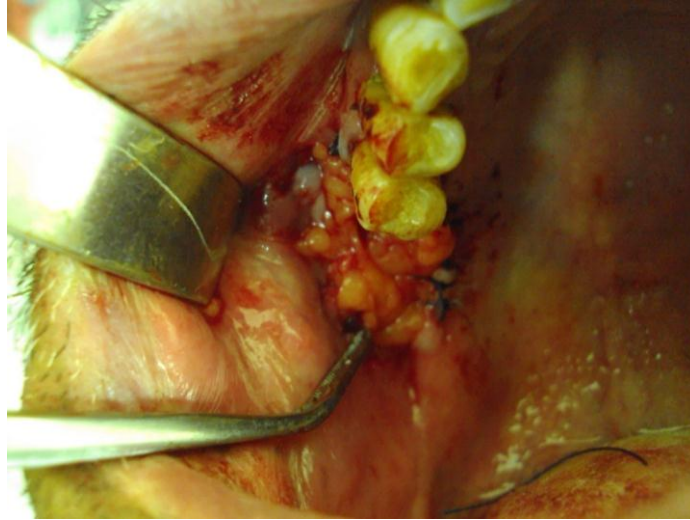**Figure 1. Oroantral fistula**



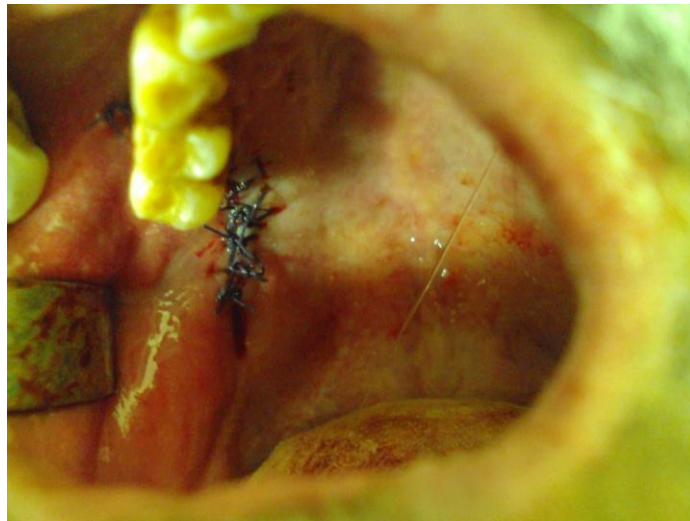**Figure 2. Buccal fat pad lift**



**Figure 3. Fistula exposition**



**Figure 4. Initial suture**



**Figure 5. Final aspect of the fistula closing**

used to close oroantral fistula and oroantral communication. Its success has been proved in the medical literature. It interferes little with vestibular depth. The buccal advancement flap interferes more with vestibular depth and cannot be used for larger oroantral fistula. The palatal flaps caused more discomfort, for the patient, than buccal pad of fat. The artificial material placement leads to exposure of the implanted material and infection and removal of implant is essential.

The buccal pad of fat causes little adverse effects on the symmetry of face. It can be used for larger oroantral fistulas with sufficient success rate. Due to its anatomical

position, it has beneficial characteristics to be used as pedicellated graft to reconstruct intraoral defects, especially in the posterior region of maxilla.

#### **CONCLUSION**

The treatment of oroantral fistula through the use of buccal fat pad is a simple and complete method which enables several uses in most of cases. The blood supply of buccal fat pad is not affected due to its displacement, once it is gripped and replaced between the flap and the maxillary wall. The operated case had no complications and fistula was cured.

**REFERENCES**

1. Principles of Oral and Maxillofacial Surgery. Ed. Peterson LJ. Lippincott Raven. Philadelphia, New York 1997, pp.223-226
2. Awand MN. Closure of oroantral fistula. *Int J Oral Maxillofac Surg.* 1998 Apr; 17(2): 110-115.
3. Bergh Van Den JPA, Bruggenkate CM, Disch FJM *et al.* Anatomical aspects of sinus floor elevations. *Clin Oral Implants Res*, 2000; 11: 256-256.
4. Eppley B and Scharoff A. Oro-nasal fistula secondary to maxillary argumentation. *Int Oral Surg.* 1984, 13:535.
5. Stajcic Z. The buccal fat pad in closure of oro-antral communication–A study of 56 cases. *J Craniomaxillofac Surg.* 1992, 20: 193.
6. Ericson S, FinneK and Persson G. A clinical radiographic review of treated oro-antral communications. *Int J Oral Surg.* 1973, 2: 185.

Submitted for publication: 23-02-2012

Accepted for publication: 01-07-2012