

9. Paoli JR, Gence E, Vives P, et al: Removal through the coronal approach of the upper wisdom teeth. Apropos of a case of bilateral migration into the temporal fossa [in French]. *Rev Stomatol Chir Maxillofac* 96:392, 1995
10. Durmus E, Dolanmaz D, Kucukkolbsi H, et al: Accidental displacement of impacted maxillary and mandibular third molars. *Quintessence Int* 35:375, 2004
11. Orr DL II: A technique for recovery of a third molar from the infratemporal fossa: Case report. *J Oral Maxillofac Surg* 57:1459, 1999
12. Shira RB: *Emergencies in Dental Practice—Prevention and Treatment* (ed 2). Philadelphia, PA, Saunders, 1972, pp 318-362
13. Kohn MN, Chase DC, Marciani RD: Surgical misadventures. *Dent Clin North Am* 17:533, 1973

J Oral Maxillofac Surg
67:1320-1322, 2009

Horner Syndrome After Temporomandibular Joint Arthroscopy: A New Complication

Julio González Martín-Moro, MD, Jesús Sastre-Pérez, MD,†
and Isabel Pena Fernández, MD‡*

A healthy 58-year-old woman had undergone arthroscopy of both temporomandibular joints because of bilateral mandibular clicks and recurrent episodes of jaw block that did not respond to nonsurgical treatment. The preoperative examination showed general restriction of mandibular motility (maximal oral aperture 26 mm, right and left lateral deviation 11 and 8 mm, respectively, protrusion 10 mm, and dental erosion without significant muscular contractures). Magnetic resonance imaging demonstrated bilateral anterior disc displacement with reduction and restricted motility of the right condyle (Fig 1).

Uneventful arthroscopy of both joints was performed under general anesthesia, after conventional nasotracheal intubation. The head was placed in a “donut,” in a natural position, not overextended, with a mild tilt. The double puncture technique was used (first, 4 mL of a mixture of lidocaine and adrenaline was injected into the superior joint space using a 23-gauge needle, followed by continuous perfusion of lactated Ringer’s solution). During the procedure, the

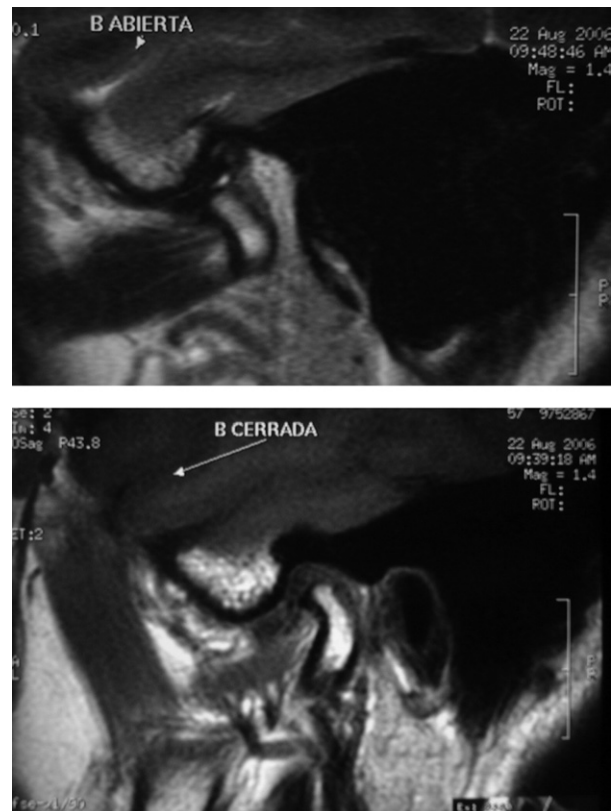


FIGURE 1. Preoperative magnetic resonance image demonstrating anterior disc displacement with reduction and restricted motility of right condyle.

González Martín-Moro, Sastre-Pérez, and Pena Fernández. Horner Syndrome, a New Complication. J Oral Maxillofac Surg 2009.

Received from Hospital Universitario de la Princesa, Madrid, Spain.

*Adjunct Doctor, Department of Ophthalmology, Division of Neuro-Ophthalmology.

†Adjunct Doctor, Department of Oral and Maxillofacial-Head and Neck Surgery.

‡Adjunct Doctor, Department of Radiology.

Address correspondence and reprint requests to Dr González Martín-Moro: Department of Neuro-ophthalmology, Hospital de la Princesa, Diego de León 62, Madrid 28006 Spain; e-mail: juliogmm@yahoo.es

© 2009 American Association of Oral and Maxillofacial Surgeons

0278-2391/09/6706-0027\$36.00/0

doi:10.1016/j.joms.2008.12.018

2.2-mm Dyonics 308 arthroscope and cannulas (Smith and Nephew, Melbourne, Australia) and the McCain instruments were used. Radiofrequency fulguration was applied over a fibrillation area. No change of

portals was necessary. Once finished, a solution of morphine chloride and bupivacaine was injected inside the articulation. Only passive and soft movements of the jaw were needed. The entire procedure was recorded, and the duration was 35 minutes.

Immediately after surgery, right eye ptosis was detected, and the patient was sent for an ophthalmologic consultation. The ophthalmologic examination showed visual acuity of 12/20 in both eyes and moderate anisocoria (right pupil 2 mm, left pupil 3 mm). Slit-lamp biomicroscopy showed mild corticonuclear sclerosis, and the fundus exploration was normal. A 2-mm ptosis was present in the right eye. Anisocoria increased in darkness (Fig 2), and presumed iatrogenic Horner syndrome was diagnosed. The patient was referred to the neuro-ophthalmology section for additional examination. Three weeks later, the suspected diagnosis (Fig 3) was confirmed by the apraclonidine test.

Discussion

Iatrogenic Horner syndrome, probably one of the most frequent variants of this classic entity, has been reported after a very wide range of surgeries and invasive head and neck procedures. It has been described after subclavian/jugular venous puncture,^{1,2} chest tube thoracostomy,^{2,3} internal jugular vein can-

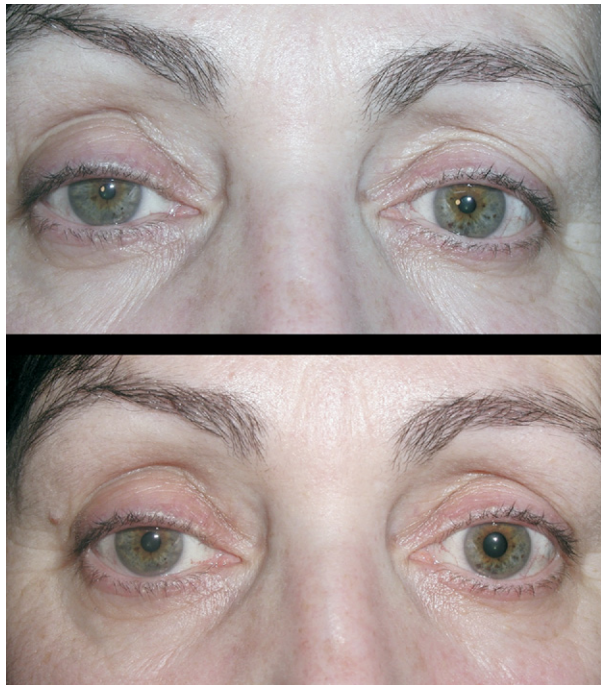

FIGURE 2. Anisocoria increased in darkness (inferior image), resulting in presumed diagnosis of iatrogenic Horner syndrome.

González Martín-Moro, Sastre-Pérez, and Pena Fernández. Horner Syndrome, a New Complication. J Oral Maxillofac Surg 2009.

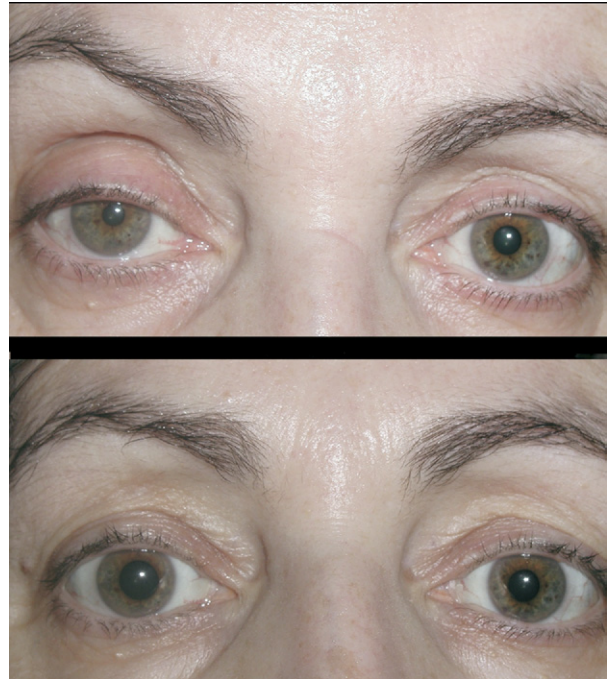

FIGURE 3. Apraclonidine test (inferior image) confirmed suspected diagnosis of Horner syndrome.

González Martín-Moro, Sastre-Pérez, and Pena Fernández. Horner Syndrome, a New Complication. J Oral Maxillofac Surg 2009.

ulation, thyroidectomy,² coronary artery bypass,² lumbar epidural anesthesia,⁴ sympathectomy for primary palmar hyperhidrosis,⁵ and carotid endarterectomy.⁶ To the best of our knowledge, this is the first report of the occurrence of Horner syndrome related to temporomandibular joint arthroscopy.

Claude Bernard Horner syndrome was first described in humans by Friedrich Horner in 1869 (it had previously been described in animals by Claude Bernard in 1852). We learned during our first years in university that it consists of ptosis, miosis, and enophthalmos; however, this enophthalmos in humans is only an apparent enophthalmos, because ptosis gives the eye a hollow look. The inferior lid also changes its position (upside-down ptosis). This reverse ptosis results from the sympathetic innervation of the retractor muscles.

Our patient referred to the appearance of the ptosis just after surgery. This close temporal relationship and the absence of other signs and symptoms made other etiologies improbable. Nevertheless, cervical magnetic resonance imaging was performed, but it did not show any abnormality. Gonzalez-Garcia et al have recently published a large review of the complications of temporomandibular joint arthroscopy, which included 5 patients with neurologic complications. Paresia of the facial nerve was the most common neurologic complication (4 patients). They also reported 1 case of a lesion of the auriculotemporal

nerve and 1 unclarified case of alteration of visual accuracy. Horner syndrome was not identified as a complication in that series.^{7,8} Because oculosympathetic palsy only generates mild ptosis and anisocoria, and complications are typically underreported in published studies, we suggest that this event could be more frequent than previously thought.

The anatomic pathway of the sympathetic route is very complex. It consists of 3 neurons, the first of which is located in the hypothalamus, and its axon descends to connect with the second neuron in the medulla (T1-T2 level). The third neuron is located in the superior cervical ganglion. The axons of this third neuron run upward again with the carotid internal artery and its branches to the eye. This high degree of complexity explains how remote lesions, located in the neck, can produce this syndrome.¹

Because the carotid artery is located at a deep level, it is difficult to explain how microincisional surgery in the temporomandibular joint could result in this complication. We believe that an unnoticed perforation of the medial wall of the articular joint, extravasation of the irrigation solution to the parapharyngeal space, and the transient compression of the carotid plexus might have been responsible for the syndrome. Horner syndrome has been described after blunt neck trauma,² and it is well established that internal compression by spontaneous carotid dissection can cause Horner syndrome. It is probable that the external compression of the sympathetic plexus that surrounds the carotid artery could produce similar damage to the sympathetic plexus.

Aqueous misdirection syndrome, a rare complication with a similar mechanism, has been described during cataract surgery. This syndrome is caused by the posterior flow of the irrigation solution into the vitreous, leading to an unexpected increase in the intraocular pressure. We hypothesized that the irrigation fluid could take unusual pathways, leading to an increase in pressure in the parapharyngeal space and to compartment syndrome. Compression of the sympathetic plexus between the high-generated external pressure and the high internal artery blood pressure could explain the damage to the nerve fibers and the interruption of the sympathetic innervation. It is also possible that the hyperextended position of the neck during surgery or the transmission of radiofrequency vibration could contribute to the plexus damage. Iat-

rogenic anesthesia due to damage of the lingual and inferior alveolar nerves has been described after fulguration; however, the sympathetic plexus is probably too deep to justify this mechanism.

The classic pharmacologic confirmation of Horner syndrome was made using the cocaine test, which consists of instilling a drop of 4% cocaine in both eyes. The cocaine inhibits the reuptake of spontaneously released noradrenaline into the synaptic cleft; thus, the normal pupil would dilate, but not the abnormal pupil (the cocaine test increases anisocoria). However, because cocaine use can result in multiple practical and legal problems, the apraclonidine test has been developed. Apraclonidine is a drug that has been used in the treatment of glaucoma for years. This drug has a very mild sympathetic activity; thus, it will not change the size of the normal pupil but will increase the size of the abnormal pupil. The normal pupil remains unchanged, and the Horner pupil dilates, reversing the anisocoria. This test will only work if denervation hypersensitivity has appeared, the reason for waiting 3 weeks to perform it.

In summary, we suggest that misdirection of the irrigation solution could have resulted in compartment syndrome and damage to the sympathetic plexus. We encourage surgeons to report their negative results and complications, because this is the only way to determine the safety of all surgical procedures.

References

1. Wilhelm H: The pupil. *Curr Opin Neurol* 21:36, 2008
2. Bell RL, Atweh N, Ivy ME, Possenti P: Traumatic and iatrogenic Horner syndrome: Case reports and review of the literature. *J Trauma* 51:400, 2001
3. Kahn SA, Brandt LJ: Iatrogenic Horner's syndrome: A complication of thoracostomy-tube replacement. *N Engl J Med* 312:245, 1985
4. Biousse V, Guevara RA, Newman NJ: Transient Horner's syndrome after lumbar epidural anesthesia. *Neurology* 51:1473, 1998
5. Cavazza S, Boccolini C, Gasparrini E, Tassinari G: Iatrogenic Horner's syndrome. *Eur J Ophthalmol* 15:504, 2005
6. Perry C, James D, Wixon C, et al: Horner's syndrome after carotid endarterectomy—A case report. *Vasc Surg* 35:325, 2001
7. Gonzalez-Garcia R, Rodriguez-Campo FJ, Escorial-Hernandez V, et al: Complications of temporomandibular joint arthroscopy: A retrospective analytic study of 670 arthroscopic procedures. *J Oral Maxillofac Surg* 64:1587, 2006
8. Tsuyama M, Kondoh T, Seto K, Fukuda J: Complications of temporomandibular joint arthroscopy: A retrospective analysis of 301 lysis and lavage procedures performed using the triangulation technique. *J Oral Maxillofac Surg* 58:500, 2000