Occurrence of Bisphosphonate-Related Osteonecrosis of the Jaw After Surgical Tooth Extraction

Giorgia Saia, MD, Stella Blandamura, MD,†*
Giordana Bettini, MD,‡ Anita Tronchet, MD,§
Andrea Totola, DMD,‖ Giorgio Bedogni, MD,¶
*Giuseppe Ferronato, MD,# Pier Francesco Nocini, MD, DDS,***
and Alberto Bedogni, MD††

Purpose: To evaluate the occurrence of bisphosphonate-related osteonecrosis of the jaw (BRONJ) in patients exposed to nitrogen-containing bisphosphonates (NBPs) requiring surgical tooth extraction.

Patients and Methods: Sixty high-risk patients exposed to NBPs underwent surgical tooth extraction with bone biopsy and were treated with a 7-day cycle of oral antibiotics and discontinuation of NBPs for 1 month. BRONJ was defined as the occurrence of any BRONJ stage (0-3) at 3, 6, or 12 months of follow-up. Inferential analysis was performed on a per-bone (maxilla and/or mandible) basis (n = 72). The time to BRONJ was calculated, and age, gender, cancer diagnosis, and baseline osteomyelitis were evaluated as potential predictors. Exact logistic regression was used to model the time-to-outcome relationship, and hazard rates were calculated from logistic probabilities.

Results: BRONJ was detected at 3 months' follow-up in 4 bones and at 6 months in 1 further bone. In the whole cohort of bones, the hazard rate of BRONJ was 5.6% at 3 months and 1.5% at 6 months. Baseline osteomyelitis was a strong risk factor for BRONJ development (odds ratio, 156.96; exact 95% confidence interval, 18.99 to ∞; exact $P < .0001$).

Conclusion: In this 12-month follow-up study, BRONJ was a rare outcome in high-risk NBP users who underwent surgical tooth extraction. Moreover, baseline osteomyelitis was a very strong risk factor for BRONJ development.
© 2010 American Association of Oral and Maxillofacial Surgeons
J Oral Maxillofac Surg 68:797-804, 2010

Bisphosphonate-related osteonecrosis of the jaw (BRONJ) is a relatively rare but potentially serious complication of treatment with nitrogen-containing bisphosphonates (NBPs). BRONJ is defined as the presence of exposed bone in the oral cavity that does not regress within 8 weeks in a patient currently or previously exposed to NBPs and who has not undergone radiation therapy in the craniofacial region. BRONJ is classified into 3 stages based on clinical signs and symptoms. Recently, a stage 0 was added to the BRONJ classifica-

*Assistant Professor, Unit of Maxillofacial Surgery, University of Padova, Padua, Italy.

†Assistant Professor, Institute of Pathology, University of Padova, Padua, Italy.

‡Resident, Section of Oral and Maxillofacial Surgery, University of Verona, Verona, Italy.

§Resident, Unit of Maxillofacial Surgery, University of Padova, Padua, Italy.

‖Section of Oral and Maxillofacial Surgery, University of Verona, Verona, Italy.

¶Senior Researcher, Clinical Epidemiology Unit, Liver Research Center, Trieste, Italy.

#Full Professor, Unit of Maxillofacial Surgery, University of Padova, Padua, Italy.

**Full Professor, Section of Oral and Maxillofacial Surgery, University of Verona, Verona, Italy.

††Assistant Professor, Section of Oral and Maxillofacial Surgery, University of Verona, Verona, Italy.

Address correspondence and reprint requests to Dr Bedogni: Section of Oral and Maxillofacial Surgery, Department of Biological and Morphological Sciences, University of Verona, Hospital GB Rossi, Piazzale LA Scuro 10, 37134 Verona, Italy; e-mail: alberto.bedogni@univr.it

© 2010 American Association of Oral and Maxillofacial Surgeons
0278-2391/10/6804-0014$36.00/0
doi:10.1016/j.joms.2009.10.026

tion to include high-risk patients without clinical evidence of necrotic bone but with nonspecific clinical signs and symptoms.[1]

Subjects treated with high-dose intravenous NBPs or with oral NBPs for more than 3 years are at greater risk of BRONJ than those from the general population.[2] Rapid bone healing after simple tooth extraction is virtually the rule in subjects not taking NBPs. However, tooth extraction is the event most commonly preceding BRONJ in clinical series.[3-5] Given the available evidence, current guidelines discourage tooth extraction in patients at high risk of BRONJ.[2] However, tooth disease, especially when accompanied by periodontal disease, favors infection, which is a known risk factor for BRONJ.[6] Thus avoidance of tooth extraction may not always be the better choice.

The aim of this study was to assess the occurrence of and the risk factors for BRONJ in high-risk patients exposed to NBPs and requiring surgical tooth extraction.

Patients and Methods

STUDY DESIGN

A cohort study was performed at the Units of Maxillofacial Surgery of the University of Verona (Verona, Italy) and University of Padova (Padua, Italy) to estimate the incidence of and the risk factors for BRONJ among high-risk NBPs users undergoing surgical tooth extraction. The local ethical committees approved the study, and all subjects gave written informed consent.

PATIENTS

Patients treated with NBPs and referred to our Units of Maxillofacial Surgery between March 2006 and March 2008 were eligible for the study if they met the following criteria: *1)* metastatic bone disease and multiple myeloma treated with high-dose intravenous NBPs or nonmalignant bone disease treated with oral NBPs for at least 3 years; *2)* 1 or more unsalvageable teeth requiring extraction; *3)* lack of bone exposure and of clinical and radiologic signs related to NBPs in the jaw where dental extraction was required; *4)* absence of previous radiation therapy of the jaws; and *5)* lack of clinical and radiologic evidence of jawbone metastases.

FIRST EXAMINATION

At the first examination, we collected the patient's clinical, drug, and dental history. NBP usage was recorded in terms of type, dosage, and duration. A measure of oral pain and discomfort was obtained by use of a visual analog scale (VAS) ranging from 0 to 10 by steps of 1. The oral cavity was inspected for all stages of BRONJ (0-3).[1] Images of the oral cavity were taken with a digital camera (Nikon Finepix S1 Pro; Nikon, Tokyo, Japan). In all patients a digital panoramic radiograph was obtained. A computed tomography (CT) scan of the jaws was also performed in patients without bone exposure but with dental or periodontal abscesses or a previous history of dental infection during NBP treatment. In these patients we looked for signs of focal sclerosis with disorganized trabeculae and poor corticomedullary differentiation, as recently suggested for subjects with clinical signs of BRONJ without bone exposure.[7] Patients with a VAS greater than 5 were given a 7-day cycle of oral antibiotics (1 g of amoxicillin–clavulanic acid 3 times per day for 3 days and 1 g 2 times per day for 4 days plus 500 mg of metronidazole 3 times per day for 4 days and 500 mg 2 times per day for 4 days). Patients with a known allergy to penicillin were given 500 mg of lincomycin 2 times per day for 7 days.

SECOND EXAMINATION

At the second examination, performed within 2 weeks of the first examination, the clinical and radiologic data were evaluated and a final diagnosis was reached. Patients without BRONJ were treated as described in the next section.

SURGICAL TOOTH EXTRACTION AND POSTEXTRACTION TREATMENT

Surgical extraction was performed with the patient under local or general anesthesia depending on the number of extractions and comorbidities and consisted of 5 steps: *1)* elevation of a mucoperiosteal envelope flap by means of bilateral release incisions; *2)* extraction of 1 or more teeth; *3)* biopsy of the alveolar bone; *4)* osteoplasty of the alveolar socket with rotating instruments; and *5)* tension-free soft tissue closure of the alveolar socket.

The postextraction treatment included *1)* a 7-day cycle of oral antibiotics (1 g of amoxicillin–clavulanic acid 3 times per day for 3 days and 1 g 2 times per day for 4 days plus 500 mg of metronidazole 3 times per day for 4 days and 500 mg 2 times per day for 4 days; patients with a known allergy to penicillin were given 500 mg of lincomycin 2 times per day for 7 days) and *2)* discontinuation of NBPs for 1 month.

BONE BIOPSY

Bone biopsy specimens were fixed in 4% formaldehyde, decalcified, and embedded in paraffin blocks. Tissue blocks were cut into 5-μm serial sections, stained with hematoxylin-eosin, and photographed (Leica DFC 280; Leica Microsystems Imaging Solutions, Cambridge, England). Specimens were examined by the same pathologist for the presence of bone inflammation and bone necrosis. Inactivation of oste-

oclasts, which is characteristic of BRONJ, was also systematically evaluated.[8] Bone was considered normal when its architecture was maintained and necrosis and inflammation were absent.

FOLLOW-UP

Patients were followed up weekly for the first month and at 3-month intervals thereafter. At each visit, a VAS score for oral pain and discomfort was obtained. Panoramic radiography and CT scans were performed at baseline and 3, 6, and 12 months as described previously.

STATISTICAL ANALYSIS

Data for 60 patients and 72 bones were available for analysis. Descriptive statistics of the cohort are given on a per-patient basis (n = 60). Continuous variables are given as median, interquartile range (IQR) (ie, difference between 75th and 25th percentile), and minimum and maximum values because of skewed distributions. Categorical variables are given as the number or percentage of patients with the characteristic of interest.

Inferential statistics are given on a per-bone basis (n = 72). The outcome was the time needed for the development of BRONJ as evaluated at 3, 6, and 12 months versus baseline. BRONJ was defined as any stage of BRONJ from 0 to 3.[1] Because follow-up was made at discrete and unequally spaced intervals, we used logistic regression to model a nonparametric time-to-event relationship and obtained hazard ratios (HRs) from the estimated logistic probabilities.[9] Because of the low number of events, we used exact logistic regression to obtain confidence intervals for the HR,[10] but we were not able to account for the fact that some subjects contributed both maxillary and mandibular bones to the analysis (ie, correlated observations).[11]

Age and cancer are known predictors of BRONJ, so we tested them as predictors of time-to-BRONJ in our cohort.[1] We also tested gender, which is not a predictor of BRONJ in available series. Lastly, we tested baseline osteomyelitis as a predictor. Predictors were coded for analysis as follows: *1)* age—baseline years/10; *2)* cancer—yes versus no; *3)* gender—male versus female; and *4)* baseline osteomyelitis—yes versus no. Because of the low number of events, we had insufficient power to test the association between time to BRONJ and the type and dose of NBP.

Results

BASELINE FEATURES OF PATIENTS

During the study period, we enrolled 60 consecutive patients who had 185 teeth extracted, 103 in the mandible and 82 in the maxilla. The characteristics of these patients are given in Table 1. The median age was 65 years, female patients (70%) were more common than male patients, and cancer-related disease (72%) was the most frequent reason for NBP use. Zoledronate (63%) and pamidronate (40%) had been the NBPs most commonly used, whereas neridronate (7%) and risedronate (3%) had been used infrequently. Bone histology at the time of tooth extraction was positive for osteomyelitis in 6 bones.

Table 1. CHARACTERISTICS OF 60 PATIENTS

Age (yr)	65 (13) [17-84]
Gender (male/female)	18/42
Cancer (yes/no)	44/16
Baseline osteomyelitis (yes/no)	4/56
Zoledronate (yes/no)*	38/22
Zoledronate cumulative dose (mg)	58 (96) [4-1,600]
Pamidronate (yes/no)*	24/36
Pamidronate cumulative dose (mg)	1,620 (2,970) [180-8,010]
Neridronate (yes/no)	4/56
Neridronate cumulative dose (mg)*	1,075 (675) [400-1,500]
Risedronate (yes/no)†	2/58
Risedronate cumulative dose (mg)	[5,040-8,695]‡

NOTE. Values for continuous variables are given as median (interquartile range) [minimum and maximum values]. Values for categorical variables are given as the number of subjects with the characteristic of interest.

*Intravenous administration.

†Oral administration.

‡Median value not given because only 2 patients contributed to the risedronate group.

Saia et al. BRONJ After Surgical Tooth Extraction. J Oral Maxillofac Surg 2010.

DEVELOPMENT AND PREDICTORS OF BRONJ

BRONJ was detected at 3 months of follow-up in 4 bones and at 6 months in 1 further bone. These bones belonged to 5 different patients aged 57 to 72 years, of whom 2 were male patients, all were cancer patients and had baseline osteomyelitis. The remaining bone with baseline osteomyelitis did not develop BRONJ during the study.

The discrete-time exact logistic regression models used to calculate the HR and to assess the role of potential risk factors for BRONJ development are given in Table 2. The HRs predicted by these models are given in Table 3. Model 1 describes the time-to-BRONJ relationship without consideration of potential predictors, and models 2 to 5 add prespecified potential risk factors (age, gender, cancer, and baseline osteomyelitis). Within the limitations imposed by the low number of events (n = 5), only baseline

Table 2. EXACT LOGISTIC REGRESSION MODELS FOR CALCULATION OF HAZARD RATES AND EVALUATION OF POTENTIAL RISK FACTORS

	Odds Ratio (Exact 95% Confidence Interval) [*P* Value]				
	Model 1	Model 2	Model 3	Model 4	Model 5
Month 3*	5.48 (0.67 to ∞)† [.120]	5.48 (0.67 to ∞)† [.120]	5.43 (0.67 to ∞)† [.121]	5.56 (0.68 to ∞)† [.118]	9.64 (0.91 to ∞)† [.06]
Month 6*	1.06 (0.03 to ∞)† [.971]	1.07 (0.03 to ∞)† [.967]	1.06 (0.03 to ∞)† [.970]	1.08 (0.03 to ∞)† [.959]	3.00 (0.08 to ∞)† [.500]
Month 12*	1 (0 to ∞) [NA]	1 (0 to ∞) [NA]	1 (0 to ∞) [NA]	1 (0 to ∞) [NA]	1 (0 to ∞) [NA]
Age (yr/10)	—	1.68 (0.68 to 5.75) [.397]	—	—	—
Male gender	—	—	1.36 (0.11 to 12.40) [NA]	—	—
Cancer	—	—	—	2.92 (0.38 to ∞) [.336]	—
Baseline osteomyelitis	—	—	—	—	156.96 (18.99 to ∞) [.0001]

*Versus month 1.
†Median unbiased estimate.
Abbreviation: NA, not available.

Saia et al. BRONJ After Surgical Tooth Extraction. J Oral Maxillofac Surg 2010.

osteomyelitis was associated with the outcome (odds ratio, 157; exact 95% confidence interval, 19 to ∞; exact $P = .0001$), so we used model 5 to calculate the HR of patients with (model 5A) and without (model 5B) baseline osteomyelitis. In the whole cohort, the hazard rate of BRONJ was 5.6% at 1 month (n = 4) and 1.5% at 6 months (n = 1). In subjects with baseline osteomyelitis, the hazard rate was 67% at 3 months of follow-up (n = 4) and 50% at 6 months (n = 1).

BONE BIOPSIES

The biopsy specimens of 54 patients were negative for osteonecrosis or osteomyelitis and showed normal bone architecture and vasculature or minor bone alterations. Such alterations were mostly bone marrow edema and fibroblastic metaplasia. Osteoclasts were scanty in these specimens. On the contrary, the biopsy specimens of 6 patients, corresponding to 2 maxillas and 4 mandibles, showed osteomyelitis. No signs of bone necrosis were detected in any specimen.

CLINICAL AND RADIOLOGIC FOLLOW-UP

Stable mucosal coverage of the alveolar socket was achieved in 50 patients (83%) 2 weeks after surgery. Surgical wound dehiscence without bone exposure was found in 10 patients (17%): 6 had stable mucosal healing within 1 month of the extraction and 1 had healing within 3 months, whereas chronic mucosal fistulas developed in 3. These 3 patients had osteomyelitis at baseline histologic analysis, and BRONJ developed in 2 at 3 months of follow-up and 1 at 6 months. The remaining 3 patients with osteomyelitis at baseline histologic analysis had no dehiscence or bone exposure at 12 months of follow-up.

The median VAS score for oral pain at 12 months of follow-up was 0 (IQR, 0; range, 0-5) versus a preoperative value of 0 (IQR, 4; range, 0-5) ($P < .0001$, Wilcoxon matched-pairs signed rank test).

NBPs were restarted 1 month after the extraction in 53 patients and 3 months after the extraction in 1 patient; they were discontinued in the 6 patients with osteomyelitis on bone biopsy. However, zoledronic acid had to be restarted 3 months later in 2 patients with breast cancer because of disease progression.

Persistence of the alveolar socket was detected at 12 months in all cases, by both panoramic radiograph and CT (Figs 1, 2). Nevertheless, panoramic radiograph failed to detect signs of BRONJ in all cases (Fig 3). CT showed progressive focal sclerosis with disorganized trabeculae and poor corticomedullary differentiation at 3 and 6 months in 5 of 6 patients with osteomyelitis on bone biopsy (Fig 4). Overall, 55 patients had no clinical and radiologic signs of BRONJ at 12 months of follow-up.

Table 3. HAZARD RATIOS AND 95% CONFIDENCE INTERVALS OBTAINED FROM MODELS 1 AND 5 OF TABLE 2

	HR (Exact 95% Confidence Interval)		
	Model 1	Model 5A (No Osteomyelitis)	Model 5B (Osteomyelitis)
Month 3*	0.0556 (0.0153 to 0.1362)	0.5000† (0.0000 to 1.0000)	0.6667 (0.2228 to 0.9567)
Month 6*	0.0147 (0.0004 to 0.0792)	0.5000† (0.0000 to 1.0000)	0.5000† (0.0126 to 0.9874)
Month 12*	0.5000 (0.0000 to 1.000)†	0.5000† (0.0000 to 1.0000)	0.5000† (0.0126 to 0.9874)

*Versus month 1.
†Median unbiased estimate.

Saia et al. BRONJ After Surgical Tooth Extraction. J Oral Maxillofac Surg 2010.

Discussion

This is the first study to evaluate the occurrence of BRONJ after surgical tooth extraction in high-risk NBP users. We showed that the occurrence of BRONJ is low, that most cases develop within 3 months of follow-up, and that baseline osteomyelitis is a strong risk factor for BRONJ.

In our series BRONJ was an uncommon outcome in high-risk NBP users who underwent tooth extraction by means of a surgical procedure aiming to separate the alveolar bone from the oral cavity. Simple tooth extraction is reported to have a higher rate of BRONJ development, and this is the reason why we prefer surgical extraction.[2] However, the efficacy and safety of surgical versus simple tooth extraction need to be tested by randomized controlled trials. If our findings are confirmed by such randomized controlled trials, surgical extraction may become a simple means of reducing the occurrence of BRONJ in high-risk NBP users in need of tooth extraction. This is especially important in view of the fact that 190 million prescriptions of bisphosphonates have been written worldwide, so the absolute number of patients with BRONJ is expected to increase.[1]

Cancer patients using intravenous NBPs have an estimated risk of BRONJ between 0.8% and 12%.[12-15] Use of oral NBPs has not been generally linked to BRONJ in patients with osteoporosis or metabolic bone disease even if an association has been recently reported in apparently healthy elderly persons.[16,17] The risk of BRONJ in osteoporotic patients treated with NBPs remains low compared with that in oncologic patients.[18,19] However, use of oral NBPs for more than 3 years is considered a risk factor for BRONJ.[1] Accordingly, the patients evaluated in this study were (mostly) users of intravenous NBPs or users of oral NBPs for at least 3 years. Current guidelines suggest that cancer patients taking high-dose intravenous NBPs should not undergo tooth extraction; alternatively, teeth should be left in place and treated by endodontic or periodontal means.[1] On the other hand, a drug holiday from 3 to 6 months has been advocated before extraction and until complete mucosal healing occurs for patients with metabolic bone disease, who have an increased risk of BRONJ.[1,20] However, NBPs have long-term skeletal retention, and it is not known whether stopping them

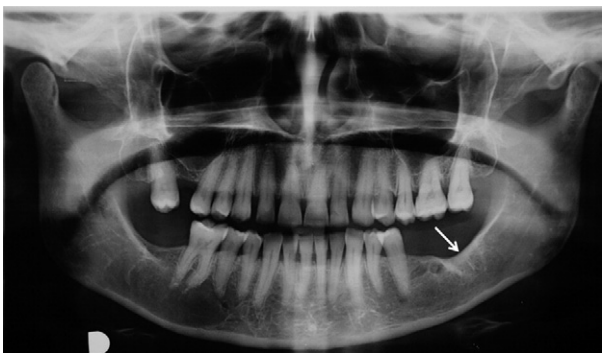

FIGURE 1. Radiologic outcome on panoramic radiograph at 12 months' follow-up in a patient with normal baseline bone histology showing persistence of alveolar socket of second molar (*arrow*).

Saia et al. BRONJ After Surgical Tooth Extraction. J Oral Maxillofac Surg 2010.

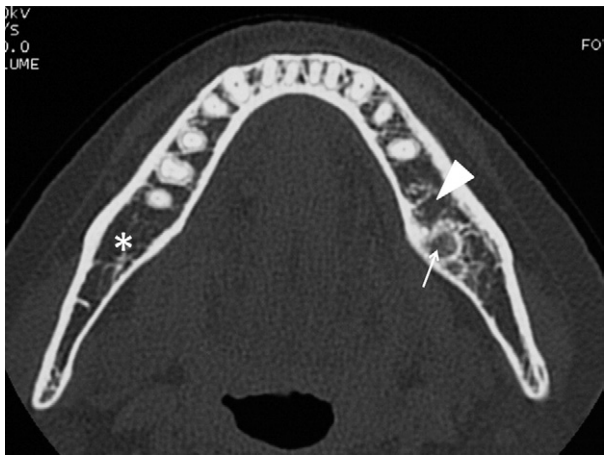

FIGURE 2. Radiologic outcome on CT scan of same patient in Figure 1 (at 12 months' follow-up) showing remnants of alveolar socket filled with fibrous tissue (*arrow*). Bone marrow adjacent to the extracted site (*arrowhead*) is normal when compared with the healthy opposite side (*asterisk*).

Saia et al. BRONJ After Surgical Tooth Extraction. J Oral Maxillofac Surg 2010.

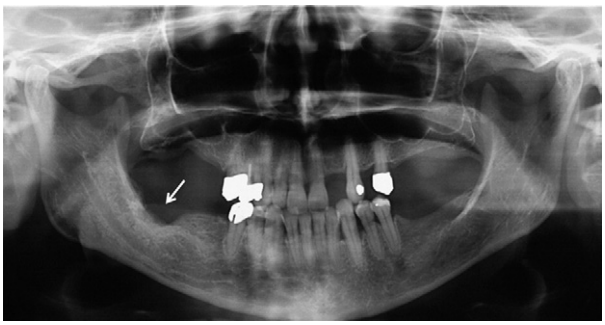

FIGURE 3. Radiologic outcome on panoramic radiograph at 6 months' follow-up in a patient with osteomyelitis at baseline bone histology showing persistent alveolar socket of third molar (*arrow*). No other signs of mandibular bone involvement are visible.

Saia et al. BRONJ After Surgical Tooth Extraction. J Oral Maxillofac Surg 2010.

before and after tooth extraction may help prevent BRONJ.[21] In our study NBPs were stopped 1 month after tooth extraction, with the aim of reducing their accumulation into the alveolar sockets. NBPs tend in fact to accumulate at sites of active bone remodeling, where the increased bone turnover may promote osteoclast migration and activation of bisphosphonates, thus interfering with bone.[22] In our study resumption of bisphosphonates in patients with normal bone histology was not associated with BRONJ at 12 months of follow-up. However, longer studies are needed to confirm this finding.

We performed biopsies of the alveolar process at the time of tooth extraction to assess its bony features and to rule out asymptomatic BRONJ. Most patients had normal or minimally altered bone histology, that is, marrow edema or fibroblastic metaplasia. None of these minor alterations had progressed to BRONJ after 12 months of follow-up. Even if bone marrow edema and fibroblastic metaplasia have been linked to bone necrosis,[23] which they promote by means of ischemia, they have not been associated with NBP use so far. Larger cohorts of patients are needed to test whether an association exists between accumulation of NBPs, these reported minor bone changes, and BRONJ development. As we have recently reported, patients with BRONJ who undergo wide jawbone resection may have histologically normal bone at the margins of resection despite accumulation of NBP.[8] The number of high-risk NBP users with normal bone biopsy findings in the present study is consistent with our previous data and adds to the hypothesis that BRONJ may be a focal disease, at least in the beginning. The demonstration of normal bone within the jaws of high-risk NBP users may open new perspectives to understanding the pathogenesis of BRONJ.

Bone biopsy specimens positive for osteomyelitis at baseline were associated with the occurrence of clinical and/or radiologic BRONJ during 12 months in all patients except 1 treated with oral bisphosphonates for osteoporosis. In this study we considered BRONJ stage 0 as the occurrence of BRONJ together with stages 1 to 3.[1] Although the risk of progression of stage 0 to higher disease stages is presently unknown, we decided to consider it as BRONJ because the patients were free of the signs and symptoms of this stage at baseline. In 2 of the 5 patients in whom BRONJ developed in this study, BRONJ stage 0 was present, and the analysis of risk factors that we present here must take this into account. We plan a further follow-up of our cohort to address the issue of the progression of stage 0 to higher stages of BRONJ. If confirmed by larger studies, a bone biopsy performed at the time of extraction may become a clinical predictor of BRONJ development.

Impairment of bone remodeling depends on the type of NBP, time of exposure, cumulative dosage, and route of administration.[22] Because oral NBPs are less potent than intravenous NBPs, their opposing effect on bone healing may be incomplete with limited jawbone involvement. This may explain why clinical and radiologic signs of BRONJ were not observed in our osteoporotic patients despite osteomyelitis at baseline histologic analysis. In this study, however, the number of events was too low to allow an evaluation of the type and duration of NBP use as a risk factor for BRONJ development.

It has been recommended that tooth extraction in high-risk NBP users should be atraumatic and not interfere with local vascularization.[24-26] Because BRONJ only developed in patients with baseline os-

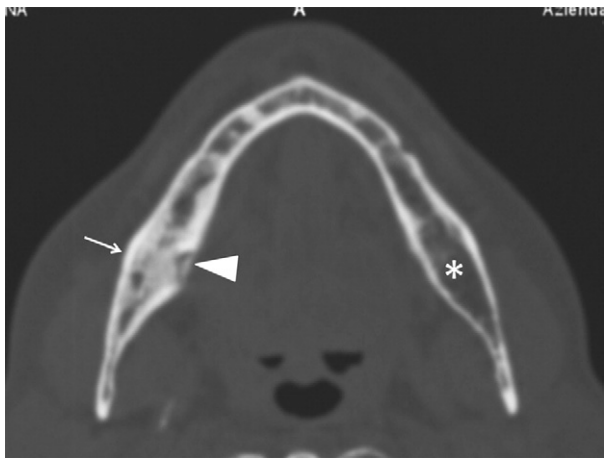

FIGURE 4. Radiologic outcome on CT scan of same patient in Figure 3 showing focal sclerosis and poor corticomedullary differentiation of bone marrow of right mandibular body (*arrow*) when compared with healthy opposite side (*asterisk*). Initial bone sequestration of the inner cortex of the right mandibular body is shown (*arrowhead*).

Saia et al. BRONJ After Surgical Tooth Extraction. J Oral Maxillofac Surg 2010.

teomyelitis, it is unlikely that the trauma induced by tooth extraction was responsible for BRONJ development. The fact that bone necrosis was not detected in any biopsy specimen at the time of tooth extraction adds to the hypothesis that BRONJ may start as an infectious disease of the bone.[27,28] Simple tooth extraction leaves the alveolar socket exposed to oral microbes, and this may favor bone infection and BRONJ development. Importantly, surgical tooth extraction yielded an excellent outcome in most patients in this study, possibly by limiting bacterial contamination of the alveolar bone by means of a complete mucosal sealing of the socket. Most of the microbes isolated from BRONJ patients are sensitive to the penicillin group of antibiotics.[1] A combination of amoxicillin–clavulanic acid and metronidazole was used in this study to protect against a broad spectrum of microbial agents including *Actinomyces*. Therapy was successfully limited to the perioperative phase, until soft tissue healing was reached.

Because BRONJ developed in a low number of patients in this study, we could not assess the role of panoramic radiograph versus CT for the early diagnosis of BRONJ. However, some considerations are in order because we collected sequential images of bone at different time points. Although the use of panoramic radiograph is advocated in high-risk BRONJ patients,[29] it never detected early jawbone involvement in the present study. These data, which need to be confirmed by larger studies, suggest that panoramic radiograph may be useful just for initial screening of high-risk NBP users. On the contrary, CT scans were able to track progressive bone modifications that led to a diagnosis of BRONJ stages 1 to 3 in 3 cases and to a diagnosis of BRONJ stage 0 in 2 cases.[30] It should be noted that all these patients had bone biopsy specimens that were positive for osteomyelitis. CT features were similar in cases with and without bone exposure in the oral cavity. Similar radiologic findings have been reported by other researchers and may be linked to the development of early BRONJ.[7] Furthermore, because CT findings were normal at 3, 6, and 12 months of follow-up in all patients with normal bone on histologic analysis, its use may be limited to patients with positive bone biopsy findings.

In conclusion, after 12 months of follow-up, BRONJ was a rare outcome in high-risk NBP users who underwent tooth extraction by use of a surgical procedure separating the alveolar bone from the oral cavity. Moreover, baseline osteomyelitis was a very strong risk factor for BRONJ development. External follow-up studies are needed to confirm these findings, and larger numbers of patients are needed to evaluate potential risk factors, especially if the occurrence of BRONJ after surgical tooth extraction is confirmed to be low.

References

1. Ruggiero SL, Dodson TB, Assael LA, et al: American Association of Oral and Maxillofacial Surgeons position paper on bisphosphonate-related osteonecrosis of the jaws—2009 update. J Oral Maxillofac Surg 67:2, 2009
2. Khosla S, Burr D, Cauley J, et al: Bisphosphonate-associated osteonecrosis of the jaw: Report of a task force of the American Society for Bone and Mineral Research. J Bone Miner Res 22:1479, 2007
3. Kyrgidis A, Vahtsevanos K, Koloutsos G, et al: Bisphosphonate-related osteonecrosis of the jaws: A case-control study of risk factors in breast cancer patients. J Clin Oncol 26:4634, 2008
4. Marx RE: Pamidronate (Aredia) and zoledronate (Zometa) induced avascular necrosis of the jaws: A growing epidemic. J Oral Maxillofac Surg 61:1115, 2003
5. Ruggiero SL, Mehrotra B, Rosenberg TJ, et al: Osteonecrosis of the jaws associated with the use of bisphosphonates: A review of 63 cases. J Oral Maxillofac Surg 62:527, 2004
6. Hoff AO, Toth BB, Altundag K, et al: Frequency and risk factors associated with osteonecrosis of the jaw in cancer patients treated with intravenous bisphosphonates. J Bone Miner Res 23:826, 2008
7. Bisdas S, Chambron Pinho N, Smolarz A, et al: Bisphosphonate-induced osteonecrosis of the jaws: CT and MRI spectrum of findings in 32 patients. Clin Radiol 63:71, 2008
8. Bedogni A, Blandamura S, Lokmic Z, et al: Bisphosphonate-associated jawbone osteonecrosis: A correlation between imaging techniques and histopathology. Oral Surg Oral Med Oral Pathol Oral Radiol Endod 105:358, 2008
9. Singer JD, Willett JB: It's about time: Using discrete-time survival analysis to study duration and the timing of events. J Educ Behav Stat 18:155, 1993
10. Mehta CR, Patel NR: Exact logistic regression: Theory and examples. Stat Med 14:2143, 1995
11. Chuang SK, Tian L, Wei LJ, et al: Kaplan-Meier analysis of dental implant survival: A strategy for estimating survival with clustered observations. J Dent Res 80:2016, 2001
12. Badros A, Weikel D, Salama A, et al: Osteonecrosis of the jaw in multiple myeloma patients: Clinical features and risk factors. J Clin Oncol 24:945, 2006
13. Bamias A, Kastritis E, Bamia C, et al: Osteonecrosis of the jaw in cancer after treatment with bisphosphonates: Incidence and risk factors. J Clin Oncol 23:8580, 2005
14. Mavrokokki T, Cheng A, Stein B, et al: Nature and frequency of bisphosphonate-associated osteonecrosis of the jaws in Australia. J Oral Maxillofac Surg 65:415, 2007
15. Zavras AI, Zhu S: Bisphosphonates are associated with increased risk for jaw surgery in medical claims data: Is it osteonecrosis? J Oral Maxillofac Surg 64:917, 2006
16. Etminan M, Aminzadeh K, Matthew IR, et al: Use of oral bisphosphonates and the risk of aseptic osteonecrosis: A nested case-control study. J Rheumatol 35:691, 2008
17. Khan AA, Sándor GK, Dore E, et al: Canadian consensus practice guidelines for bisphosphonate associated osteonecrosis of the jaw. J Rheumatol 35:1391, 2008
18. Bilezikian JP: Osteonecrosis of the jaw—Do bisphosphonates pose a risk? N Engl J Med 355:2278, 2006
19. Rizzoli R, Burlet N, Cahall D, et al: Osteonecrosis of the jaw and bisphosphonate treatment for osteoporosis. Bone 42:841, 2008
20. Marx RE, Cillo JE, Ulloa JJ: Oral bisphosphonate-induced osteonecrosis: Risk factors, prediction of risk using serum CTX testing, prevention, and treatment. J Oral Maxillofac Surg 65: 2397, 2007
21. Edwards BJ, Hellstein JW, Jacobsen PL, et al: Updated recommendations for managing the care of patients receiving oral bisphosphonate therapy: An advisory statement from the American Dental Association Council on Scientific Affairs. J Am Dent Assoc 139:1674, 2008

22. Stepensky D, Kleinberg L, Hoffman A: Bone as an effect compartment: Models for uptake and release of drugs. Clin Pharmacokinet 42:863, 2003
23. Bouquot JE, McMahon RE, Glueck CJ: Bone marrow edema: Mild or nascent variant of ischemic bone disease. J Oral Maxillofac Surg 66:205, 2008
24. Abu-Id MH, Warnke PH, Gottschalk J, et al: "Bis-phossy jaws"—High and low risk factors for bisphosphonate-induced osteonecrosis of the jaw. J Craniomaxillofac Surg 36:95, 2008
25. Marx RE, Sawatari Y, Fortin M, et al: Bisphosphonate-induced exposed bone (osteonecrosis/osteopetrosis) of the jaws: Risk factors, recognition, prevention, and treatment. J Oral Maxillofac Surg 63:1567, 2005
26. Ruggiero SL, Drew SJ: Osteonecrosis of the jaws and bisphosphonate therapy. J Dent Res 86:1013, 2007
27. Bettini G, Bedogni A, Saia G, et al: Surgical treatment of bisphosphonate-related osteonecrosis. J Craniomaxillofac Surg 36:37, 2008 (suppl 1)
28. Reid IR, Cundy T: Osteonecrosis of the jaw. Skeletal Radiol 38:5, 2009
29. Treister N, Sheehy N, Bae EH, et al: Dental panoramic radiographic evaluation in bisphosphonate-associated osteonecrosis of the jaws. Oral Dis 15:88, 2009
30. Junquera L, Gallego L: Nonexposed bisphosphonate-related osteonecrosis of the jaws: Another clinical variant? J Oral Maxillofac Surg 66:1516, 2008