

# Causes of Persistent Joint Pain After Arthrocentesis of Temporomandibular Joint

*Kosuke Honda, DDS, PhD,\* Yoko Yasukawa, DDS, PhD,†  
Masanori Fujiwara, DDS,‡ Tetsuya Abe, DDS, PhD,§ and  
Masabiro Urade, DDS, PhD||*

**Purpose:** The present study was undertaken to elucidate the factors responsible for the failure of arthrocentesis to cure persistent joint pain in patients with nonreducing articular disc displacement in the temporomandibular joint (TMJ).

**Patients and Methods:** Thirty-six patients with internal derangement of the TMJ were selected. Magnetic resonance imaging was used to examine the configuration and position of the articular discs, cortical changes, and bone marrow abnormalities in the condyle and the presence of joint effusion. Arthrocentesis was then performed, and the patients were followed for 6 weeks. The results were then classified as poor or improved.

**Results:** The effects of arthrocentesis did not depend on the configuration of the disc, disc position and motion, or bone marrow abnormalities. Joints with no or minimal amounts of joint effusion achieved a good response to arthrocentesis. Joints with erosive cortical changes of the condyle were less responsive to arthrocentesis.

**Conclusion:** Persistent joint pain after arthrocentesis is generally associated with extensive amounts of joint effusion or erosive cortical changes of the condyle.

© 2011 American Association of Oral and Maxillofacial Surgeons  
*J Oral Maxillofac Surg* 69:2311-2315, 2011

Arthrocentesis is frequently used to treat patients with temporomandibular joint (TMJ) pain or restricted mouth opening caused by nonreducing TMJ articular disc displacement.<sup>1-3</sup> This therapy is generally effective in reducing pain and improving joint function. However, some patients undergo 1 or more arthrocenteses with no apparent improvement in their symptoms, especially joint pain. The present

study was undertaken to determine the factors responsible for such failure.

## Patients and Methods

Thirty-six women (mean age  $51.9 \pm 16.3$  years, range 18 to 82), who had been diagnosed with internal derangement of the TMJ and treated at the Department of Dentistry and Oral Surgery, Hyogo College of Medicine from January 2008 to December 2009, were selected for the present study. The Ethics Committee of Hyogo College of Medicine approved the study, and all patients provided informed consent. All patients had initially been treated with nonsteroidal anti-inflammatory drugs for 3 weeks; however, their joint pain did not decrease, and no improvement in mouth opening was apparent. The initial mean pain value on a 100-mm visual analog scale (VAS) was  $60.7 \pm 15.4$ , and the initial mean range of mouth opening measured between the maxillary and mandibular incisors was  $29.7 \pm 5.6$  mm.

Magnetic resonance imaging (MRI) of the TMJ was performed with a 1.5 T MRI machine (Magnetom Vision,

Received from the Department of Dentistry and Oral Surgery, Hyogo College of Medicine, Hyogo, Japan.

\*Associate Professor.

†Assistant Professor.

‡Resident.

§Chief, Professor.

||Assistant Professor.

Address correspondence and reprint requests to Dr Honda: Department of Dentistry and Oral Surgery, Hyogo College of Medicine, 1-1, Mukogawa cho, Nishinomiya, Hyogo 663-8501, Japan; e-mail: [ko-honda@hyo-med.ac.jp](mailto:ko-honda@hyo-med.ac.jp)

© 2011 American Association of Oral and Maxillofacial Surgeons

0278-2391/11/6909-0010\$36.00/0

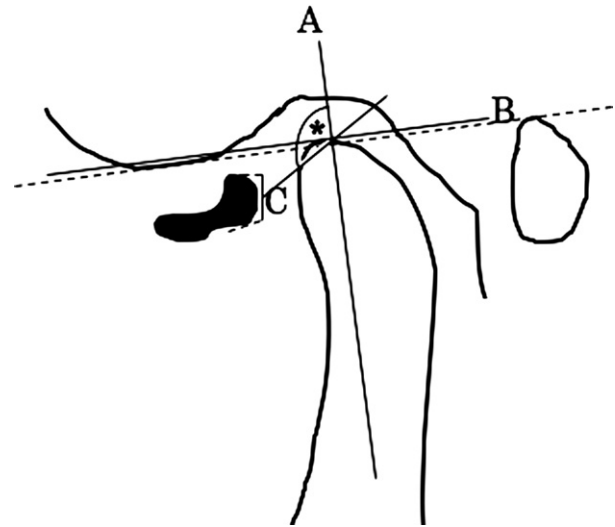
doi:10.1016/j.joms.2011.02.025

Siemens, Erlangen, Germany) using 3-mm-thick sagittal slices during centric occlusion and self-maximal mouth opening to examine the configuration and position of the articular discs at the initial consultation at our clinic. The configuration of the discs on the proton density images was divided into 5 types according to the Westesson and Bronstein classification:<sup>4</sup> biconcave, even thickness, posterior band enlargement, convex, and folded. Bony changes on the condylar surfaces were assessed by radiographic examination with TMJ radiography using panoramic equipment and MRI. These were divided into 5 types according to the classification of Peterson and Nanthaviraj:<sup>5</sup> erosion, osteophyte formation, deformity, flattening, and concavity.

Assessment of the amount of TMJ effusion was performed using T<sub>2</sub>-weighted MRI scans and classified as reported by Larheim et al<sup>6</sup> into 4 grades: no or minimal, moderate, marked, and extensive, according to the amount of joint fluid. The condyle marrow abnormalities were categorized into 3 grades: normal, marrow edema, and osteonecrosis, as defined by Larheim et al.<sup>6</sup> A “normal” bone marrow signal was identified by hyperdensity on proton density-weighted images and hypodensity on T<sub>2</sub>-weighted images; “marrow edema” was identified by hypodensity on proton density-weighted images and hyperdensity on T<sub>2</sub>-weighted images; and “osteonecrosis” was identified by hypodensity on both types of MRI scans.

The disc position in relation to the condyle was analyzed from the MRI scans in both closed and open mouth positions as follows. A perpendicular line, which ran parallel to a line drawn from the bottom of the articular eminence to the superior margin of the external auditory canal, drawn to a tangent on the center of the greatest curvature of the condylar surface, was defined as the baseline (line A). The terminal point at the junction of the posterior band of the disc and the retrodisc tissue was identified as the landmark point (point B). A line was then drawn from point B to the center of the greatest curvature of the condylar surface. The angle between this line and line A was measured to estimate the degree of disc displacement in relation to the condyle (Fig 1). All patients had anteriorly displaced, nonreducing discs. The range of disc motion was determined by calculating the difference in disc position between when the mouth was closed and open. These measurements were performed in a blind manner by 1 clinician using more than 2 consecutive sections of each MRI scan (256 × 256 dots/in.; each image was constructed of 300 pixels), all of which clearly showed the disc, condyle, and glenoid fossa.

Arthrocentesis was performed with 200 mL of physiologic saline. The VAS scores were then recorded at weekly intervals for 6 weeks after treat-



**FIGURE 1.** Measurements to assess disc position in relation to condyle on MRI scan. Line A is perpendicular to tangent B, which is parallel to the dotted line drawn from the bottom of the articular eminence to the superior margin of the external auditory canal in the center of the greatest curvature of the condylar surface. Point C is the terminal point at the junction of the posterior band of the disc and retrodisc tissue (asterisk indicates angle showing extent of disc displacement relative to condyle). Range of disc motion was determined by calculating difference in disc position between when the mouth was closed and open.

Honda et al. Persistent Joint Pain and Arthrocentesis of TMJ. *J Oral Maxillofac Surg* 2011.

ment. The response to arthrocentesis was categorized into 2 grades: “poor” and “improved.” A VAS score of less than 33 was considered “improved” and more than 33, a “poor” response.

#### STATISTICAL ANALYSIS

Pearson’s product-moment correlation *r* analysis was used to identify significant associations among the categorical factors (eg, displacement of the disc vs the range of disc motion). Chi-square tests and unpaired *t* tests were used to determine the significance of differences between the poor and improved groups for each categorical factor. Differences with *P* < .05 were considered significant.

## Results

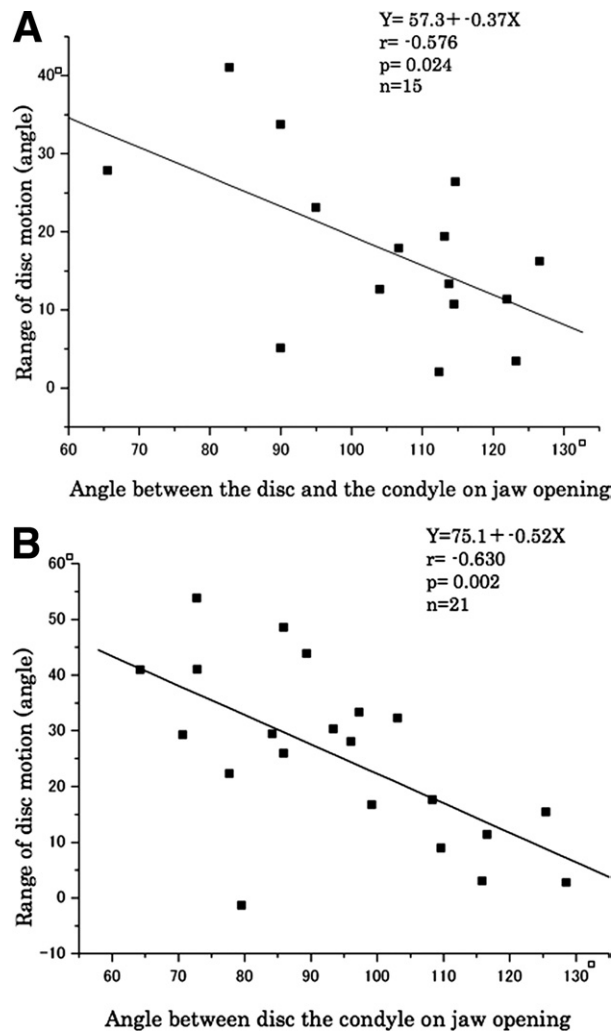
Of the 36 patients, 15, with a mean age of 51.1 ± 14.0 years, were judged to have a poor response, because they displayed no apparent improvement in their symptoms after arthrocentesis. In contrast, 21 patients, with a mean age of 52.5 ± 18.3 years, were judged to have an improved response after arthrocentesis.

The mean VAS score of the patients without a response to arthrocentesis (poor group) was 52.1 ± 15.4. The median range of mouth opening after arthrocentesis was 38.4 ± 4.3 mm in the poor group

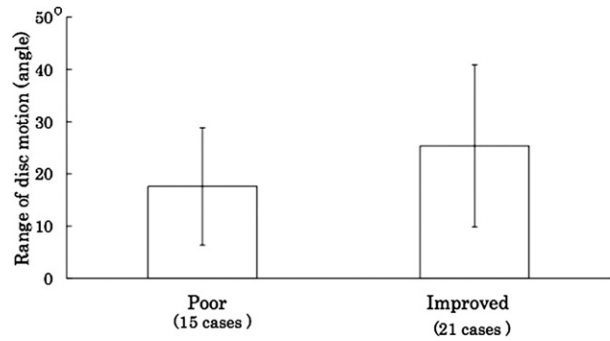
and  $39.4 \pm 3.9$  mm in the improved group. As the disc displacement angle increased, the range of disc motion tended to decrease. Statistically significant ( $P < .05$ ) correlations were observed between these values in both the poor and improved groups (Fig 2). However, no significant difference was found in the range of disc motion between these 2 groups (Fig 3).

A favorable clinical response to arthrocentesis was achieved in the patients with no or minimal joint effusion; significantly greater ( $P < .05$ ) than that achieved for those with other grades of joint effusion (Fig 4).

The percentage of patients with erosive condylar surface bone changes was significantly less ( $P < .01$ ) in the improved group than in the poor group. In contrast, the percentage of patients whose condylar surface changes were diagnosed as flattening was



**FIGURE 2.** Relationship between disc position relative to condyle and range of disc motion in A, poor and B, improved groups. Honda et al. Persistent Joint Pain and Arthrocentesis of TMJ. J Oral Maxillofac Surg 2011.



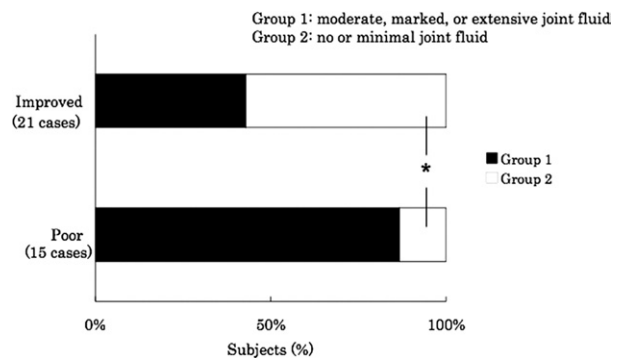
**FIGURE 3.** Comparison of range of articular disc motion between poor and improved groups. Statistically significant ( $P < .05$ ) correlations were not observed between the 2 groups. Honda et al. Persistent Joint Pain and Arthrocentesis of TMJ. J Oral Maxillofac Surg 2011.

significantly greater ( $P < .01$ ) in the improved group than in the poor group (Fig 5).

No difference was found in the percentage of improved patients among the 3 categories of condylar bone marrow alterations (Fig 6).

**Discussion**

Arthrocentesis was introduced by Nitzan et al<sup>1</sup> as a modification of arthroscopic surgery in 1991. The favorable effects of this procedure have been reported in several studies.<sup>7-9</sup> In particular, arthrocentesis produces great improvement in patients with mouth opening limitations resulting from nonreducing articular disc displacement, eliminating joint symptoms and removing adhesive lesions in the synovial cavity. Additionally, arthrocentesis is considered to have lower surgical risk and costs less than other arthroscopic procedures. However, although good clinical results with arthrocentesis have been reported, the success rates and baseline period after treatment in these reports have varied. Therefore, additional studies are



**FIGURE 4.** Relationship between efficacy of arthrocentesis and joint effusion. \*Significantly different at  $P < .01$ ,  $\chi^2$  test. Honda et al. Persistent Joint Pain and Arthrocentesis of TMJ. J Oral Maxillofac Surg 2011.

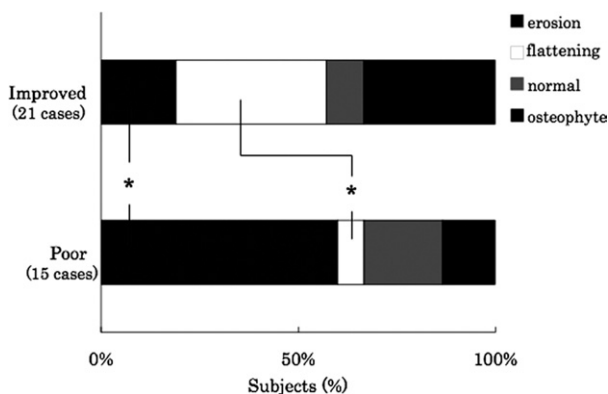
required to clarify the effects of arthrocentesis, and it is necessary to evaluate, not only its clinical efficacy, but also the factors responsible for any failures.

The present study was performed to determine which aspects of TMJ internal derangement predict an unsatisfactory prognosis after arthrocentesis and which factors affect the success of this procedure. As a first step in our analysis, we examined whether disc abnormalities correlated with the effects of arthrocentesis. Our results led us to conclude that the success rate of arthrocentesis does not depend on the configuration of the disc, amount of disc displacement, or range of disc motion between mouth closing and opening.

Joint effusion and bone marrow alterations have been reported as clinical factors that affect the symptoms of internal derangement of the TMJ.<sup>10</sup> Our results showed that the grade of joint effusion was also related to the therapeutic effect of arthrocentesis. Patients with no or a minimal amount of abnormal joint fluid had a good response to arthrocentesis. Larheim et al<sup>6</sup> indicated a relationship between MRI signals of joint effusion and inflammatory reactions in the TMJ. It was considered that the curative ability of arthrocentesis depended on the inflammatory state of the TMJ, and it was suggested that the indications for arthrocentesis should be restricted by the grade of joint effusion. However, MRI signals relating to bone marrow abnormalities do not always agree with a patient's symptoms. Previous reports have shown that the amount of bone marrow edema does not always reflect the pathologic state of the mandibular condyle.<sup>11-13</sup> In the case of the TMJ, Larheim et al,<sup>12</sup> in a clinical MRI study, reported that joint effusion and condylar bone marrow abnormalities were significant pain-increasing factors. Sano et al<sup>13</sup> also reported that the degree of pain in the joints with abnormal bone

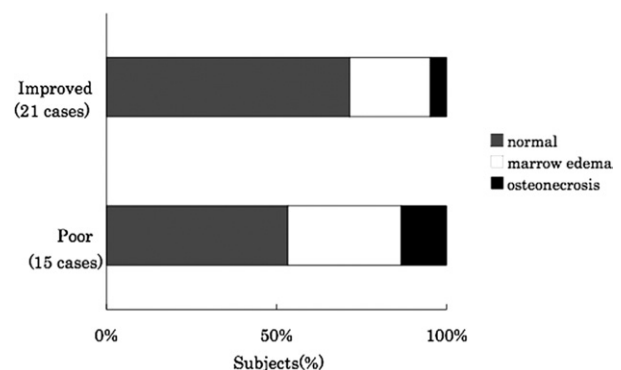
marrow was greater than in the joints with normal bone marrow signals on MRI scans. However, in our study, no statistically significant evidence was found that the joints with bone marrow abnormalities demonstrated a poor response to arthrocentesis. Arthrocentesis relieves joint symptoms in the TMJ by lysis and lavage of the synovial cavity. Accordingly, this procedure might have less beneficial effects on intra-bony pathologic features, such as bone marrow abnormalities, despite providing good improvement in the patients with osteoarthritis and/or cortical bone abnormalities of the condyle.

Interestingly, the results of the present study showed that joints with erosive cortical changes in the condyle were less responsive to arthrocentesis. It has been suggested that such bony changes should be considered as an accurate sign of a pathologic lesion from both a radiologic and clinical point of view.<sup>14</sup> We have taken a similar view. We have previously noted that radiographically demonstrated erosive bony changes of the condylar surface tend to induce joint pain and a high frequency of joint sounds.<sup>15,16</sup> In contrast, in the present study, a favorable response to arthrocentesis was achieved in the joints with bony condylar surface changes that were diagnosed as flattening. Flattening is regarded as an adaptive bony change with fewer accompanying symptoms.<sup>14</sup> Our previous study also showed that the range of motion of the condyle between the mouth closed and open positions in the joints with erosive condylar bone changes was smaller than in the joints with adaptive bone changes such as flattening.<sup>16</sup> Viewed in this light, it is quite likely that joints with pathologic condylar surface bone changes have an increased tendency to be affected by friction between the condylar surface and the articular disc than joints with adaptive bone changes and that the increased friction could lead to joint pain associated with jaw movement disturbance. Arthrocentesis acts to abolish such friction



**FIGURE 5.** Relationship between efficacy of arthrocentesis and bony changes on condylar surfaces. \*Significantly different at  $P < .05$ ,  $\chi^2$  test.

Honda et al. Persistent Joint Pain and Arthrocentesis of TMJ. *J Oral Maxillofac Surg* 2011.



**FIGURE 6.** Relationship between efficacy of arthrocentesis procedure and condylar bone marrow abnormalities.

Honda et al. Persistent Joint Pain and Arthrocentesis of TMJ. *J Oral Maxillofac Surg* 2011.

when adaptive changes. However, pathologic condylar surface bone changes such as erosion predispose the TMJ to friction and adhesion in the synovial cavity after arthrocentesis, despite the use of an occlusal splint.

The present study showed that the effects of arthrocentesis do not depend on the configuration of the disc, the disc position, or the range of the disc motion between the closed and open mouth positions. Moreover, no statistically significant evidence was found that joints with bone marrow abnormalities or with a minimal amount of joint effusion have a poor response to arthrocentesis. In contrast, the joints with erosive cortical changes in the condyle were less responsive to arthrocentesis.

## References

1. Nitzan DW, Dolwick MF, Martinez GA: Temporomandibular joint arthrocentesis: A simplified treatment for severe, limited mouth opening. *J Oral Maxillofac Surg* 49:1163, 1991
2. Frost DE, Kendell BD: The use of arthrocentesis for treatment of temporomandibular joint disorders. *J Oral Maxillofac Surg* 57:583, 1999
3. Barkin S, Weinberg S: Internal derangements of the temporomandibular joint: The role of arthroscopic surgery and arthrocentesis. *J Can Dent Assoc* 66:199, 2000
4. Westesson PL, Bronstein SL: Internal derangement of the temporomandibular joints: Morphologic description with correlation to the joint function. *Oral Surg Oral Med Oral Pathol* 59:323, 1985
5. Peterson A, Nanthaviroj S: Radiography of the temporomandibular joint utilizing the transmaxillary projection. *Dentomaxillofac Radiol* 4:76, 1975
6. Larheim TA, Westesson PL, Sano T: Grading of temporomandibular joint fluid: Association with disk displacement categories, condyle marrow abnormalities and pain. *Int J Oral Maxillofac Surg* 30:104, 2001
7. Carvajal WA, Laskin DM: Long-term evaluation of arthrocentesis for the treatment of internal derangements of the temporomandibular joint. *J Oral Maxillofac Surg* 58:852, 2000
8. Dimitroulis G, Dolwick MF, Martinez GA: Temporomandibular joint arthrocentesis and lavage for the treatment of closed lock: A follow up study. *Br J Oral Maxillofac Surg* 33:23, 1995
9. Murakami K, Hosaka H, Moriya Y, et al: Short-term treatment outcome study for the management of temporomandibular joint of closed lock: A comparison of arthrocentesis to nonsurgical therapy and arthroscopy lysis and lavage. *Oral Surg Oral Med Oral Pathol* 80:253, 1995
10. Emshoff R, Brandlmaier I, Gerhard S, et al: Magnetic resonance imaging predictors of temporomandibular joint pain. *J Am Dent Assoc* 134:705, 2003
11. Sano T, Westesson PL, Larheim TA, et al: Osteoarthritis and abnormal bone marrow of the mandibular condyle. *Oral Surg Oral Med Oral Pathol Oral Radiol Endod* 87:243, 1999
12. Larheim TA, Katzberg RW, Westesson PL, et al: MR evidence of temporomandibular joint fluid and condyle marrow alterations: Occurrence in asymptomatic volunteers and symptomatic patients. *Int J Oral Maxillofac Surg* 30:113, 2001
13. Sano T, Westesson PL, Larheim TA, et al: The association of temporomandibular joint pain with abnormal bone marrow in the mandibular condyle. *J Oral Maxillofac Surg* 58:254, 2000
14. Sato H, Fujii T, Yamada N, et al: Temporomandibular joint osteoarthritis, a comparative clinical and tomographic study pre- and post-treatment. *J Oral Rehabil* 21:383, 1994
15. Honda K, Natsumi Y, Urade M: Relationship between degenerative bone changes of condylar surface and articular disc disorders in symptomatic osteoarthritis of temporomandibular joints. *Oral Sci Int* 1:65, 2004
16. Honda K, Natsumi Y, Urade M: Correlation between MRI evidence of degenerative condylar surface changes, induction of articular disc displacement and pathological joint sounds in the temporomandibular joint. *Gerodontology* 25:251, 2008