

Excision of an atypical case of palatal bone exostosis: a case report

Fernando V. Raldi, Rodrigo D. Nascimento, José R. Sá-Lima, Caio A. Tsuda
and Michelle B. de Moraes

Department of Diagnosis and Surgery, São José dos Campos Dental School, São Paulo State University,
SP, Brazil

(Received 6 December 2007 and accepted 28 March 2008)

Abstract: Bone exostosis has long been described in the literature, appearing in most cases as a *torus palatinus* or *mandibularis*. These two variations are relatively common and affect approximately 30% of the world's population. Incidence is even higher when human skulls are examined *post mortem*, indicating that in some cases the exostosis is small and cannot be seen under the soft tissue. Removal of an exostosis is usually associated with the construction of a prosthesis, but in rare cases such as the present, the lesion enlarges enough to affect speech and feeding. Few studies have reported the removal of such a large exostosis, and all were conducted in a hospital environment. In this case, complete removal was successfully conducted in an ambulatory clinic under local anesthesia. (J. Oral Sci. 50, 229-231, 2008)

Keywords: bone formation; alveoloplasty; pathology oral.

Introduction

Bone exostosis, also known as hyperostosis or hamartoma is described as a non-pathologic, localized bony protuberance that arises from the cortical bone or sometimes from the spongy layer. It is most common in the mandible (1). The exact etiology of exostosis has not yet been elucidated, but some authors believe it is caused by the

interaction between genetic and environmental factors (2,3). The gene responsible has been described as a simple autosomal dominant one (3).

Torus palatinus (TP) and *torus mandibularis* (TM) are the two most common exostosis, showing genetic and racial incidence patterns (4). As stated by most authors, TP affects approximately 30% of the population (5-7). Studies conducted by Antoniades and Seah show that TP is more prevalent in females, and TM is more common in males (1,8,9). In both genders, exostosis occur most frequently in the 35-65 year age group (1,8).

Case Report

A 40-year-old man was referred to the Department of Oral & Maxillofacial Surgery of the Dentistry School of São José dos Campos – UNESP, for removal of a palatal bone exostosis located on the left hemi arch and for further rehabilitation. The exostosis covered both anterior and posterior regions of the palatal vault and alveolar process, with little involvement of the buccal aspect. The process crossed the midline in the central area of the palatal vault. Despite the fact that the remaining teeth were caried, fractured or worn out, the periodontal tissue showed little damage. Nevertheless, in this case, the large dimensions of the lesion affected the patient's speech and feeding. Radiography and computed tomography (CT) indicated that complete removal of the process could be accomplished without fear of nasal or antral perforation and possible resultant oral-antral or oral-nasal fistulas (Figs. 1 and 2).

Due to the dimensions of the exostosis, removal was performed in two steps, both under local anesthesia. In the first surgery, we selected a supracrestal semilunar incision on the vestibular limit of the exostosis. After total detachment of the mucoperiosteal tissue, segmental

Correspondence to Dr. Rodrigo Dias Nascimento, Rua Paineiras, 340, Jd. das Indústrias, São José dos Campos, São Paulo, CEP: 12241-090 Brazil

Tel: +55-12-3933-4269

Fax: +55-12-3916-4687

E-mail: nascimentodr@yahoo.com.br

osteotomy was initiated under plentiful irrigation throughout, in order to ease the removal of bony fragments and prevent the occurrence of bucconasal communication (Fig. 3). Suturing was performed with 4.0 silk, aiming to let the wound heal by primary intention. Material collected was sent for histopathologic analysis, in which the diagnostic hypothesis of bony exostosis was confirmed.

After 30 days, the second surgery was performed for removal of the remaining exostosis and regularization of the hard palate. The same supracrestal semilunar incision, on the vestibular limit of the remaining lesion was made. Osteotomy and suture were carried out in the same way as in the first surgery (Fig. 4). The patient progressed well after both operations, with no post-operative complications.

Histopathologic Findings

Two histopathologic examinations were performed. The examined fragments from a superficial part of the lesion suggested bone exostosis due to tissue normality. These results were confirmed by the examination of a larger

fragment from a deeper layer of the lesion removed during the first operation. The examination revealed mature bone tissue organized in wide trabeculas, and sometimes in a lamellar pattern, with the formation of some haversian canals. Numerous viable osteocytes were observed inside the lacunas.

Discussion

The case described herein does not support the theory of origin and development of exostosis established by Thoma. According to this theory, the continued growth of the palatal process results in a lobular process through expansion; however, in this case the exostosis presented itself in just one large lobe (8). In the same way, the exostosis appeared and enlarged in the fourth and fifth decades of life in the present patient, contradicting the results of another study (4). Unlike some reported excisions conducted in a hospital environment under general anesthesia, the excision in this case was conducted in the university's clinic under local anesthesia (4,5). The present case also diverges from those previously reported in the decision to conduct the excision in two steps instead of

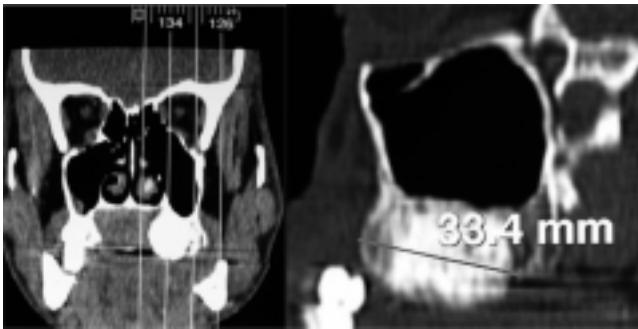


Fig. 1 Left: Coronal CT slice. Right: Sagittal CT slice.

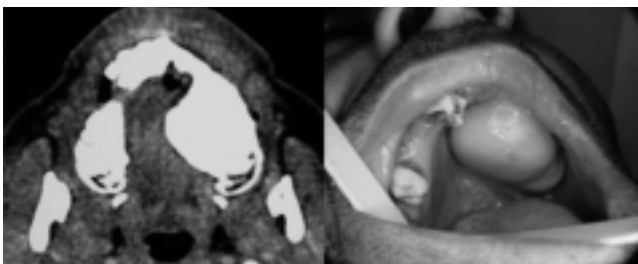


Fig. 2 Left: Axial CT slice. Right: clinical appearance.

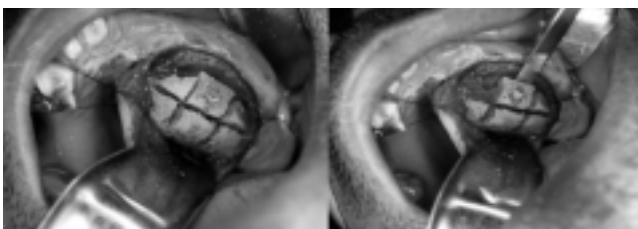


Fig. 3 First surgical procedure.

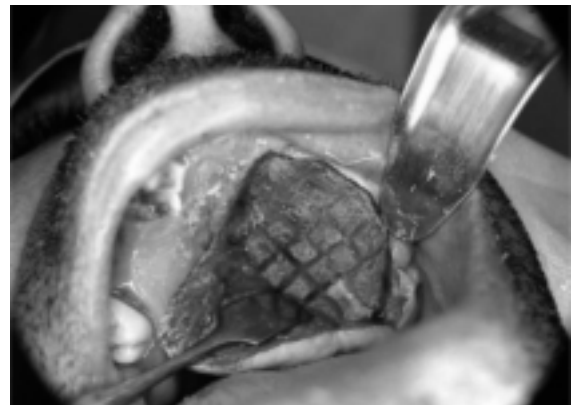


Fig. 4 Second surgical procedure.

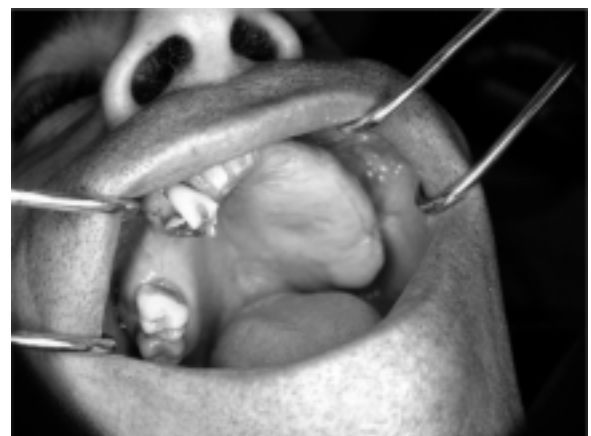


Fig. 5 Clinical appearance after six months.

one (Figs. 3 and 4) (4,5). At the end of each surgical step, a previously prepared acrylic splint filled with soft denture liner was placed in the mouth to prevent hematoma formation, as reported by Blakemore (4).

The present case study demonstrates that the complete removal of a palatal exostosis can be conducted in an ambulatory clinic under local anesthesia, when correct planning is established based on clinical examination and investigations such as CT and histopathological examination (Fig. 5). Considering the extent of the incision and the amount of bone removed, use of the acrylic splint appeared to prevent hematoma formation and collaborate to the healing process.

References

1. Antoniadis DZ, Belazi M, Papanayiotou P (1998) Concurrence of torus palatinus with palatal and buccal exostoses: case report and review of the literature. *Oral Surg Oral Med Oral Pathol Oral Radiol Endod* 85, 552-557
2. Eggen S, Natvig B (1991) Variation in torus palatinus prevalence in Norway: a statistical analysis using logistic regression. *Community Dent Oral Epidemiol* 19, 32-35
3. Gould AW (1964) An investigation of the inheritance of torus palatinus and torus mandibularis. *J Dent Res* 43, 159-167
4. Blakemore JR, Eller DJ, Tomaro AJ (1975) Maxillary exostosis. *Oral Surg Oral Med Oral Pathol* 40, 200-204
5. Topazian DS, Mullen FR (1977) Continued growth of a torus palatinus. *J Oral Surg* 35, 845-846
6. Larato DC (1972) Palatal exostosis of the posterior maxillary alveolar process. *J Periodontol* 43, 486-489
7. Nery EB, Corn H, Eisenstein IL (1977) Palatal exostosis in the molar region. *J Periodontol* 48, 663-666
8. Seah YH (1995) Torus palatinus and torus mandibularis: a review of the literature. *Aust Dent J* 40, 318-320
9. Al Quran FA, Al-Dwairi ZN (2006) Torus palatinus and torus mandibularis in edentulous patients. *J Contemp Dent Pract* 7, 112-119