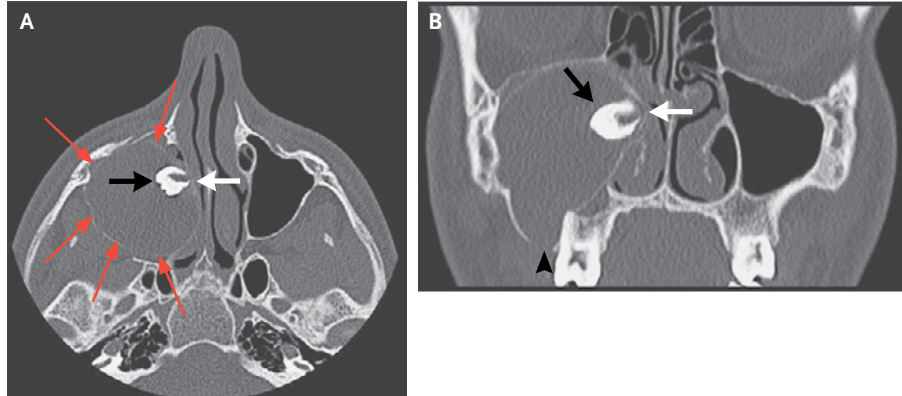


## IMAGES IN CLINICAL MEDICINE

## Ectopic Tooth in the Maxillary Sinus



Lluís Nisa, M.D.  
Roland Giger, M.D.

Hôpital de Sion  
Sion, Switzerland

A 15-YEAR-OLD BOY WAS REFERRED BY HIS DENTIST FOR EVALUATION OF recurrent episodes of maxillary and dental pain on the right side, accompanied by a purulent oral discharge. Physical examination revealed purulent material draining from a small opening in the gum next to the upper right maxillary first molar. A presumptive diagnosis of oroantral fistula was made, with probable extension to the maxillary sinus. Computed tomographic imaging revealed an ectopic tooth in the right maxillary sinus (Panel A, axial image, and Panel B, coronal image, with tooth indicated by black arrows). The ectopic tooth had obstructed the osteomeatal complex (Panels A and B, white arrows), causing the formation of a large mucocele (Panel A, red arrows) that resulted in the destruction of the bony floor of the maxillary sinus and the development of the oroantral fistula (Panel B, arrowhead). The presence of ectopic teeth in the maxillary sinus is most often asymptomatic but on rare occasions can be a cause of recurrent sinusitis. This patient's ectopic tooth was extracted from the maxillary sinus by means of endoscopic surgery, and the patient has been symptom-free for more than 8 months.

Copyright © 2011 Massachusetts Medical Society.