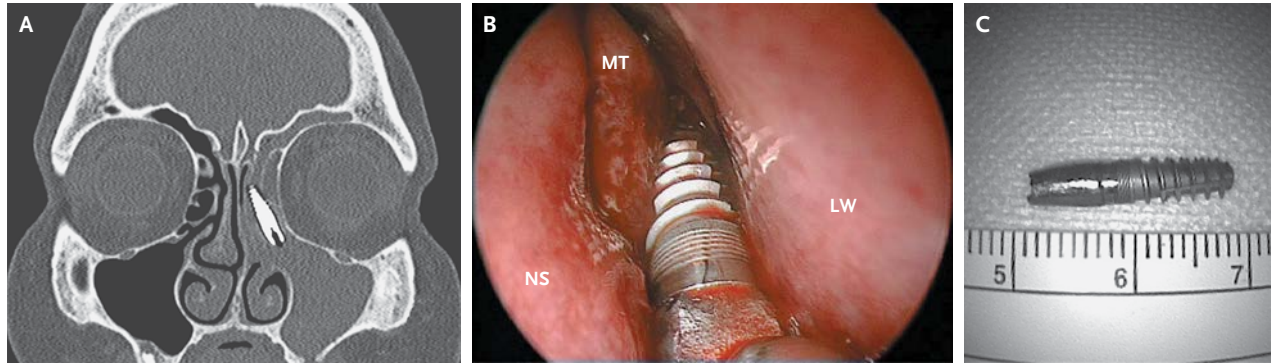


IMAGES IN CLINICAL MEDICINE

Lindsey R. Baden, M.D., *Editor*

Dental Implant in the Ethmoid Sinus



A 57-YEAR-OLD WOMAN PRESENTED WITH RECURRENT SINUSITIS OF THE left maxillary sinus. Computed tomography showed the presence of a foreign body in the left ethmoid sinus (Panel A). The patient had received an endosseous implant in the upper jaw 2 years earlier without complication. On transoral examination, the implant was unexpectedly absent; the mucosa covering the alveolar process was intact, and the remaining teeth were healthy. During endoscopic surgery, a dental implant in the ostiomeatal complex was visualized (Panel B; LW denotes lateral nasal wall, MT middle turbinate, and NS nasal septum) and extracted (Panel C; units of measurement are centimeters). The patient was discharged the day after surgery, with rapid relief of symptoms. Eight months later, she reported no residual symptoms; on nasal endoscopy, the maxillary sinusotomy was patent with normal mucosa. Displacement of dental implants into the sinus may be the result of improper positioning or the late consequence of periimplantitis and bone resorption.

Alberto Schreiber, M.D.
Davide Lombardi, M.D.

University of Brescia
Brescia, Italy
albertoschreiber@excite.it

DOI: 10.1056/NEJMicm1305466

Copyright © 2013 Massachusetts Medical Society.