

A New Surgical Management for Oro-antral Communication

The Resorbable Guided Tissue Regeneration Membrane – Bone Substitute Sandwich Technique

C Ogunsalu

ABSTRACT

This paper describes a new technique for the closure of oro-antral fistula/communication, in which both hard tissue (bone) and soft tissue closure is achieved. The sandwich technique utilizes a suitable bone grafting material sandwiched between two sheaths of Biogide® (a resorbable membrane) for the hard tissue closure of oro-antral communication post traumatic exodontia. The bone grafting material utilized for this case was Bio-oss. The result obtained was excellent with regeneration of sufficient bony tissue to allow placement of an endosseous implant. This sandwich technique is a simple and excellent technique for the closure of oro-antral communication, especially when subsequent placement of endosseous implant is considered without the need of donor site surgery for bone grafting. The otorhinolaryngologists and oral and maxillofacial surgeons should find this technique very useful in the closure of oro-antral fistulae.

INTRODUCTION

One of the clinical complications encountered by oral surgeons is oro-antral communication (OAC) with progressive formation of oro-antral fistula (OAF). The incidence of this complication may vary from 0.31% to 3.8% after simple extraction of maxillary teeth (1, 2). Buccal sliding flap, palatal flap, soft palate flap and related modifications are the various modalities available for the management of OAC or OAF (3-10). These techniques have the following shortfalls:

- Buccal sliding flap reduces the depth of the vestibular sulcus, hence need for a vestibuloplasty
- Only soft tissue closure is achieved, hence the need of complex hard tissue (bone) grafting when endosseous implant is considered
- Severe pain and scarring in palatal flaps; the palatal denuded area takes too long to heal.

Recently, Yoshimasa *et al* (11) reported the use of 3rd molar transplantation as a technique in which closure of OAC is achieved without the need for further prosthodontic treatment of the single tooth missing in the region. This proposed modality of treatment by Yoshimasa *et al* is promising and unique but has the following pitfalls:

- Extraction of the 3rd molar, which is to be transplanted, may lead to any of the known complications of 3rd molar extraction.
- OAF cannot be closed in this manner.
- Root canal treatment of the transplanted tooth is indicated, and this should be continuously monitored for failure.

Our technique using the Bio-oss-Bio-Gide Sandwich technique is particularly unique because it excludes all the above shortfalls and further has the advantage of concurrent bone tissue regeneration in the OAC/OAF site, which will enable the placement of an endosseous implant in future without the need for complex maxillary sinus lift procedure. This is the first reported case of the sandwich technique utilized for the closure of oro-antral communication (OAC) in the English Language literature.

Bio-Gide® (Fig.1) is a pure collagen membrane obtained by standardized controlled manufacturing processes. The collagen is extracted from veterinary certified pigs and carefully purified to avoid antigenic reactions. It is sterilized in double blisters by gamma irradiation, it is as such a bilayer structure. The porous surface facing the bone will allow the in-growth of bone-forming cells. The dense surface facing the soft tissue will prevent the in-growth of fibrous tissue into the bony defects. The membrane is made of type I and type III collagen without further cross-linking or chemical treatment. When used as a barrier membrane in bone cavities, it will resorb within 24 weeks. Adverse reaction to Bio-Gide has not been observed.

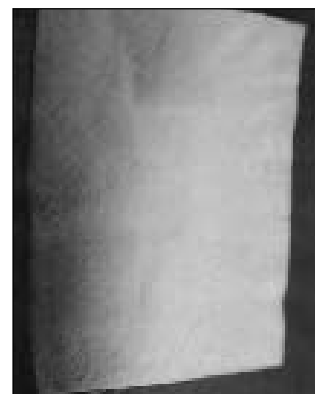


Fig. 1: Picture showing Bio-Gide

From: School of Dentistry, Faculty of Medical Sciences, The University of the West Indies, St Augustine, Trinidad and Tobago, West Indies.

Correspondence: Dr C Ogunsalu, School of Dentistry, Faculty of Medical Sciences, The University of the West Indies, St Augustine, Trinidad and Tobago, West Indies. Fax: (868) 645-3823, e-mail: chrisogun@yahoo.com

Bio-Oss® is a safe and effective bone graft material. Under the election microscope, Bio-Oss looks very similar to human bone. Because of this similarity to human bone, Bio-Oss is highly successful in helping new bone to form. It is prepared from specially processed bovine sources. Since it is highly purified bone, no allergic reaction or infection has been observed following its use.

Case Report

A 40-year-old Jamaican male was referred to the Cornwall Dental Centre by his Dentist, with a history of recently created OAC, following the extraction of the right maxillary second molar. Clinical examination and panoramic tomogram confirmed the presence of the oro-antral communication (Fig. 2).

Based on the author's previous use of Biogran-Bio-Gide Sandwich technique for the reconstruction of the maxillary sinus floor following tumour surgery (12, 13), and the excellent outcome in terms of the quality and quantity of bone regenerated (13), the sandwich technique for bone regeneration was used for the first-time in the closure of this OAC. This procedure was done on the same day of presentation and the immediate post-operative radiograph revealed adequate bone height and stabilization of the bone in the subantral region in the location of the OAC (Fig. 3).

Technique

Some cancellous granules of Bio-Oss® were sandwiched between sheaths of appropriately trimmed Bio-Gide® which were previously sutured together in three sides using 3/0 vicryl (resorbable) suture. The fourth side was then adequately closed using the same suture after the Bio-oss® had been inserted, thus creating a closed sandwich. The sandwich is prepared in such a way that it has a smooth side which is marked with "up" and a rough side (Fig. 4). A full thickness mucoperiosteal flap was raised in relation to the buccal aspect of the edentulous area of #17 extending from #16 to the mid-point of tooth #18.

The prepared sandwich was tucked into the OAC in such a way that it formed a convexity towards the sinus and a concavity towards the alveolar bone. The rough surface of the sandwich is faced to the alveolar bone and additional bio-oss is filled into this concavity. Marginal alveolectomy

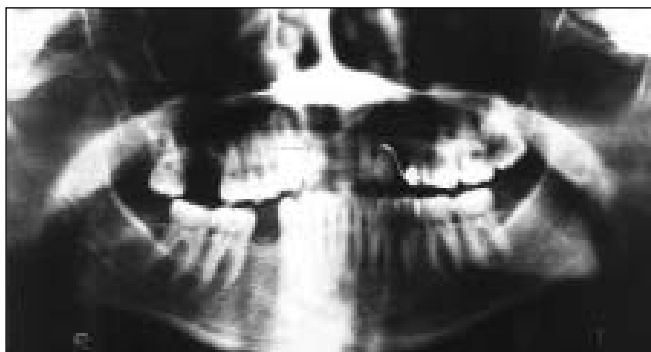


Fig. 2: DPT showing an oro-antral communication in the right maxilla

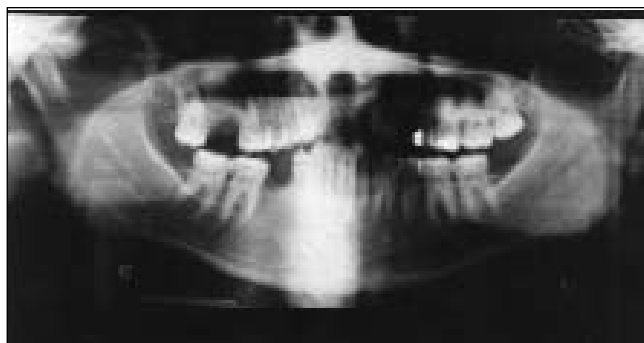


Fig. 3: DPT immediately post repair of oro-antral communication with the sandwich technique – note good quality and quantity of repair

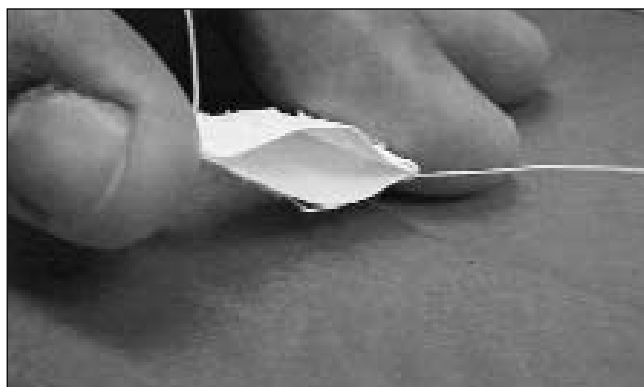

Fig. 4: Picture showing the Bio-Oss-Bio-Gide open sandwich

is performed and flaps repositioned and sutured in place whilst achieving primary closure. The suturing was made water-tight. Postoperative orthopantomogram was taken (Fig. 3) to radiologically quantify the amount of bone grafting/augmentation and closure of oro-antral fistula.

Outcome

A follow-up radiograph at eight months showed the creation of a new maxillary sinus at the bony floor and subantral bone of good quality and height that can permit the placement of an endosseous implant (Fig. 5).

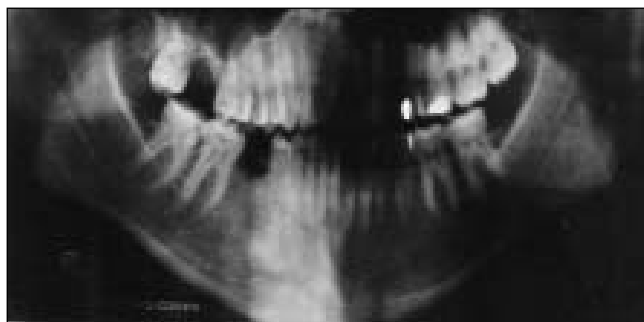

Fig. 5: DPT showing the repaired area eight months post surgery – note the maintained good quality and quantity of bone

DISCUSSION

The sandwich technique in the closure of oro-antral communication/fistula is new and promising. Ogunsalu *et al* first used this technique in 2000 in the reconstruction of the maxillary sinus floor and alveolus post excision of a bone destroying lesion without the need of bone graft donor site. In their classic papers (12, 13), the authors suggested other possible application of this technique to include reconstruction of orbital floor, closure of oro-antral fistula, frontal sinus ablation and reconstruction of table, reconstruction of bony cleft defects and mastoid ablation.

As no donor site surgery is necessary, this is an advantageous technique in terms of time saving, cost and, more importantly, less discomfort to the patient during and after surgery. Furthermore, both bony (hard tissue) and soft tissue closure is achieved for oro-antral communication in contrast to only soft tissue closure obtained by buccally sliding flap and palatal flaps. The reconstructed bony tissue regenerated from this technique will also be able to receive an endosseous implant.

In their recent publication, Khan *et al* (14) concluded that SPECT offers a simple, reproducible, objective and physiologic approach to studying the osseointegration process that occurs after placement of endosseous implant. This method can also be utilized for the measurement of osteoblastic activity index following the sandwich technique. This will enable us to predict/determine how soon endosseous implants can be placed after such technique has been utilized in regenerating bone.

The main objectives of the current clinical approaches to tissue replacement and reconstruction are to alleviate discomfort and to restore mechanical stability and function. The current modalities for treating lost tissues include the utilization of autogenous grafts, allografts, synthetic materials and xynografts. Although all these modalities of treatment have been successful, each of them has its own limitation or shortfall. One of the main problems with autogeneous graft is the fact that humans do not have a significant store of excess tissue for transplantation. Also, relating to replacement of lost bone, donor site morbidity, anatomic and structural problems and increased level of bone resorption during healing are among the problems with autogeneous bone grafting.

The sandwich technique thus offers a promising approach to replacement of lost bone without the above mentioned limitations. This technique can also be used

successfully in the closure of typical post extraction oro-antral fistula as long as the ingrowing oral tissue into the fistula is removed appropriately.

CONCLUSION

The sandwich technique in the management of oro-antral communication or fistula, in this single case, has yielded excellent results in terms of hard tissue and soft tissue closure. Furthermore, it has regenerated more than enough bone to enable placement of an endosseous implant in position #17.

REFERENCES

1. Punwutikorn J, Waikakul A, Pairuchvej V. Clinically significant Oroantral Communications – a study of incidence and site. *Int J Oral Maxillofac Surg* 1994; **23**: 19-21.
2. Hirata Y, Kino K, Nagoya S, Miyamoto R, Yoshimasu H, Amagasa T. A clinical investigation of oro-maxillary sinus perforation due to tooth extraction. *Kokubyo Gakkai Zasshi* 2001; **68**: 249-53.
3. Killey HC, Kay LW. An analysis of 250 cases of oro-antral fistula treated by the buccal flap operation. *Oral Surg Oral Med Oral Pathol* 1967; **24**: 726-39.
4. Ziembra RB. Combined buccal and reverse palatal flap for closure of oral-antral fistula. *J Oral Surg* 1972; **30**: 727-9.
5. Von Wowern N. Treatment of oro-antral fistulae. *Arch Otolaryngol* 1972; **96**: 99-104.
6. Choukas NC. Modified palatal flap technique for closure of oroantral fistulas. *J Oral Surg* 1974; **32**: 112-3.
7. Haanaes HR, Pedersen KN. Treatment of oroantral communication. *Int J Oral Surg* 1974; **3**: 124-32.
8. Ehrl PA. Oroantral communication. Epicritical study of 175 patients, with special concern to secondary operative closure. *Int J Oral Surg* 1980; **9**: 351-8.
9. Yih WY, Merrill RG, Howerton DW. Secondary closure of oroantral and oronasal fistulas: a modification of existing techniques. *J Oral Surg* 1980; **9**: 351-8.
10. Kraut RA, Smith RV. Team approach for closure of oroantral and oronasal fistule. *Atlas Oral Maxillofac Surg Clin North Am* 2000; **8**: 55-75.
11. Kitagawa Y, Sano K, Nakamura M, Ogasawara T. Use of third molar transplantation for closure of the oroantral communication after tooth extraction: A report of 2 cases. *Oral Surg Oral Med Oral Path Oral Radiol Endod* 2003; **95**: 409-15.
12. Ogunsalu C, Jadusign W, Lewis A. Sinus floor and alveolar floor reconstruction using synthetic bioactive glass (Biogran) Sandwich – an innovation in bone regeneration and pre-implant reconstructive surgery. *BJ Oral Maxillofacial Surg* 2000; **38**: 645-55.
13. Ogunsalu C, Shirly S, Lewis A, Jadusign W. Sinus floor and alveolar floor reconstruction using synthetic bioactive glass (Biogran) Sandwich – an innovation in bone regeneration and pre-implant reconstructive surgery. *Intern Mag Oral Implantol*: In Press.
14. Khan O, Archibald A, Thompson E. The role of quantitative single photo emission computerized tomography (SPECT) in the osseous integration process of dental implants. *Oral Surg Oral Med Oral Pathol* 2000; **90**: 228-32.