

Etiology of Lingual Nerve Injuries in the Third Molar Region: A Cadaver and Histologic Study

M. Anthony Pogrel, DDS, MD, FRCS,* and Hung Le, DDS†

Purpose: It has been suggested that different etiologies of lingual nerve damage in the third molar area will produce a different clinical and histologic appearance in the nerve. If the clinical and histologic pictures were different, it could result in different treatments being recommended.

Materials and Methods: Eight preserved cadavers (16 lingual nerves) were used for this study. As far as possible, the nerves were left in situ and damaged in a way that could be envisaged during third molar surgery. In each case, the damaged sections of nerve were photographed, resected, embedded in paraffin wax, sectioned in 5 μ m sections, stained with hematoxylin-eosin, and examined histologically.

Results: The scalpel clinically produced a clean wound with sharply defined edges; this was confirmed histologically with minimal disruption to the fascicles. The 702 fissure bur produced a ragged stretch-type injury clinically, and histologically this was confirmed with an irregular-edged border to the lesion and stretching and internal damage to the fascicles immediately adjacent to the wound. The crush injury clinically caused considerable apparent damage to the nerve, which was confirmed histologically with crushing and disruption of the fascicles and reduction to approximately 25% of their preinjury thickness. The stretch injury clinically showed no damage, but histologically showed irregular internal disruption of the fascicles over the whole area subject to stretching movements.

Conclusion: It does appear that different modalities in nerve injury produce a different type of injury both clinically and histologically. This information has implications for both natural clinical recovery and the indications for surgical intervention. Clinical recovery may occur best with close approximation of a sharp scalpel-type wound or excision of a crushed area of nerve with reapproximation of the nerve endings, but a ragged wound caused by a fissure bur may require excision back to healthy nerve with subsequent reapproximation, whereas with the stretching injury it may be difficult to ascertain the edges and limits of the wound, and difficult to repair, and it may be most appropriate to rely on a natural healing process for the best results.

© 2006 American Association of Oral and Maxillofacial Surgeons

J Oral Maxillofac Surg 64:1790-1794, 2006

Injuries to the lingual nerve as a result of third molar removal continue to be a problem both clinically and, to a certain extent, medicolegally. A recent study in California showed that when there is a lingual nerve injury following third molar removal the surgeon involved usually has no idea of the cause of the injury.¹

Conceptually, it can be imagined that there would be many possible causes of injury to the lingual nerve in connection with third molar removal and that they could each produce a different type of injury to the nerve and conceivably require different treatments. Among the suggested causes of lingual nerve injury in these circumstances are:

- 1) Injury could be caused by the local anesthetic injection given.²
- 2) Injury could be from the scalpel used to make the initial incision.
- 3) Injury could occur from the use of a bur during bone and tooth removal.
- 4) Injury could be caused by accidental crushing of the nerve, or excess tension from retraction.
- 5) Injury could be caused by inadvertent stretching of the nerve. This could occur during such cir-

Received from the Department of Oral and Maxillofacial Surgery, University of California, San Francisco, San Francisco, CA.

*Professor and Chairman.

†Resident.

Address correspondence and reprint requests to Dr Pogrel: Department of Oral and Maxillofacial Surgery, University of California, San Francisco, Box 0440, Room C-522, 521 Parnassus Ave, San Francisco, CA 94143-0440; e-mail: tony.pogrel@ucsf.edu

© 2006 American Association of Oral and Maxillofacial Surgeons

0278-2391/06/6412-0014\$32.00/0

doi:10.1016/j.joms.2006.05.060

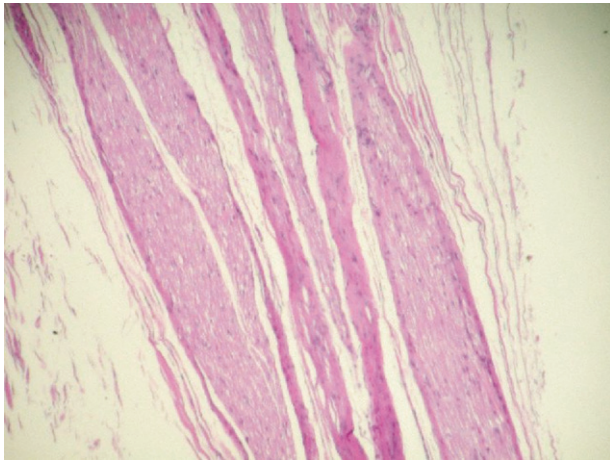


FIGURE 1. Appearance of a normal lingual nerve sectioned longitudinally showing uninterrupted fascicles of different diameters. (Hematoxylin-eosin stain; magnification $\times 20$.)

Pogrel and Le. *Lingual Nerve Injuries in Third Molar Region.* *J Oral Maxillofac Surg* 2006.

cumstances as attempting to detach adherent dental follicle from the nerve.

- 6) Injury could be caused by fracture of a sharp piece of bone from the lingual plate of the mandible.
- 7) Injury could be from other dental instrumentation (eg, a curette used to curette the dental follicle).
- 8) Injury could occur from suturing of the wound, either by direct trauma from the dental needle or compression by the suture.
- 9) Injury could occur from medicaments coming into contact with the nerve either during the primary surgery or in the treatment of any subsequent dry socket or other condition.³⁻⁵

It has been suggested that there may be differences clinically in the type of injury produced and also histologically by these different causes of nerve injury, and that if this were known it may result in different treatment protocols being proposed, depending on the type of injury. To test this hypothesis for some of the types of injuries listed above, the following study was performed.

Materials and Methods

This study was carried out using 8 preserved cadavers, giving access to 16 lingual nerves. To be as clinically realistic as possible, the nerves were not detached from the cadaver to carry out this study, but rather were damaged in situ in as realistic a fashion as possible.

The 16 nerves were damaged in the following manner:

- 1) Four were transected with a #15 scalpel blade moved from the buccal side of the mandibular ridge through the lingual soft tissues.
- 2) Four were transected with a 702 fissure bur on a Stryker surgical handpiece rotating at 50,000 rpm. The drill was moved lingually through the lingual plate of the mandible in the third molar region and through the adjacent soft tissues to include the lingual nerve.
- 3) In 4 cases the lingual nerve was identified on the lingual side of the ridge and was deliberately crushed with mosquito forceps, which were fully closed over the nerve.
- 4) Four were identified and stretched to greater than 120% of their original length. This was done by placing 2 sets of mosquito forceps from the nerve some 2 cm apart and then stretching them to increase the length of the nerve to at least 24 mm.

Following injury, the damaged sections of nerve were photographed and then dissected free from the rest of the soft tissues, rephotographed, resected with 5-mm margins, embedded in paraffin wax, sectioned in 5 μ m sections, stained with hematoxylin-eosin, and examined histologically.

Results

A normal control section of lingual nerve from one of the cadavers is shown in Figure 1, showing intact, uninterrupted fascicles of different diameters.

The lingual nerve damaged by a #15 scalpel blade produced a clean wound with sharply defined edges (Fig 2), and this was confirmed histologically with minimal disruption to the fascicles (Fig 3).

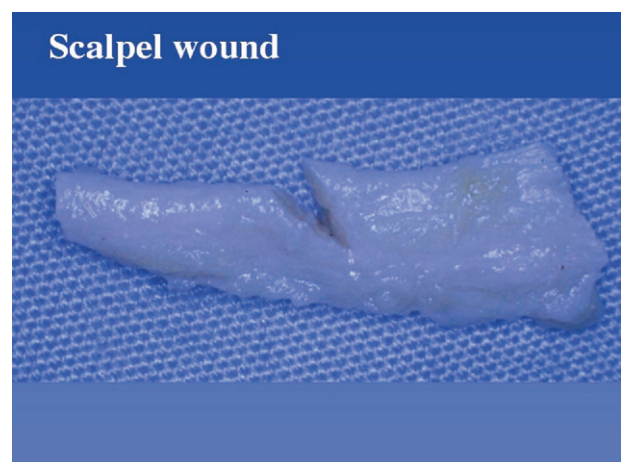


FIGURE 2. Clinical appearance of a lingual nerve damaged by a scalpel blade. Note the clean, sharp incised edges.

Pogrel and Le. *Lingual Nerve Injuries in Third Molar Region.* *J Oral Maxillofac Surg* 2006.

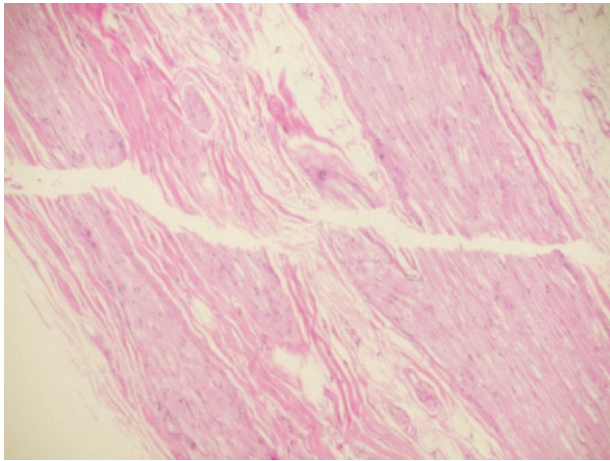


FIGURE 3. Histologic appearance of nerves seen in Figure 2 showing minimal lateral damage and good approximation of the fascicles. (Hematoxylin-eosin stain; magnification $\times 15$.)

Pogrel and Le. Lingual Nerve Injuries in Third Molar Region. J Oral Maxillofac Surg 2006.

The 702 fissure bur produced a ragged, stretch-type injury clinically (Fig 4), and histologically this was confirmed with an irregular-edged border to the lesion and stretching and internal damage to fascicles adjacent to the wound (Fig 5). However, the area of damage to the fascicles did not extend beyond 3 mm from the wound edge in any particular case.

The crushed injury clinically caused considerable apparent damage to the nerve (Fig 6), and this was confirmed histologically with crushing and disruption to the fascicles and a reduction to approximately 25% of the preinjury thickness of the nerve in conjunction with the crushed fascicles (Fig 7). However, the immediately adjacent nerve was not damaged.




FIGURE 4. Appearance of the lingual nerve transected by a 702 fissure bur. Note the ragged injury.

Pogrel and Le. Lingual Nerve Injuries in Third Molar Region. J Oral Maxillofac Surg 2006.

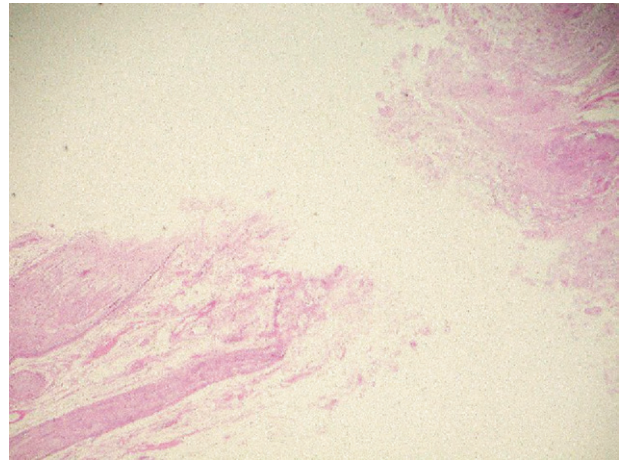


FIGURE 5. Histologic examination of nerve shown in Figure 4. Note the ragged ends with lack of fascicular pattern. The damage appears to be restricted to a 3-mm area on each side of the transection. (Hematoxylin-eosin stain; magnification $\times 15$.)

Pogrel and Le. Lingual Nerve Injuries in Third Molar Region. J Oral Maxillofac Surg 2006.

The stretch injury clinically produced no change to the nerve. Histologically, the nerve showed irregular disruption to the fascicles over the whole 2.4 cm post-stretching length of the nerve that was subjected to the stretching movement (Fig 8).

Discussion

This relatively small in vitro study suggests that different modalities of nerve injury may produce a different type of injury both clinically and histologically, and that this has implications both for natural clinical recovery and the indications for surgical intervention.

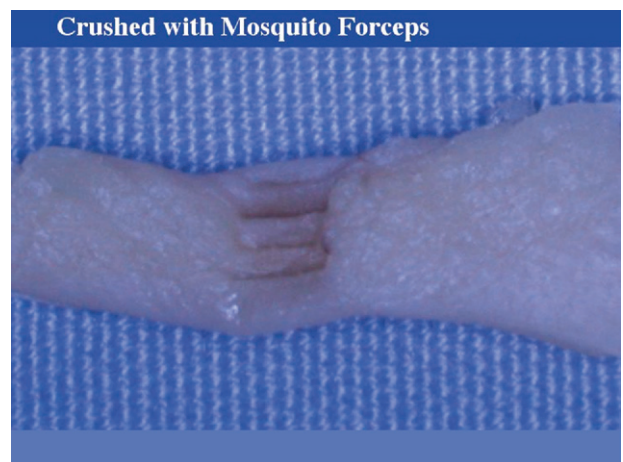

FIGURE 6. Clinical appearance of the nerve crushed by complete closure of a pair of mosquito forceps.

Pogrel and Le. Lingual Nerve Injuries in Third Molar Region. J Oral Maxillofac Surg 2006.

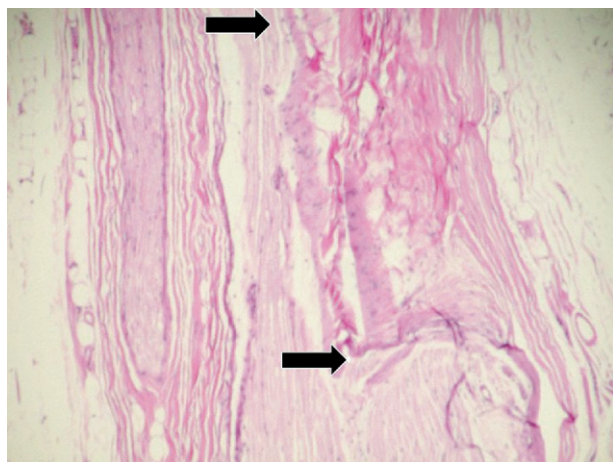


FIGURE 7. Histologic appearance of nerve seen in Figure 6. Note the clearly defined area of crushing (between the arrows), but normal appearance of the nerve on either side. (Hematoxylin-eosin stain; magnification $\times 15$.)

Pogrel and Le. Lingual Nerve Injuries in Third Molar Region. J Oral Maxillofac Surg 2006.

In the case of the scalpel-induced transection, it does appear to produce a clean wound with sharp incised edges. One would anticipate that providing the nerve ends did not retract, that natural recovery might be possible in this case, and in particular if a nerve was only partially transected by a scalpel because of the good resulting alignment of the fascicles, natural recovery might well occur. However, if there was any retraction of the nerve ends (as often occurs in lingual nerve transections) it could be anticipated that an early nerve reapproximation procedure might well offer good results. This would need to be carried out before there was time for any neuroma formation to occur.

Conversely, the 702 fissure bur produced a ragged, stretch-type injury that clinically would not be expected to recover well without surgical intervention. Surgical intervention would involve the resection of the damaged ends back to healthy nerve, and from this study, this would appear to indicate an approximately 3-mm resection on each end to produce a gap of at least 6 mm in the nerve. Most clinicians report that it is possible to mobilize the lingual nerve adequately to close a 6-mm defect without requiring any kind of interpositional graft material.⁶⁻⁸ It has sometimes been suggested that a 702-type fissure bur could in some way get hold of the nerve and wrap it around the bur, giving a much more substantial injury. We did try to reproduce this effect on the cadaver, but in no circumstance were we able to get the nerve to adhere to the bur enough that it could wrap it around itself. It is unknown whether this can happen clinically, but it appears unlikely.

The crush injury appears to be serious and conceptually would not be expected to recover spontane-

ously. However, there is virtually no lateral damage, and therefore early resection of the crushed area and reapproximation of the ends would be anticipated to give a satisfactory clinical result. Providing the resultant defect was less than apparently 8 mm, it should be possible to mobilize the nerve adequately so that no form of interpositional graft is necessary; although others have reported primary approximation of larger defects.⁹

The stretching injury, however, appears to be diffuse and occurs along the whole length that was stretched. Because this cannot be ascertained with any degree of accuracy clinically at the time of any nerve exploration, this makes surgical management of this condition difficult. At the least it would mean resection of a considerable length of nerve and the almost inevitable need for an interpositional graft^{3,6} with the resultant increase in degree of difficulty of the surgery and decrease in any success rate, plus the increased morbidity at the donor site area whether one uses nerve or vein as the interpositional graft. In these cases it may be preferable to not intervene surgically and hope for some element of natural recovery. This may well occur, because the fascicles were damaged inconsistently with stretching, and it is conceivable that some fascicles were minimally damaged while others were more profoundly damaged such that some recovery of the less damaged fascicles might be anticipated.

In conclusion, it does indeed appear that different types of nerve injury produce different clinical and histologic patterns of injury in the lingual nerve during third molar removal. However, this does not get around the clinical issue that in most cases the surgeons them-

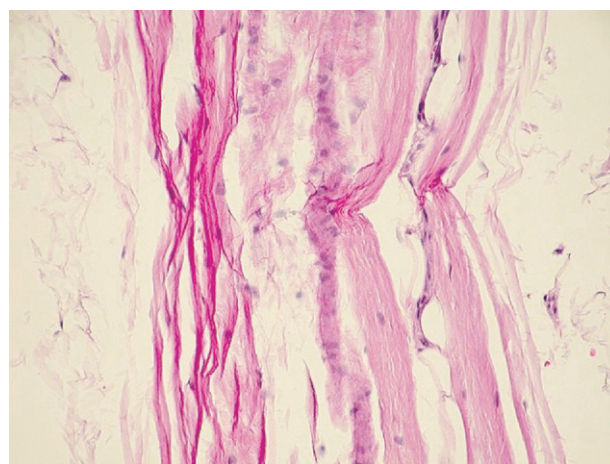


FIGURE 8. Histologic appearance of stretch injury of a nerve (clinical appearance showed no abnormalities). There is a diffuse longitudinal damage to the fascicles occurring at different levels to different degrees. (Hematoxylin-eosin stain; magnification $\times 15$.)

Pogrel and Le. Lingual Nerve Injuries in Third Molar Region. J Oral Maxillofac Surg 2006.

selves do not know what caused the injury.¹ Where the cause of the injury is known, this may influence both the timing and the type of nerve exploration and repair carried out. Even when the surgeon does not know the cause of the injury, if surgical exploration is carried out the nerve will then be examined and the appearance of the nerve at exploratory surgery may give some indication of the etiology of the injury, and therefore direct the type of nerve repair carried out.

References

1. Robert RC, Bacchetti P, Pogrel MA: Frequency of trigeminal nerve injuries following third molar removal. *J Oral Maxillofac Surg* 63:732, 2005
2. Pogrel MA, Thamby S: Permanent nerve involvement resulting from inferior alveolar nerve blocks. *J Am Dent Assoc* 131:901, 2000
3. Conrad S: Neurosensory disturbances as a result of chemical injury to the inferior alveolar nerve. *Oral Maxillofac Surg Clin N Am* 13:255, 2001
4. Loescher AR, Robinson PP: The effect of surgical medicaments on peripheral nerve function. *Br J Oral Maxillofac Surg* 36:327, 1998
5. Pogrel MA, Schmidt BL: Trigeminal nerve chemical neurotrauma from injectable materials. *Oral Maxillofac Surg Clin N Am* 13:247, 2001
6. Gregg JM, Zuniga JR: An outcome analysis of clinical trials of the surgical treatment of traumatic trigeminal sensory neuropathy. *Oral Maxillofac Surg Clin N Am* 13:377, 2001
7. Pogrel MA: The results of microneurosurgery of the inferior alveolar and lingual nerve. *J Oral Maxillofac Surg* 60:485, 2002
8. Zuniga JR, Meyer RA, Gregg JM: The accuracy of clinical neurosensory testing for nerve injury diagnosis. *J Oral Maxillofac Surg* 56:2, 1998
9. Robinson PP, Loescher AR, Smith KG: A prospective, quantitative study on the clinical outcome of lingual nerve repair. *Br J Oral Maxillofac Surg* 38:255, 2000