

Diagnostic Accuracy of Panoramic Radiography in Determining Relationship Between Inferior Alveolar Nerve and Mandibular Third Molar

Momen A. Atieh, BDS, MSc*

Purpose: The aim of this review was to determine the diagnostic accuracy of panoramic radiographic markers in the detection of the relationship between the mandibular canal and third molar roots.

Materials and Methods: A literature search of electronic databases, Cochrane Oral Health Group's Trials Register, National Research Register, conference proceedings, and abstracts was performed to identify studies that had investigated the diagnostic accuracy of the 3 panoramic radiographic markers (ie, darkening of the root, interruption of the radiopaque borders, and diversion of the mandibular canal). RevMan, version 5.0, and Meta-DiSc software programs were used for the pooled analyses and the construction of a summary receiver operating characteristic curve.

Results: A total of 5 studies were included, involving 894 observations. The overall pooled sensitivity and specificity for darkening of the root was calculated as 51.2% (95% confidence interval [CI] 42% to 60%) and 89% (95% CI 87% to 90%), respectively. The interruption of radiopaque borders showed a pooled sensitivity of 53.5% (95% CI 78.1% to 81.8%) and a pooled specificity of 80% (95% CI 78.1% to 81.8%). The diversion of the canal criterion had a pooled sensitivity of 29.4% (95% CI 21.8% to 38.1%) and a pooled specificity of 94.7% (95% CI 93.6% to 95.7%). The area under the receiver operating characteristic curve was 70% to 77%.

Conclusions: The results of this meta-analysis suggest a reasonable diagnostic accuracy for panoramic radiography in the preoperative evaluation of the relationship between third molars and the canal. Additional studies are needed to examine a more accurate, accessible, and cost-effective initial radiographic technique before third molar surgery.

© 2010 American Association of Oral and Maxillofacial Surgeons

J Oral Maxillofac Surg 68:74-82, 2010

The surgical extraction of third molars is one of the most common oral and maxillofacial surgical procedures, and several complications can occur post-operatively.^{1,2} The impairment of lower lip and chin sensation up to the midline owing to inferior alveolar nerve (IAN) injury is one of the complications related to mandibular third molar surgery. The IAN travels in the mandibular canal within the mandible in close proximity to the apices of the lower molar teeth. It mainly carries sensory fibers and supplies the mandib-

ular lower teeth, as well as the chin and lower lip. Although permanent numbness is not common, the temporary altered sensation can last for variable periods, depending on the surgical method,^{3,4} experience of the surgeon,^{5,6} and the relationship between the mandibular third molar and the IAN.^{7,8}

The incidence of transient IAN injury after removal of a lower third molar has ranged from 0.4%⁵ to 20.3%,⁹ and the reported risk of permanent IAN injury (chronic paresthesia) has been less than 1%.^{8,10-12} A preoperative evaluation of the true relationship between the roots of the mandibular third molar and the IAN would help in predicting, and possibly avoiding, sensory impairment. Therefore, radiography has been routinely used as a part of the preoperative assessment before the extraction of the lower third molar. Several investigators have described the anatomic relationship of the IAN and mandibular third molar teeth and have identified several radiologic signs (Table 1).¹³⁻¹⁹ These signs have been regarded as the

*Sir John Walsh Research Institute, University of Otago School of Dentistry, Dunedin, New Zealand.

Address correspondence and reprint requests to Dr Atieh: Sir John Walsh Research Institute, School of Dentistry, University of Otago, PO Box 647, Dunedin 9054 New Zealand; e-mail: maatieh@gmail.com

© 2010 American Association of Oral and Maxillofacial Surgeons

0278-2391/10/6801-0013\$36.00/0

doi:10.1016/j.joms.2009.04.074

Table 1. RADIOGRAPHIC MARKERS

Sign	Description
Darkening of root ^{13,15}	Increased radiolucency due to impingement of canal on molar roots
Deflected roots ^{17,18}	Abrupt deviation of molar roots to buccal or lingual or both sides of mandibular canal or around it
Narrowing of root ¹⁹	Deep grooving or perforation of molar root where canal crosses it
Dark and bifid of root apex ¹⁹	Double shadow of periodontal membrane where canal crosses apex
Interruption of radiopaque borders of mandibular canal ^{15,19}	Deep grooving or perforation of molar roots
Diversion of mandibular canal ¹⁹	Upward displacement of mandibular canal as it crosses lower third molar
Narrowing of mandibular canal ¹⁹	Reduction of diameter of canal as molar roots pass partially or completely around it

Momen A. Atieh. Diagnostic Accuracy of Panoramic Radiography. *J Oral Maxillofac Surg* 2010.

standard markers for identifying the likelihood of IAN injury. However, the accurate prediction of IAN injury remains a problematic issue owing to the lack of detailed information obtained through the use of conventional 2-dimensional methods. Other methods such as computed tomography could provide a more accurate assessment of the position of the IAN. However, it is costly and subjects the patients to greater radiation dosage.²⁰

Today, pantomography is the imaging method of choice to assess impacted lower third molars and their relationship with the IAN.⁷ Several studies have evaluated the diagnostic accuracy of the panoramic radiographic findings in identifying patients at risk of IAN injury after extraction of the lower third molars.^{7,21,22} However, the use of such a radiographic modality as a preoperative diagnostic tool has never been assessed systematically. Thus, the purpose of the present systematic study was to evaluate the diagnostic accuracy of the radiologic signs in predicting the degree of intimacy between the IAN and the mandibular third molars using conventional pantomography.

Materials and Methods

The present study was conducted in accordance with the principles of the Cochrane Collaboration and the guidelines in reporting reviews of diagnostic accuracy (the STARD Intuitive).²³

SEARCH METHOD

The following electronic databases were searched: MEDLINE (1969 to October 1, 2008); EMBASE (1980/1981 to October 2008); the Cochrane Methodology Register (to October 1, 2008); and the ISI Web of science. The search was performed without any language restriction and the following keywords were used: “inferior alveolar nerve” or “inferior dental nerve” and “injury” or “damage” and “third molar extraction” or “third molar surgery” and “panoramic radiography” or “orthopantomogram” or “pantomog-

raphy” and “sensitivity” or “specificity” or “predictive value” or “likelihood ratio.” Additionally, a comprehensive manual search of the following dental journals from 2000 to 2008 was conducted: *British Journal of Oral and Maxillofacial Surgery*, *Clinical Oral Investigations*, *Dento-Maxillo-Facial Radiology*, *European Journal of Oral Sciences*, *International Journal of Oral and Maxillofacial Surgery*, *Journal of the American Dental Association*, *Journal of Cranio-Maxillofacial Surgery*, *Journal of Dental Research*, *Journal of Oral and Maxillofacial Surgery*, and *Journal of Orofacial Pain*, *Oral Surgery Oral Medicine Oral Pathology Oral Radiology and Endodontology*. The bibliographies of all the retrieved articles, conference proceedings, and abstracts were further searched to identify other relevant studies.

STUDY SELECTION

All the studies that investigated the relationship between IAN injury and third molar surgery were included if they met the following inclusion criteria: 1) the use of panoramic radiography in the preoperative evaluation; 2) the use of at least 3 radiologic signs^{13,15,19} to describe the relationship between the IAN and lower third molars; and 3) the inclusion of the outcomes of interest or sufficient raw data to calculate the sensitivity, specificity, and diagnostic accuracy of each radiographic marker in relation to injury or exposure of IAN. The reference standard was composed of the clinical findings and follow-up during and after surgical extraction of the mandibular third molar. An intraoperative sighting of the IAN bundle indicated its close relationship to the third molars.²⁴ Thus, the exposure of the IAN at surgical extraction or the presence of paresthesia was regarded as positive reference standard results. Paresthesia was defined as any postoperative sensation of tingling, pricking, or numbness of the tissues innervated by the IAN. The reviewer was not masked to authors' identity, affiliations, or journal identification.

DATA ABSTRACTION

The following data were extracted from each study using an extraction form developed by the reviewer: 1) authors' names; 2) country of origin; 3) year of publication; 4) demographic characteristics of the participants; 5) type of impaction; 6) radiographic findings; 7) true-positive results; 8) false-positive results; 9) false-negative results; 10) true-negative results; 11) sensitivity; 12) specificity; 13) positive predictive value (PPV); and 14) negative predictive value (NPV).

QUALITY ASSESSMENT

The QUADAS tool^{25,26} was used to assess the methodologic quality of the diagnostic accuracy studies (Table 2). The scale consists of 14 items, which should be answered as "yes," "no," or "unclear." The tool does not calculate a summary quality score for each study. Incorporating an overall quality score is generally subjective, and it does not take into account the importance of each item and any potential biases.^{27,28}

STATISTICAL ANALYSIS

The analysis was conducted using RevMan software, version 5.0 (RevMan, Copenhagen, Sweden; the Nordic Cochrane Centre, the Cochrane Collaboration, 2008), and Meta-DiSc software, version 1.4 (Meta-DiSc, Clinical Biostatistics Unit, Ramón y Cajal Hospital, Madrid, Spain). For each radiographic marker, the true-positive, false-positive, false-negative, and true-negative results were calculated. The overall pooled sensitivity, specificity, PPV, NPV, positive likelihood ratio (LR+), negative likelihood ratio (LR-), and diagnostic odds ratio (DOR) for each radiographic find-

ing were either extracted or calculated using the data of the 2-by-2 contingency tables. The variation in the results across the studies was assessed visually using forest plots and statistically using Cochran's Q test. In the case of heterogeneity, *P* less than .1 was usually considered significant.

A random-effects model was used to calculate the overall pooled estimates of sensitivity, specificity, and LR with 95% confidence intervals (CIs). The LR measures the discriminating ability of a diagnostic or predictive test, with a high LR+ and lower LR- indicating good discriminating ability. The forest plot and summary receiver operating characteristic (SROC) curve were generated to graphically present the interaction between sensitivity and specificity. The overall test performance was quantified using the area under the SROC curve. The area under the curve (AUC) measures the overall capacity of the test to discriminate between participants with the disease and those without it. An AUC of 0.5 indicates poor discriminative ability; 0.75 to 0.92 is good, 0.93 to 0.97 is very good, and an area of 1.0 indicates a perfect test.²⁹ The DOR is a single summary statistic that describes the odds of positive test results in those with the disease compared with the odds of positive test results in those without the disease. The DOR is often constant, regardless of the diagnostic threshold, and ranges from 0 to infinity, with greater values indicating greater accuracy.³⁰ Meta-regression analysis can be used to investigate the potential sources of heterogeneity, such as study design, sampling method, exposure time, and other imaging characteristics. However, such an analysis was not attempted because of the small number of included studies.

Results

The initial electronic search identified a total of 940 studies (Fig 1). Of these 940 studies, 13 potentially relevant studies were selected for additional examination. After a full article review, 8 studies were excluded for the following reasons: 3 had used computed tomography findings as the reference standard,³¹⁻³³ 3 had not used the radiologic markers to study the relationship between the mandibular canal and the roots of the third molar,³⁴⁻³⁶ and 2 had insufficient data to calculate the sensitivity and specificity.^{37,38} Thus, 5 studies,^{21,22,39-41} with a total of 1,179 patients were included in the meta-analysis (Table 3). No additional studies were identified through the manual search or reference checks.

DESCRIPTIVE RESULTS

All the participants required extraction of 1 or more mandibular third molars. A total of 894 observations of the 3 standard radiographic markers^{13,15,19}

Table 2. QUADAS LIST^{25,26}

Item No.	Description
1	Representative patient spectrum
2	Clear description of selection criteria
3	Acceptable reference standard
4	Acceptable delay between tests
5	Avoiding partial verification bias
6	Avoiding differential verification bias
7	Avoiding incorporation bias
8	Sufficient description of index test
9	Sufficient description of reference test
10	Blinded interpretation of index test results
11	Blinded interpretation of reference test results
12	Availability of clinical data to the researchers
13	Reporting of uninterpretable/intermediate/indeterminate results
14	Explanation of withdrawals from study

Data from Whiting et al.^{25,26}

Momen A. Atieb. Diagnostic Accuracy of Panoramic Radiography. *J Oral Maxillofac Surg* 2010.

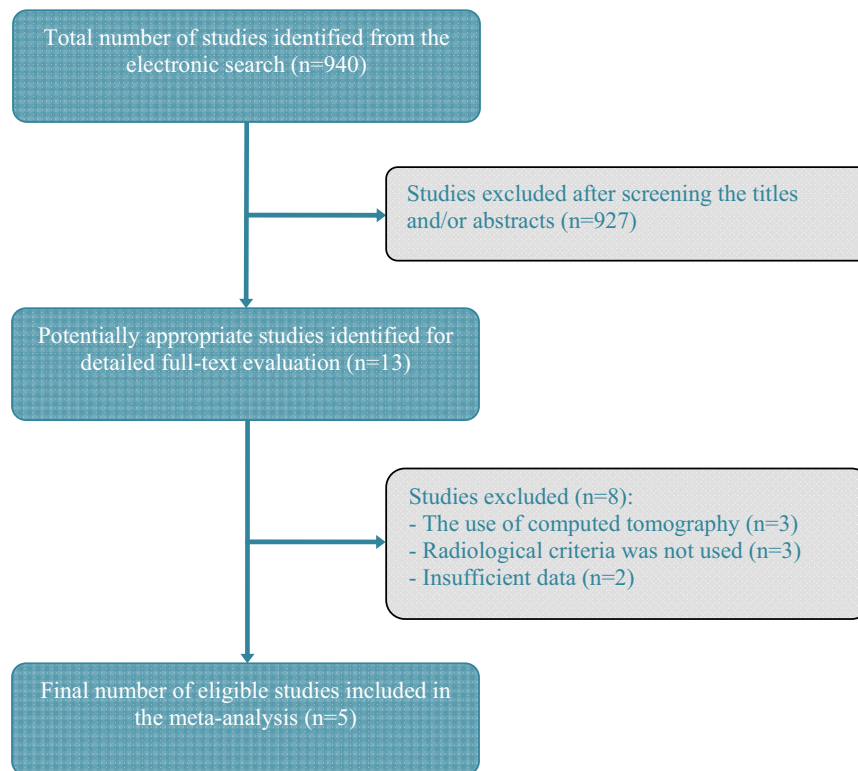


FIGURE 1. Flowchart showing review process.

Momen A. Atieh. Diagnostic Accuracy of Panoramic Radiography. J Oral Maxillofac Surg 2010.

were made in 1,793 operation sites. One study⁴¹ included both prospective and retrospective data. However, the retrospective data were excluded, because the use of panoramic radiography was not clear in all cases. Another study was prospective,³⁹ and the remaining 3 studies were retrospective.^{21,22,40} Of the 5 studies, 2 studies^{22,39} described the diagnostic accuracy according to the results of IAN exposure after mandibular third molar extraction, and 3 studies^{21,40,41} reported the presence of IAN injury as the reference standard. Because the objective of the present review was to assess the diagnostic accuracy of panoramic radiography in detecting the close relationship between the mandibular canal and lower third molars, both reference methods were accepted, and all the studies were included in the meta-analysis.

QUALITY ASSESSMENT

The methodologic quality of the included studies was assessed using the QUADAS 14-item list.^{25,26} For the first item, 2 studies^{39,41} failed to report the age groups of the patients; thus, their representative spectrum was scored as “unclear.” All the selected studies recruited patients who required extraction of the mandibular third molars, stated the place of recruitment, used an acceptable reference standard, reported IAN exposure or injury after mandibular third molar surgery without delay in all par-

ticipants, and described the use of pantomography as the index test. Thus, all the studies scored “yes” for items 2 to 8 and items 12 to 14. However, item 9 was scored as “unclear” for all the studies, because the reference standard was determined by an objective assessment and lacked the description of more subjective measures such as the use of light touch, pin prick, noxious heat, or 2-point discrimination.

With regard to blinding, only 2 studies^{21,22} scored item 10 as “yes,” because the use of blinded investigators for the assessment of the preoperative radiographic findings of the pantomography was reported. The blinded assessment of the reference test results was not clearly stated, and item 11 was scored as “no” for 2 studies^{39,40} and “unclear” for the remaining 3 studies.^{21,22,41} The quality assessment results are summarized in Table 4.

META-ANALYSIS

All the selected studies were included in the meta-analysis of the 3 predefined radiographic markers. For the diagnostic ability of the “darkening of the root” marker in identifying an intimate relationship between the third molar and the mandibular canal, the pooled sensitivity was 51.2% (95% CI 42% to 60%), and the pooled specificity was 89% (95% CI 87% to 90%; Fig 2). Thus, the pooled PPV was 23.9%, and the

Table 3. STUDY CHARACTERISTICS

Characteristic	Bell ³⁹	Blaeser et al ²¹	Gomes et al ⁴⁰	Rood and Shehab ⁴¹	Sedaghatfar et al ²²
Study design	Prospective	Retrospective	Retrospective cohort	Prospective	Retrospective cohort
Country	United Kingdom	United States	Brazil	United Kingdom	United States
Patients (n)	219	25	153	552	230
Mean age (yr)	NR	Cases 34 Controls 27	19.96	NR	24
Extracted lower third molars/radiographic observations (n)	300/135	50/250	260/75	760/157	423/277
Prevalence of IAN injury/exposure (%)	12	32	3.5	3.08	5.7
Sensitivity (%)					
Darkening of root	34	65	33	38	71
Interruption of radiopaque borders of mandibular canal	34	80	22	24	75
Diversion of mandibular canal	2.9	50	11	29	42
Specificity (%)					
Darkening of root	96	73	80	95	86
Interruption of radiopaque borders of mandibular canal	63	54	94	96	66
Diversion of mandibular canal	99.6	82	98	98	89
PPV (%)					
Darkening of root	52	31	5.6	17	24
Interruption of radiopaque borders of mandibular canal	11	25	11	14	12
Diversion of mandibular canal	50	34	20	33	19
NPV (%)					
Darkening of root	92	93	97	98	98
Interruption of radiopaque borders of mandibular canal	88	93	94	98	98
Diversion of mandibular canal	89	89	96	98	96

Abbreviations: NR, not reported; IAN, inferior alveolar nerve; PPV, positive predictive value; NPV, negative predictive value.

Momen A. Atieb. *Diagnostic Accuracy of Panoramic Radiography. J Oral Maxillofac Surg* 2010.

pooled NPV was 96.3%. Significant heterogeneity for sensitivity and specificity was observed, allowing the use of SROC. The pooled LR+ was 4.26 (95% CI 2.47 to 7.34) and the pooled LR– was 0.60 (95% CI .47 to

.78), indicating acceptable predictive ability. The summary DOR was calculated at 8.0 (95% CI 4.32 to 14.81) and the AUC at 0.77, demonstrating reasonable diagnostic performance.

Table 4. METHODOLOGIC QUALITY ASSESSMENT

Item	Bell ³⁹	Blaeser et al ²¹	Gomes et al ⁴⁰	Rood and Shehab ⁴¹	Sedaghatfar et al ²²
1. Representative patient spectrum	Unclear	Yes	Yes	Unclear	Yes
2. Clear description of selection criteria	Yes	Yes	Yes	Yes	Yes
3. Acceptable reference standard	Yes	Yes	Yes	Yes	Yes
4. Acceptable delay between tests	Yes	Yes	Yes	Yes	Yes
5. Avoiding partial verification bias	Yes	Yes	Yes	Yes	Yes
6. Avoiding differential verification bias	Yes	Yes	Yes	Yes	Yes
7. Avoiding incorporation bias	Yes	Yes	Yes	Yes	Yes
8. Sufficient description of index test	Yes	Yes	Yes	Yes	Yes
9. Sufficient description of reference test	Unclear	Unclear	Unclear	Unclear	Unclear
10. Blinded interpretation of index test results	No	Yes	No	Unclear	Yes
11. Blinded interpretation of reference test results	No	Unclear	No	Unclear	Unclear
12. Availability of clinical data	Yes	Yes	Yes	Yes	Yes
13. Reporting of uninterpretable results	Yes	Yes	Yes	Yes	Yes
14. Explanation of withdrawals from study	Yes	Yes	Yes	Yes	Yes

Momen A. Atieb. *Diagnostic Accuracy of Panoramic Radiography. J Oral Maxillofac Surg* 2010.

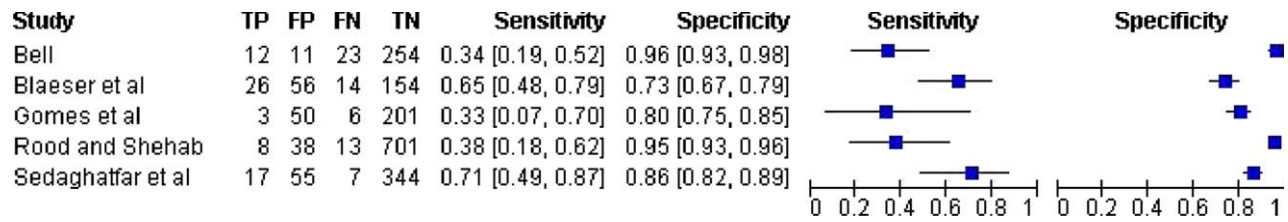


FIGURE 2. Forest plot of sensitivity and specificity for marker, darkening of third molar roots. *Solid squares* represent point estimates of sensitivity and specificity, and *black lines*, its 95% CIs. TP, true-positive; FP, false-positive; FN, false-negative; TN, true negative.

Momen A. Atieb. *Diagnostic Accuracy of Panoramic Radiography. J Oral Maxillofac Surg* 2010.

For the “interruption of the radiopaque borders of the mandibular canal,” the calculated pooled sensitivity was 53.5% (95% CI 44.5% to 62.3%), and the pooled specificity was 80% (95% CI 78.1% to 81.8%; Fig 3). The sensitivity and specificity both showed significant heterogeneity. The pooled PPV and NPV was 15.6% and 96.1%, respectively. The predictive ability was considered average, because the pooled LR+ was estimated at 2.05 (95% CI 1.33 to 3.15), and the pooled LR– was 0.69 (95% CI 0.48 to 0.99). The summary DOR for this radiographic marker was lower at 3.66 (95% CI 1.50 to 8.95), with an AUC of 0.70.

For the “diversion of the mandibular canal,” the analysis showed an overall pooled sensitivity of 29.4% (95% CI 21.8% to 38.1%) and pooled specificity of 94.7% (95% CI 93.6% to 95.7%; Fig 4), with significant heterogeneity among the included studies. Furthermore, the pooled PPV was 27.9%, and the pooled NPV was 95.1%. The predictive ability was considered good, with a pooled LR+ of 5.49 (95% CI 2.58 to 11.71) and pooled LR– of 0.77 (95% CI 0.52 to 1.14). A similar reasonable discriminative ability was demonstrated, with an estimated summary DOR of 7.73 (95% CI 3.83 to 15.61) and AUC of 0.70. The AUCs of the SROCs for the 3 radiographic markers are summarized in Figure 5.

The post-test probability was calculated using Bayes’ theorem,⁴² and the pretest probability was estimated at a mean of 11.3%, considering the prevalence of IAN injury/exposure reported in the selected studies. Thus, 35% of patients with a panoramic radiographic marker of “darkening of the roots” would

have a true close relationship between the lower third molars and the mandibular canal, and only 21% of those with an “interruption of the radiographic borders of the mandibular molars” would have a true relationship. The greatest post-test probability was calculated for the third radiographic marker, because 41.2% of patients with “diversion of the mandibular canal” would have a true intimate relationship between the lower third molars and the mandibular canal.

Discussion

The present systematic review and meta-analysis followed the guidelines of the STARD committee²³ and Cochrane Collaboration in evaluating the accuracy of the 3 panoramic radiographic criteria used by clinicians to evaluate the risk of injury to the IAN bundle. Five studies, with a total of 894 observations of the 3 chosen radiographic markers, were included in the meta-analysis to investigate the proximity of the mandibular canal to the lower third molars.

The radiographic markers were the darkening of the root or increased radiolucency, interruption of the radiopaque borders of the mandibular canal, and diversion of the mandibular canal. Those 3 signs were selected because they have been described as the most significant markers for the prediction of a close relationship between the IAN and the lower third molars.^{7,41} A high specificity (the ability to exclude an intimate relationship) and low sensitivity (the ability to identify a true intimate relationship) was demon-

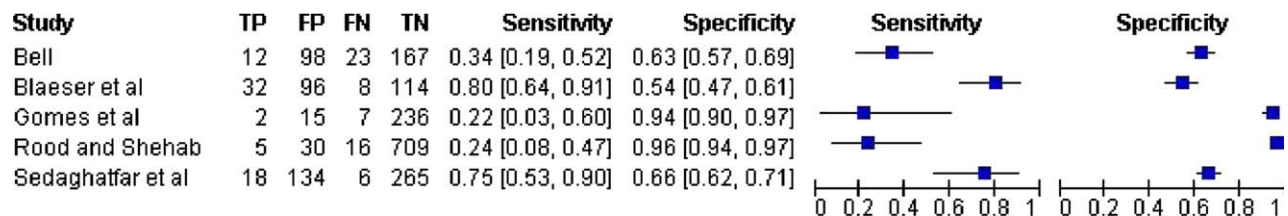


FIGURE 3. Forest plot of sensitivity and specificity for marker, interruption of radiographic borders of mandibular canal. *Solid squares* represent point estimates of sensitivity and specificity, and *black lines*, its 95% CIs. TP, true-positive; FP, false-positive; FN, false-negative; TN, true negative.

Momen A. Atieb. *Diagnostic Accuracy of Panoramic Radiography. J Oral Maxillofac Surg* 2010.

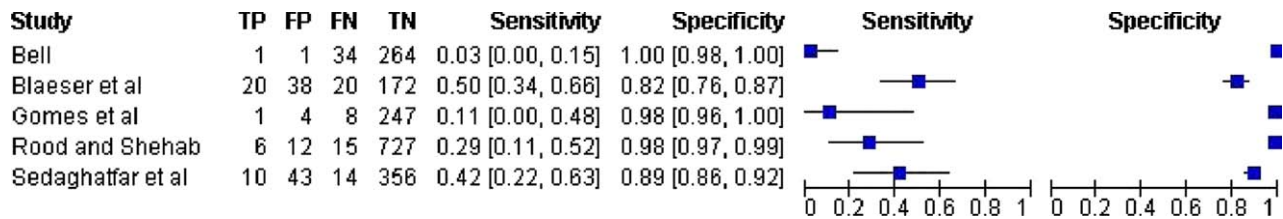


FIGURE 4. Forest plot of sensitivity and specificity for marker, diversion of mandibular canal. Solid squares represent point estimates of sensitivity and specificity, and black lines, its 95% CIs. TP, true positive; FP, false positive; FN, false negative; TN, true negative.

Momen A. Atieb. Diagnostic Accuracy of Panoramic Radiography. *J Oral Maxillofac Surg* 2010.

strated, with an area under the SROC of 70% for both the “interruption” and the “diversion” markers and 77% for the “darkening” marker. A moderate diagnostic accuracy was also demonstrated by the values of the summary DORs (8.00, 3.66, and 7.73 for the “darkening,” “interruption,” and “diversion” radiographic markers, respectively).

Panoramic radiography is therefore more reliable in excluding the close relationship between the root and the nerve in the absence of these radiographic markers than in confirming the presence of a true relationship in the presence of these radiographic findings. The low sensitivity of the radiographic markers can

be partly explained by the 2-dimensional nature of conventional radiography and the anatomic position of the mandibular canal, which is located buccally to the roots of the lower third molars in 61% of the cases, on the lingual side in 33%, and between the roots in 3%.⁴³ Thus, the presence of 1 of the radiographic markers is not necessarily an accurate indication of the intimate relationship between the roots and the canal.

The present review had several limitations. First, the analysis was performed on a small number of studies. Second, the search strategy did not identify unpublished data, which could have contributed to

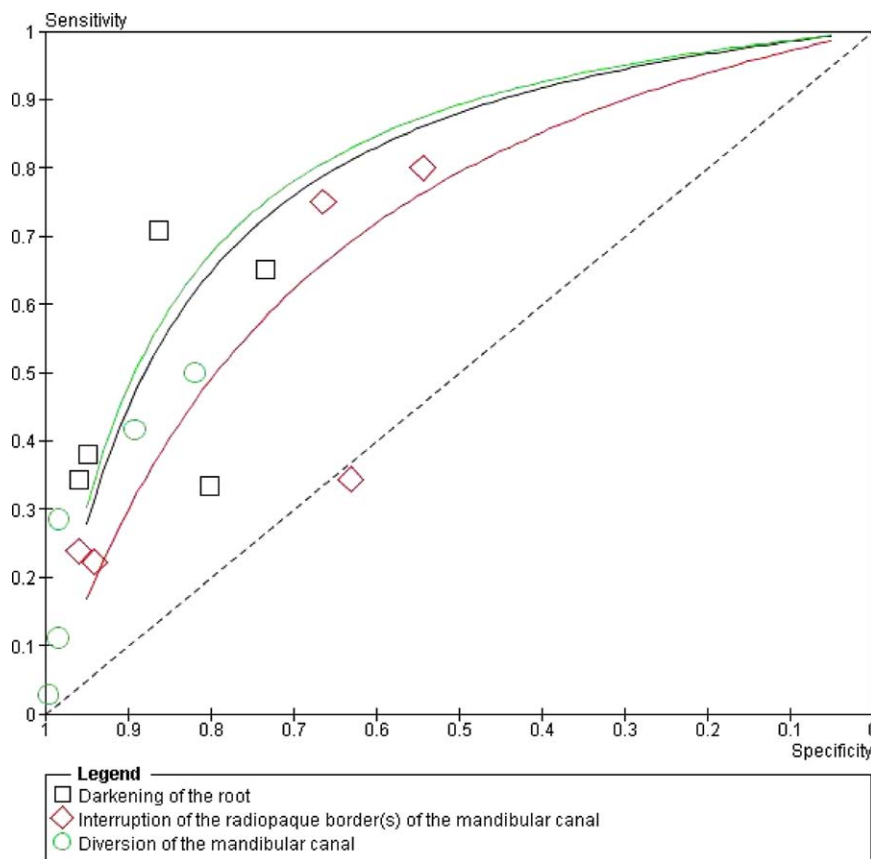


FIGURE 5. SROC curves for 3 radiographic markers. Symbols represent included studies in meta-analysis, and solid lines (SROCs) represent overall diagnostic accuracy.

Momen A. Atieb. Diagnostic Accuracy of Panoramic Radiography. *J Oral Maxillofac Surg* 2010.

the publication bias. Nevertheless most systematic reviews of diagnostic tests have failed to include unpublished data, because studies of diagnostic accuracy are not common or registered as intervention studies. Third, heterogeneity was evident among the results across the included studies, which could be attributed to the experience of the examiners, errors in exposure and positioning, and the overall quality of the radiographs. However, the present study showed moderate levels of diagnostic accuracy and a limited usefulness of the conventional radiographic markers in the preoperative assessment of the relationship between the third molars and the mandibular canal.

Despite its limitations, panoramic radiography has always been recommended as the radiographic investigation of choice in the practice of third molar surgery.^{7,44} Such an imaging technique has been proved to be relatively safe, reliable, and readily accessible. Moreover, the incidence of complications or injury to the inferior alveolar neurovascular bundle might not have been alarming enough to question the reliability of such an investigation. However, the dilemma arises when the surgeon must decide whether more detailed radiologic investigations are required. It has been suggested that the radiographic finding of 2 or more markers might improve the sensitivity in predicting a true intimate relationship and hence an indication for applying other imaging techniques such as computed tomography to confirm the diagnosis and provide the surgeon with additional detailed information about the anatomy of the mandibular canal and third molar roots.³² However, such imaging techniques might still be less popular among clinicians and patients owing to the cost and dose-related factors.

A true close relationship between the third molars and the mandibular canal increases the risk of IAN injury, and an accurate evaluation of the relationship is essential to avoid the risk of surgery. Surgeons, however, should be aware of the limitations of the radiographic markers of panoramic radiography and should consider more detailed imaging in specific cases in which more than 1 radiographic marker is present. Additional studies are needed to examine other predictive markers and investigate a cost-effective, safe, and accessible radiographic technique for the preoperative assessment of the relationship between the third molar roots and mandibular canal.

References

- Mercier P, Precious D: Risks and benefits of removal of impacted third molars: A critical review of the literature. *Int J Oral Maxillofac Surg* 21:17, 1992
- Daley TD: Third molar prophylactic extraction: A review and analysis of the literature. *Gen Dent* 44:310, 1996
- Rood JP: Permanent damage to inferior alveolar and lingual nerves during the removal of impacted mandibular third molars: Comparison of two methods of bone removal. *Br Dent J* 172:108, 1992
- Rud J: Reevaluation of the lingual split-bone technique for removal of impacted mandibular third molars. *J Oral Maxillofac Surg* 42:114, 1984
- Sisk AI, Hammer WB, Shelton DW, et al: Complications following removal of impacted third molars: The role of the experience of the surgeon. *J Oral Maxillofac Surg* 44:855, 1986
- Bataineh AB: Sensory nerve impairment following mandibular third molar surgery. *J Oral Maxillofac Surg* 59:1012, 2001
- Bouloux GF, Steed MB, Perciaccante VJ: Complications of third molar surgery. *Oral Maxillofac Surg Clin North Am* 19:117, 2007
- Wofford DT, Miller RI: Prospective study of dysesthesia following odontectomy of impacted mandibular third molars. *J Oral Maxillofac Surg* 45:15, 1987
- Brann CR, Brickley MR, Shepherd JP: Factors influencing nerve damage during lower third molar surgery. *Br Dent J* 186:514, 1999
- van Gool AV, Ten Bosch JJ, Boering G: Clinical consequences of complaints and complications after removal of the mandibular third molar. *Int J Oral Surg* 6:29, 1977
- Alling CC III: Dysesthesia of the lingual and inferior alveolar nerves following third molar surgery. *J Oral Maxillofac Surg* 44:454, 1986
- Carmichael FA, McGowan DA: Incidence of nerve damage following third molar removal: A West Scotland oral surgery research group study. *Br J Oral Surg* 30:78, 1992
- Main J: Further roentgenographic study of mandibular third molars. *J Am Dent Assoc* 25:1993, 1938
- Austin LT: Perforation of roots of impacted lower third molars by contents of mandibular canal: Report of a case. *Am J Orthod Oral Surg* 33:623, 1947
- Howe GL, Poyton HG: Prevention of damage to the inferior dental nerve during the extraction of mandibular third molars. *Br Dent J* 109:355, 1960
- Merrill RG: Prevention, treatment and prognosis for nerve injury related to the difficult impaction. *Dent Clin North Am* 23:471, 1979
- Stockdale CR: The relationship of the roots of mandibular third molars to the inferior dental canal. *Oral Surg Oral Med Oral Pathol* 12:1061, 1959
- Waggenger DT: Relationships of third molar roots to the mandibular canal. *Oral Surg Oral Med Oral Pathol* 12:853, 1959
- Seward GR: Radiology in general dental practice. VIII. Assessment of lower third molars. *Br Dent J* 115:45, 1963
- Ngan DC, Kharbanda OP, Geenty JP, et al: Comparison of radiation levels from computed tomography and conventional dental radiographs. *Aust Orthod J* 19:67, 2003
- Blaeser B, August MA, Kaban LB, et al: Radiographic risk factors for inferior alveolar nerve injury during third molar extraction. *J Oral Maxillofac Surg* 61:417, 2003
- Sedaghatfar M, August MA, Dodson TB: Panoramic radiographic findings as predictors of inferior alveolar nerve exposure following third molar extraction. *J Oral Maxillofac Surg* 63:3, 2005
- Bossuyt PM, Reitsma JB, Bruns DE, et al: Towards complete and accurate reporting of studies of diagnostic accuracy: The STARD intuitive. *Radiology* 226:24, 2003
- Tay AB, Go WS: Effect of exposed inferior alveolar neurovascular bundle during surgical removal of impacted lower third molars. *J Oral Maxillofac Surg* 62:592, 2004
- Whiting P, Rutjes AW, Reitsma JB, et al: The development of QUADAS: A tool for the quality assessment of studies of diagnostic accuracy included in systematic review. *BMC Med Res Methodol* 3:25, 2003
- Whiting P, Weswood ME, Rutjes AW, et al: Evaluation of QUADAS, a tool for the quality assessment of diagnostic accuracy studies. *BMC Med Res Methodol* 6:9, 2006
- Juni P, Witschi A, Bloch RM, et al: The hazards of scoring the quality of clinical trials for meta-analysis. *J Am Med Assoc* 282:1054, 1999

28. Whiting P, Harbord R, Kleijnen J: No role for quality scores in systematic reviews of diagnostic accuracy studies. *BMC Med Res Methodol* 5:19, 2005
29. Deeks JJ: Systematic reviews of evaluation of diagnostic and screening tests, *in* Egger M, Smith GD, Altman DG (eds): *Systematic Reviews in Health Care: Meta-Analysis in Context* (ed 2). London, BMJ Publishing, 2001, pp 248-282
30. Glas AS, Lijmer JG, Prins MH, et al: The diagnostic odds ratio: A single indicator of test performance. *J Clin Epidemiol* 56: 1129, 2003
31. Better H, Abramovitz I, Shlomi B, et al: The presurgical workup before third molar surgery: How much is enough? *J Oral Maxillofac Surg* 62:689, 2004
32. Monaco G, Montecchi M, Alessandri B, et al: Reliability of panoramic radiography in evaluating the topographic relationship between the mandibular canal and impacted third molars. *J Am Dent Assoc* 135:312, 2004
33. Nakamori K, Fujiwara K, Miyazaki A, et al: Clinical assessment of the relationship between the third molar and the inferior alveolar canal using panoramic images and computed tomography. *J Oral Maxillofac Surg* 66:2308, 2008
34. Susarla SM, Dodson TB: Estimating third molar extraction difficulty: A comparison of subjective and objective factors. *J Oral Maxillofac Surg* 63:427, 2005
35. Gülicher D, Gerlach KL: Sensory impairment of the lingual and inferior alveolar nerves following removal of impacted mandibular third molars. *Int J Oral Maxillofac Surg* 30:306, 2001
36. Bell GW, Rodgers JM, Grime RJ, et al: The accuracy of dental panoramic tomographs in determining the root morphology of mandibular third molar teeth before surgery. *Oral Surg Oral Med Oral Pathol Oral Radiol Endod* 95:119, 2003
37. Valmaseda-Castellón E, Berini-Aytés L, Gay-Escoda C: Inferior alveolar nerve damage after lower third molar surgical extraction: A prospective study of 1117 surgical extractions. *Oral Surg Oral Med Oral Pathol Oral Radiol Endod* 92:377, 2001
38. Jerjes W, El-Maaytah M, Swinson B, et al: Inferior alveolar nerve injury and surgical difficulty prediction in third molar surgery: The role of dental panoramic tomography. *J Clin Dent* 17:122, 2006
39. Bell GW: Use of dental panoramic tomographs to predict the relation between mandibular third molar teeth and the inferior alveolar nerve: Radiological and surgical findings, and clinical outcome. *Br J Oral Maxillofac Surg* 42:21, 2004
40. Gomes AC, Vasconcelos BC, Silva ED, et al: Sensitivity and specificity of pantomography to predict inferior alveolar nerve damage during extraction of impacted lower third molars. *J Oral Maxillofac Surg* 66:256, 2008
41. Rood JP, Shehab BA: The radiological prediction of inferior alveolar nerve injury during third molar surgery. *Br J Oral Maxillofac Surg* 28:20, 1990
42. Deeks JJ, Altman DG: Diagnostic tests 4: Likelihood ratios. *BMJ* 329:168, 2004
43. Tammissalo T, Happonen RP, Tammissalo EH: Stereographic assessment of mandibular canal in relation to the roots of impacted lower third molar using multiprojection narrow beam radiography. *Int J Oral Maxillofac Surg* 21:8, 1992
44. The Faculty of General Dental Practitioners, the Royal College of Surgeons of England: Selection Criteria for Dental Radiography. London, Royal College of Surgeons of England, 1998, p 20