

Dental emergencies

The management of dental emergencies in the hospital environment has evolved dramatically over the last 20 years. While once providing management limited to odontogenic problems on a consultation basis only, general and pediatric dentists, as well as oral and maxillofacial surgeons, are now often the primary providers of care and might manage everything from a simple toothache to the most severe maxillofacial and craniofacial injuries. This natural evolution has brought with it many opportunities for both practitioners and residents alike. It also carries with it a new level of responsibility, for now the dentist must be aware not only of the odontogenic emergency but also of all the local and systemic consequences of the patient's current emergency condition, as well as overall medical status.

Emergency department (ED) [A&E] organization varies from hospital to hospital. Smaller hospitals often have a single emergency facility staffed by members of the medical staff on a rotating basis, or by specialists in emergency medicine. Larger academic medical centers often have emergency medicine house officers as the primary staffing, with support by the emergency medicine faculty. These medical centers also commonly have several combined or distinct areas for the specific management of medical, surgical, pediatric, obstetric/gynecologic and non-emergency problems.

Non-critical emergency patients are usually first seen by a secretary or nurse, who obtains demographic data and starts a medical chart [notes]. When necessary, old medical records are requested to facilitate obtaining an accurate medical history. A nurse will then triage the patient. This involves an assessment of the problem, establishment of a priority for care and assignment of the patient to an appropriate member of the medical/dental staff. The initial assignment of the patient varies by hospital. In some institutions, patients with isolated dental/oral or maxillofacial problems may be

directly referred to and managed by a dentist. In other facilities, patients are first seen by the emergency physician who, after performing an examination and managing any medical conditions, consults a dentist about treating any oral/facial problem(s). A thorough knowledge of the organizational, triage and treatment protocols in the emergency department will greatly enhance the dentist's ability to provide rapid, appropriate and broadly scoped emergency care.

MEDICOLEGAL ASPECTS OF EMERGENCY CARE

As the provision of emergency care is inherently acute and impersonal in nature, the medicolegal aspects of care are of great importance.

Responsibilities of the doctor

Appointment to a hospital staff obligates an attending or house-staff member to treat patients with emergency needs. Depending on the facility, emergency department care may be provided by dentists on a rotating basis or on an 'as needed' basis by specific consultation. Either way, emergency care should be provided in a timely fashion, both for the patient and for the efficient running of the emergency department [A&E].

Consent

As with any hospital procedure, a signed informed consent for treatment is a prerequisite for emergency treatment. In conscious children or adult patients this is not usually a problem. However, children and adults who are unable to give consent because of unconsciousness, intellectual incapacity, neurological disease (e.g. prior stroke or Alzheimer's disease) or emotional/psychiatric instability must be dealt with by alternative means. In the case of children, a parent or legal guardian can give consent. If an adult patient is unable to give consent, an immediate family member can do so for emergency procedures. When no parent or family member can be contacted, telephone consents are usually acceptable if witnessed by at least one other uninvolved healthcare provider.

Emergency consent

If unable to obtain patient, guardian or family consent, emergency care can be rendered only if:

- the care is necessary to prevent loss of life or limb, or severe disability *and*
- the above is documented by the dentist and at least one other doctor.

Non-emergency care should be deferred. As a last resort, the doctor or a hospital administrator can obtain emergency judicial consent by court order. One should become familiar with individual state and national laws and hospital rules concerning such situations.

Follow-up

It is incumbent on the doctor who renders emergency services to provide patients with information on the need and accessibility for follow-up care. Preferably, this information should be in written form and documented in the medical record.

Outpatient versus inpatient care

Generally speaking, most dental emergencies can be treated in an outpatient environment. However, oral and maxillofacial surgeons, in particular, are commonly faced with situations where admission of the patient is warranted.

General indications for admission to the hospital

- Patients with severe, traumatic injuries requiring skilled nursing care, such as a concurrent head injury.
- Patients who require parenteral antibiotics or analgesics.
- Patients who require parenteral hydration or feeding.
- Patients who require emergency surgery.
- Patients unable to care for themselves under the current circumstances, including children whose parents are deemed a risk.
- Patients with the need for airway management.

EMERGENCY DEPARTMENT MEDICAL RECORDS

Documentation

Nowhere is the mandate for accurate and complete documentation more important than in emergency care:

- Many of these patients will be seen for definitive follow-up care by non-dentists.
- Dental treatment and terminology is often poorly understood by physicians and nurses (hence the need to write 'bleeding in maxillary right first molar region' and not 'bleeding from #3').
- Some emergency department cases can eventually involve legal proceedings or litigation. Therefore, the maintenance of objective, accurate detailed records is paramount to the ability to recollect prior events.

Medical records

The medical records used for emergency care are similar to those used elsewhere in the hospital (e.g. the history and physical examination and the progress notes). These notes are presented in detail in Chapters 2 and 4 but some modifications specific to emergency records are outlined below.

Consultation note

This note is for a patient under the care of another provider who requests a dental opinion regarding a specific problem. Primary care responsibilities remain with the requesting provider and all orders should be confirmed with that provider prior to institution, unless responsibility has been transferred to the dentist. A consult note should be thorough yet concise and include the following information:

- History of present illness (HPI): a detailed history of the current dental problem relating to the consult request. If other conditions exist that brought the patient to the ED [A&E] and are being treated by the primary provider (e.g. long bone injuries accompanying a mandible fracture from a motor vehicle accident), these too should be briefly described.
- Past medical history (PMH): a listing of the pertinent positive and negative findings from the patient's past and current medical

history. Any positive review of systems findings are generally included in this section for consultation notes. All positive findings should include a brief discussion describing the current status of the medical condition.

- **Current medications:** a list of the patient's medications with the route of administration, dose and interval schedule. If unclear, a family member, the pharmacist or the doctor who wrote the prescription(s) should be contacted.
- **Allergies:** a list of the patient's known drug allergies and the particular response seen from previous administration (e.g. hives, itching, gastrointestinal upset).

Physical examination (PE)

This section should include an appropriate head and neck examination and a thorough oral examination. In addition, any other examination pertinent to the consultation request should also be performed (e.g. a neurologic examination for a patient with facial injuries). Examination results should be detailed, especially in the specific area mentioned for examination in the consult request.

Radiographic and laboratory examination

Necessary radiographs and/or laboratory tests should be obtained and interpreted. Many radiographs (e.g. periapicals, panoramic) are interpreted by the dental consultant, not by a radiologist or the primary provider and should, therefore, be read comprehensively, not just for the specific complaint. All pertinent laboratory data (e.g. CBC, platelet count, PT/INR, PTT) should be listed and interpreted as well.

Assessment

This is a line-by-line listing of all the positive findings, followed by a brief discussion of its current status and its effect on the patient's care.

Recommendations and treatment

These are recommendations regarding diagnosis and appropriate treatment based on the assessment. Recommendations should be thorough and specific, indicating particular therapies, drugs and dosages. No treatment should be performed without the consent of the primary provider. If any treatment is performed, it should be clearly noted in this section, along with any anesthesia used.

Disposition or discharge information

This is a listing of instructions given to the patient, medications prescribed (with primary provider's permission), follow-up appointments or other plans.

Primary care notes

In some circumstances, the dentist might be the only doctor to see the patient. In these cases, it is even more imperative to consider the patient's overall medical condition and not just the head and neck region. For example, patients with facial injuries might have concomitant cervical or intracranial injuries that often cannot be appreciated by the triage staff. Another example would be oral bleeding. Although there are many local reasons for oral bleeding, the dentist is obliged to consider systemic sources or coagulopathies and order the appropriate tests to make the correct diagnosis, and then obtain appropriate medical consultation. It is important to write complete notes that more closely approximate an admission note. Orofacial trauma might be a result of syncope in the elderly (a common but significant and diagnostically complex syndrome with potential cardiovascular, neurologic, endocrinologic, visual, vestibular and neuromotor implications), or abuse in a child or a dependent older individual. These situations dictate a medical and/or social services consult if abuse is suspected.

Primary care notes differ from consult notes as follows:

- HPI: the history must be comprehensive and include all information relating to the present condition, not just those affecting the head and neck. Traumatic dental or facial injuries, for example, should be detailed as to the time, mechanism and severity of the injury as well as previous traumatic episodes. Specific questions should be directed at ascertaining the likelihood of other systemic injuries (e.g. chest, abdominal, cervical or intracranial).
- The physical examination, while certainly emphasizing the head and neck findings, should nevertheless include a basic examination of any other bodily system that is pertinent to the HPI. Positive findings should indicate the need for appropriate medical consultation.
- Radiology/Labs: appropriate films (e.g. C-spine) and lab data should be obtained (when indicated by the history or PE) to rule out

concomitant injuries and/or possible systemic factors, as well as to diagnose the acute dental or facial injuries.

- Assessment/Plan (A/P): this should reflect the patient's overall condition including the oral findings and any others. When non-dental items are listed, specific medical consultation should be ordered and noted in the medical record.
- Admission notes: these should consist of the primary care note and the following:
 - Indication for admission.
 - Name of the attending dentist.
 - Principal diagnosis.
 - Place to be admitted.
 - Condition of the patient.
 - Immediate treatment plan.

Consultation request notes

Written consultation requests to another service or doctor should be instituted whenever the dentist feels that it is necessary for the comprehensive and appropriate care of the patient. The best practitioners are the ones who know when to ask for assistance in the best interest of the patient. When in doubt, obtain a consult. A consult request should include the following:

- A brief summary of the HPI and treatment to date.
- Any pertinent medical history, physical findings and radiographic or laboratory data.
- A detailed and specific explanation of why the consult is being ordered and what information is desired from the consultant. If any necessary treatment by the consultant is desired, this should also be indicated in the note.
- Direct verbal communication between dentist and consulted physician is encouraged whenever possible.

Follow-up notes

Follow-up notes can be written in the 'SOAP' format as follows:

- Subjective: this includes the patient's chief complaint if there is one, or any comments the patient has regarding the condition, past treatment and so on.
- Objective: this includes the physical examination and the radiographic and laboratory data, if ordered.
- Assessment: a summary of the patient's condition.
- Plan: the consideration for the future management of the patient and any appointments scheduled.

INTRAORAL URGENCIES

Odontogenic pain

General principles

Pain of odontogenic origin is the most common dental emergency seen in the ED [A&E]. Although the etiology and management are usually straightforward, other more serious conditions can present with a similar clinical presentation. Misdiagnosis can have serious ramifications and it is incumbent upon the practitioner to perform a complete diagnostic workup that includes the following:

- **History:** the history of pain should include duration, location, description (character and intensity on a scale of 1–10) and what exacerbates and relieves the pain. Note the medications taken, dose and duration and how effective or ineffective they have proved to be. Watch for acetaminophen [paracetamol] toxicity in children. Any previous treatment or similar history should be noted.
- **Physical examination:** the patient should be examined for any tooth that is sensitive to percussion, pressure on biting/mastication and palpation, as well as for mobility, periodontal pocketing, adjacent soft tissue swelling, caries, fractures, integrity of existing restorations and pulp vitality.
- **Radiographic and laboratory examination:** intraoral and/or panoramic radiographs should be obtained and examined for caries, periodontal disease and periapical changes, fractures or other pathology. Occlusal views may be useful for children. A Water's view might be necessary to examine for sinus disease. Laboratory values such as a CBC and cultures are often useful when infection exists or is suspected.

Management of specific intraoral urgencies

Hypersensitivity of dentin or cementum

- **History:** positive for localized sensitivity to cold, sweets, acids, tooth brushing, fingernail or metal instrument.
- **Examination:** usually demonstrates localized areas of exposed cementum or dentin, with or without overlying plaque.

- Tests: may be sensitive to air blast or metal instrument (explorer) at gingival level of tooth surface. Hyper- or traumatic occlusion should be ruled out.
- Treatment: use of fluoride gel or commercial dentin desensitizers following thorough cleaning can help to desensitize.
- Prognosis: symptoms should decrease within days and eventually disappear. The area must be kept clean. Restoration might be required.

Pulpal hyperemia

- History: transient thermal or biting sensitivity. History of recent restorative treatment, upper respiratory infection or flu (with sinus involvement) in the past 6–8 weeks.
- Examination: examine patient for faulty restoration, caries, hyper- or traumatic occlusion or enamel or tooth fracture ('cracked tooth' syndrome).
- Tests: may be sensitive to air blast or cold. Electric pulp test (EPT) positive at low level or normal.
- Prognosis: usually reversible with appropriate treatment.
- Treatment: if possible, the source (e.g. high restoration) should be removed. If indicated, a sedative restoration can be useful. If due to deep caries, an indirect pulp cap should be used only in permanent teeth and when pulp pathology is believed to be reversible (e.g. no periapical pathology, no lingering spontaneous pain that might be worse overnight and stimulated pain of short duration only).

Acute pulpitis (early)

- History: spontaneous, intermittent, sharp, spasmodic pain and cold sensitivity. Pain of longer duration than simple hyperemia but not continuous. Sensitivity to hot and/or cold foods/drinks (e.g. coffee/tea and/or ice cream).
- Examination: usually reveals identifiable source of pulpitis (e.g. caries, deep restoration, fractured restoration or clinical crown). Radiograph might not demonstrate periapical radiolucency.
- Tests: positive electric pulp test at low level. Heat and/or cold may excite. Tooth may be percussion sensitive.
- Prognosis: probably not reversible.
- Treatment: if reversible pulpitis and if all infected caries is removed without exposure, use sedative filling. If carious exposure then:

- permanent tooth (open apex): calcium hydroxide pulpotomy
- permanent tooth (closed apex): pulpectomy
- primary tooth: formocresal pulpectomy or pulpectomy, depending on the stage of root resorption
- extraction as an alternative.

Note: A given tooth might have overlapping symptoms from more than one cause, for example, a molar with pulpal hyperemia in a distal canal and necrotic mesial canals (from mesial caries) might give misleading electric pulp test (EPT) results and the history might suggest symptoms of both a reversible and irreversible situation.

Acute suppurative pulpitis (later stage)

- History: spontaneous, intense, sharp pain lasting longer periods of time. Heat sensitive, cold may soothe.
- Examination: look for a source of pulpitis (e.g. caries, fractured tooth or restoration), which might have referred pain and/or may be of periodontal origin. A radiograph will usually show widening of the periodontal ligament at the apex, or periapical lucency. Regional – particularly submandibular – tender lymphadenopathy on palpation.
- Tests: electric pulp test unreliable. Usually percussion and/or heat sensitive.
- Prognosis: irreversible.
- Treatment: extraction or root canal therapy.

Non-vital pulp with periapical inflammation

- History: chronic, unstimulated pain; sensitive to biting. May report a recent history of cold sensitivity with a tooth. Percussion sensitivity. Pain may be referred. In severe cases, patient may be sipping cold water to relieve pain.
- Examination: identify source of pulpal pathology. Regional particularly submandibular, tender lymphadenopathy on palpation.
- Tests: no response to heat, cold or electric pulp test. Positive percussion sensitivity.
- Treatment: pulpectomy and eventual root canal therapy or extraction. With regional or systemic involvement, antibiotics may be indicated (e.g. penicillin VK 500 mg QID, amoxil [amoxicillin] 500 mg tds, or for penicillin-allergic patients, clindamycin 250–300 mg QID).

Acute periapical disease (alveolar abscess)

- History: exquisite, localized pain, throbbing. May have history of facial swelling and/or fever.
- Examination: identifiable source of pulpal disease is almost always found. May be tender on direct finger palpation of the vestibule or may see swelling in the vestibule (that can be fluctuant and painful), inflammation and possibly fever and/or regional lymphadenopathy.
- Tests: positive percussion sensitivity. No response to thermal or electrical stimulation. Radiographic evidence of periapical radiolucency.
- Treatment: antibiotics (e.g. penicillin VK 500 mg QID, amoxicil 500 mg tds, or for penicillin-allergic patients, clindamycin 250–300 mg QID), analgesics, establishment of adequate drainage either through the pulp chamber, by incision and drainage of the vestibule or by extraction. If drainage will not require opening fascial planes then extraction should be done as the initial therapy. When fascial planes will be violated by an extraction (e.g. a 'surgical extraction'), the patient should initially be placed on antibiotics, an incision and drainage (I&D) done and the extraction performed when less acute, usually in 1–2 days.

Maxillary sinusitis with referred pain to teeth

- History: unilateral or bilateral pain in maxillary posterior teeth, usually difficult to localize to one tooth and often involves premolars and molars with root apices adjacent to sinus. The patient may complain that 'all the teeth hurt' and also of increasing pain upon bending over. Pain may occur several weeks following resolution of 'flu, or upper respiratory infection. Otherwise, the patient presents with typical sinus symptoms.
- Examination: primary dental source should be ruled out. Discomfort when digital pressure is placed infraorbitally on the sinus wall. Transillumination of the sinus by placing a fiberoptic light against the hard palate may reveal an increased opacity on the affected side.
- Tests: percussion sensitivity of multiple maxillary teeth. Sinus (Water's or panoramic) films demonstrate increased radiopacity or an air-fluid level. Electric pulp testing should be normal.
- Treatment: with history of sinus infection, pain, drainage, blockage or dental sensitivity that does not improve in 24–48 h, treatment

with appropriate antibiotics and topical nasal decongestant for 3–5 days is recommended. Chronic or refractory cases should be referred to an otolaryngologist [ENT surgeon].

- Prognosis: excellent. Symptoms usually resolve within several days if due to sinus rather than odontogenic source.

Coronal fracture ('fractured/cracked tooth syndrome')

- History: sharp, intermittent, localized pain, usually with chewing (releasing). May have history of trauma to tooth/jaw, recent restoration, or chewing ice.
- Examination: pain elicited by biting pressure or, classically, with release after biting on a tongue depressor. Fracture is usually evident upon close inspection of a dry tooth with mirror and good lighting. Often occurs on marginal ridges at contact point or lingual/occlusal adjacent to overextended restoration groove. May run over cusp tip or be circumferential.
- Treatment: cusp capping restoration often necessary. Intermediate restoration material (IRM), if necessary using an orthodontic band to stabilize, followed by removal or reduction of the fractured area for several weeks to allow for resolution of symptoms. Possible endodontic therapy or extraction if fracture involves furcation or extends below cemento-enamel junction.

Dental pain of other origin

Occasionally, pain that appears to be of odontogenic origin actually originates from other sources. Possibilities for such pain include referral from a myofascial source, myocardial ischemia, otalgia, sickle-cell crisis and adverse effects of medications such as vincristine or vinblastine. These sources must be considered when no odontogenic source is identified.

Soft tissue lesions

Periodontal abscess

- Etiology: ○ Acute exacerbation of chronic periodontitis; unable to drain through gingival crevice. ○ Localized plaque and/or calculus deep in gingival crevice. ○ Foreign body in the gingival crevice. ○ Endodontic abscess. ○ Root fracture.
- Diagnosis: ○ Progressive localized pain and deep isolated pocket formation. ○ Gingival tissues become red, swollen and painful

- with possible purulence from gingival crevice. ○ Tooth mobility.
- Foreign body may be found in crevice. ○ Non-vital pulp possible. ○ Identification of root fracture with deep pocket.
- Treatment: ○ Local anesthesia. ○ Irrigation with saline. ○ Ultrasonic debridement, scaling and root planing. ○ Incision and drainage if fluctuant, with or without a Penrose drain, to obtain drainage through gingival crevice. ○ Antibiotic coverage in presence of systemic signs or symptoms (penicillin VK 500 mg QID for 5–7 days, or amoxil [amoxicillin] 500 mg tds or, for penicillin-allergic patients, clindamycin 250 mg QID). ○ Careful periodontal follow-up.

Necrotizing ulcerative gingivitis or periodontitis

- Etiology: necrotizing ulcerative gingivitis (NUG) and necrotizing ulcerative periodontitis (NUP) are painful, non-contagious bacterial infections of the papillary and marginal gingiva. ○ Usually an opportunistic infection of mixed anaerobic flora, but anaerobic spirochetes and fusiforms commonly predominate. ○ Commonly associated with mild local or systemic immunosuppression that accompanies periods of emotional stress, fatigue, malnutrition, poor hygiene, pre-existing gingivitis and smoking. ○ The periodontitis form has been associated with the systemic immunosuppression resulting from HIV infection.
- Diagnosis: ○ Bleeding, necrosis and blunting of the interdental papillary gingiva with pseudomembrane formation. ○ Gingival pain, usually severe and halitosis. ○ Fever, malaise, cervical lymphadenopathy. ○ Periodontitis form also associated with periodontal ligament attachment loss and alveolar bone destruction.
- Treatment: ○ Saline irrigation using a large syringe and plastic IV catheter. ○ Gross mechanical debridement (ultrasonic or, if possible, scaling and curettage) using local anesthesia. ○ Oral hygiene, dietary and stress counseling. ○ Antibiotic therapy when systemic signs present (clindamycin 250–300 mg QID or metronidazole 250 [200] mg tid for 7 days). ○ Prompt follow-up appointment for oral hygiene. ○ Analgesic medication as needed. ○ Consider HIV testing when periodontitis form is present or if index of suspicion is high.

Herpes simplex infection

- Etiology: infection caused by the herpes simplex type 1 (HSV-1) or herpes virus type 1 (HHV-1) virus or, less commonly, by the

herpes simplex type 2 (HSV-2) or HHV-2 virus, which more commonly causes genital lesions. Approximately 80% of the adult population have antibodies following primary infection. The latent virus persists in the trigeminal nerve ganglion innervating the affected area, where it may be reactivated to reappear later, under a variety of conditions, as a recurrent herpes infection.

Primary herpetic gingivostomatitis

- **Diagnosis:** ○ Usually seen in children, or young adults not previously exposed to virus. May be subclinical or quite severe. ○ Prodrome of fever, irritability, headache, dysphagia and regional lymphadenopathy. ○ A few days later, the patient reports painful gingivitis followed by multiple yellowish, fluid-filled vesicles on the lips, tongue, buccal mucosa and hard palate, which rapidly rupture to form ragged, extremely painful ulcers. These ulcers last 7–14 days, crust over and heal without scarring. ○ Diagnosis is usually clinical, although the virus can be cultured from fluid of an intact vesicle. Must be differentiated from erythema multiforme.

Recurrent herpes

- **Diagnosis:** ○ Usually seen as an attenuated form of primary infection. ○ Reactivated by trauma, emotional stress, fatigue, menstruation, pregnancy, respiratory infections or prolonged exposure to sunlight. ○ Prodromal symptoms include burning, tingling or pain at the site where the recurrent lesion will appear. ○ May see one or multiple small vesicles, which quickly ulcerate and coalesce, leaving a small red area with or without an erythematous halo and which heal without scarring in 7–14 days.

Treatment

- **Primary herpes** ○ Adequate hydration and nutrition. In severe cases and with young children, this may require intravenous rehydration and dietary supplementation. ○ Systemic and topical analgesics as required (e.g. viscous lidocaine 2% swished and expectorated prior to meals). ○ Avoid aspirin in young patients. ○ In immunocompromised patients with primary herpetic stomatitis or mucocutaneous herpes simplex infection, consider intravenous acyclovir (5 mg/kg every 8 h, slowly).
- **Herpes labialis** ○ May benefit symptomatically from topical acyclovir (5% ointment) or penciclovir (1% cream) but only if

given during the prodromal stage. ◦ Patients with frequent, recurrent bouts of herpes labialis can benefit from oral acyclovir given at the first sign of recurrence (200 mg five times per day).

Aphthous ulcers

- Etiology: the etiology of aphthous ulcers is not clearly understood but they appear to be autoimmune with many possible contributory mechanisms, including psychic, allergic, microbial, traumatic, endocrine and heredity. Despite some clinical similarities, aphthae are separate and distinct entities from recurrent herpetic lesions.
- Diagnosis: ◦ Can occur at any age. ◦ Originates as an erythematous macule or papule that undergoes central blanching, necrosis and eventual ulceration. Shallow ulcers range in size from 0.5 (minor aphthae) to 3 cm (major aphthae). Demonstrates gray or yellow necrotic center and an erythematous halo. ◦ Although usually singular, they can occur in small groups (herpetiform type) that later become a single or a few confluent ulcers. ◦ Almost always occur on non-keratinized, unattached tissue (e.g. vestibule, ventral tongue, labial mucosa, floor of mouth). ◦ Pain is moderate to severe.
- Treatment: generally supportive in nature, as the lesions usually disappear in 7–14 days. Particularly severe aphthae and major aphthae might require additional measures. This should include adequate hydration and nutrition. Although there is no proven treatment for aphthae, a number of clinical therapies have been advocated for minimizing pain or shortening the life of the ulcer, including: ◦ antibiotics – tetracycline (250 mg in 5 cc sterile water) or chlorhexidine mouthwashes ◦ protective topical dressings such as hydroxypropyl cellulose (Zilactin) or Orabase used PRN ◦ topical steroids such as Kenalog [Adcortyl®] in Orabase or fluocinonide (Lidex) ointment twice a day ◦ analgesics – benzocaine in Orabase applied PRN or benzydamine [Difflam] rinse, if available.

Burns

- Etiology: ◦ Chemical – most commonly seen with topically used salicylates (e.g. aspirin), which cause coagulation necrosis. Iatrogenic chemical burns can result from common materials such as eugenol. Occasionally seen with accidental or intentional ingestion of caustic materials (e.g. lye). ◦ Physical – can occur in a child biting an electrical cord or a burn from a dental hand-piece. Also common from hot food (e.g. 'pizza palate').

- **Diagnosis:**
 - Mild burns (first degree) manifest as erythema.
 - More severe burns will be mixed red–white areas, or just white areas, indicating tissue necrosis.
 - Electrical wire burns usually occur at the commissures of the mouth. Can cause severe scarring and contraction if left to heal without treatment. Can be complicated by delayed hemorrhage from the facial/labial arteries.
- **Treatment:**
 - Most mild burns require no treatment and heal spontaneously, although adequate hydration and nutrition must be assured.
 - More severe burns may require debridement of necrotic tissue. Can be accomplished with or without local anesthesia as warranted.
 - Saline rinses and good oral hygiene.
 - Topical (e.g. viscous lidocaine) or systemic analgesics often necessary.
 - For electrical burns, the patient should be referred immediately to a pediatric dentist for splint construction to prevent contracture of the commissures subsequent to healing and fibrous scarring.
 - Swallowed caustics – refer for endoscopy.

Human bites

The usual organisms are *Staphylococcus aureus*, *Streptococcus species* and *Eikenella corrodens*. Anaerobic bacteria such as *Bacteroides*, *Prevotella*, *Fusobacteria* species and others are common. Gram-negative species are less common. *E. corrodens* is especially important because of its unusual antibiotic sensitivity, being sensitive to penicillin and ampicillin but resistant to semisynthetic penicillins and first-generation cephalosporins.

Management

- All bites should receive appropriate tetanus prophylaxis. Treatment then involves thorough cleansing, copious irrigation, debridement and the appropriate use of prophylactic antibiotics. Bites often occur in daycare settings. Child abuse should be suspected in bites with a questionable history.
- Human bites to the face seen within 24 h can be primarily sutured after appropriate cleansing and debridement. Prophylactic antibiotics should be given.
- Hand bites require special treatment because of the possibility of unrecognized penetrating injury to a joint. Human bite injuries to the hand must be irrigated thoroughly and should not be sutured primarily because close follow-up is essential. There is a high

incidence of infection of the soft tissue and joint space (metacarpophalangeal).

- Treatment recommendations for bites other than the hand and face are individualized but always include thorough debridement and irrigation and generally prophylactic antibiotics.
- Broad-spectrum second-generation cephalosporins have been widely recommended for human bites. A combination of penicillin and a penicillinase-resistant penicillin can be used. Amoxicillin plus clavulanic acid (Augmentin) is also widely used.

POSTOPERATIVE EMERGENCIES

Postoperative complications sometimes pose difficulties for dentists because little might be known about the original procedure.

- Acquire a complete history of present illness, including as many details about the original procedure as the patient can remember. The medical records should be obtained, if possible.
- Conduct a thorough physical examination of the involved site.
- Contact the doctor who performed the original surgery, if possible.

Bleeding

This can be a particularly frightening complication to the patient or family. Any amount of blood (as little as 5 or 10 cc) can be considered heavy bleeding by the patient when it originates from the mouth or involves the patient's clothing. Blood will mix with saliva in the mouth, increasing the apparent volume of 'blood' present.

Bleeding is most commonly due to local factors and is rarely a manifestation of an underlying systemic problem.

Bleeding from an extraction or bony surgery site

- Identify the site of origin: ○ A small bleeding vessel within the bony wall of the socket. ○ Brisk bleeding from the apical area indicating possible arterial damage especially if pulsatile. ○ Bleeding emanating from the soft tissue around the socket. ○ Bleeding from granulation tissue left in the socket. ○ Generalized oozing from all areas.

- Etiology:
 - Loss of organized blood clot from smoking, excessive spitting and rinsing or using a straw within 24 h of surgery. Can also be caused by salivary plasminogens.
 - Reopening of a vessel that was tamponaded or vasoconstricted at the time of surgery.
 - Loss of one or more sutures.
 - Excessive highly vascular granulation tissue in the socket (as is often seen in severe periodontal disease).
 - An acquired coagulopathy – most commonly drug related (e.g. warfarin or substances containing aspirin or alcohol).
 - Less frequently, an inherited coagulopathy.
- Management:
 - Thorough history and physical examination. Particular emphasis should be placed on current medications (patients are often unaware of medications that may impair coagulation). Also inquire about compliance with postoperative instructions; take care phrasing these questions (e.g. 'Have you had to spit much blood to keep from swallowing it?').
 - Ensure the appropriate suction equipment (with a small-diameter stiff suction tip) and lighting (preferably a headlight) is available.
 - Examine for obvious bleeding vessels in or around the site. If visualized, electrically coagulate or ligate with resorbable suture, under local anesthesia.
 - If the bleeding is noted to be brisk or arterial (pulsatile) in nature, inject local anesthesia with a vasoconstrictor, debride, irrigate the socket and examine closely for specific areas of bleeding. Small bone bleeders may be crushed with a metal instrument or stopped with a small amount of bone wax. Apical or non-isolatable bleeds should be packed with Surgicel, Avitene or Gelfoam. Following this, or if bleeding is coming from the soft tissues, use interpapillary or figure-of-eight 'hemorrhagic' sutures and reinstitute pressure.
 - If no obvious vessels are seen, initial management should always be direct pressure. This is accomplished by biting on gauze, under observation, for 20 min. If this fails, a gauze impregnated with liquid topical thrombin or the antifibrinolytic syrup, epsilon aminocaproic acid (Amicar) or 5% tranexamic acid, can be tried for an additional 20 min.
 - When local causes have been ruled out, appropriate laboratory tests should be ordered. This includes a complete [full] blood count (CBC) [FBC] with differential and platelet count,

prothrombin time (PT) and international normalized ratio (INR) and partial thromboplastin time (APTT). If abnormalities are detected, medical consultation is indicated.

- Instructions: when the bleeding is controlled, the patient should be given careful verbal, and preferably written, instructions to decrease risk of recurrence.

Bleeding from the gingiva

- Etiology: ○ Severe gingival or periodontal infection, including acute necrotizing ulcerative gingivitis, linear gingival erythema and primary herpes. ○ Trauma. ○ Intrinsic (e.g. hemophilia) or extrinsic (medications) coagulopathy. ○ Other systemic cause (e.g. acute leukemia).
- Diagnosis: history and physical examination should differentiate local from systemic sources. When indicated, obtain appropriate blood tests.
- Management: ○ Injection of local anesthesia with vasoconstrictor into the area. ○ Gauze pressure. ○ Removal of granulation tissue in periodontal conditions. ○ Repair of traumatic injuries. ○ Medical consultation for coagulopathies.

Bleeding from postoperative soft-tissue incisions

- Etiology: ○ Wound margin bleeder. ○ Dead-space hematoma. ○ Arterial or venous bleeding within the wound itself.
- Diagnosis: ○ Examine and palpate the surgical site. Gradual discoloration and swelling at the site usually indicates an underlying hematoma. ○ Brisk, bright red blood usually indicates arterial bleeding. This may be immediate or delayed (from loss of a suture or vascular invasion).
- Management: ○ Wound margin bleeders and slow, venous bleeders can usually be stopped with direct pressure or a pressure bandage, but might require additional sutures. ○ Deep arterial bleeding mandates opening the wound; explore for vessel to be coagulated or ligated. ○ Hematomas should be evacuated by opening a small area of the incision, probing with a hemostat until the hematoma is found and expressing the blood. Direct pressure and a pressure bandage should be used to prevent secondary hematoma formation. If bleeding persists, the wound should be explored.

Postextraction pain

- Etiology: ○ Normal pain due to inflammation. ○ Alveolar osteitis ('dry socket') due to loss of the blood clot within the socket and exposure of sensory nerve endings within the socket. ○ Localized infection (periostitis or alveolar infection). ○ Localized tenderness due to loose bone fragment.
- Diagnosis: a careful review of the history will usually lead to a diagnosis:
 - Normal pain: begins soon after surgery and remains constant or improves slowly with time (varies from patient to patient).
 - Alveolar osteitis: pain remains constant or initially improves after surgery, then suddenly increases after 3 or 4 days. Much more common in the mandible than the maxilla. Often radiates to the ipsilateral ear. The examination will only show loss of the clot from the socket. A foul odor is common.
 - Localized infection: usually presents a few days to a few weeks after surgery. Physical examination reveals signs of inflammation and infection. May see purulence and there might be an elevated white blood cell count and fever. Palpation of the area will be acutely painful, especially with periostitis.
 - Fractured buccal plate: palpation over socket, usually buccal, will reveal tenderness and possibly crepitus.
- Management:
 - Normal pain: reassurance, observation and analgesics as indicated.
 - Alveolar osteitis: gentle irrigation of socket to remove debris and placement of a sedative dressing (e.g. Eugenol on 1" × 1/4" strip gauze or Alvogyl®). This should be left for 4–5 days. Replacement during that period should be carried out at any time the patient feels the pain return. Analgesics should be prescribed.
 - Localized infection: periostitis is usually treatable with antibiotic therapy (e.g. penicillin VK 250–500 mg QID for 5 days). Socket infections are treated with antibiotics and incision and drainage as necessary.
 - For fractured bone: remove suture, identify and remove bone fragment, irrigate and resuture.

Nausea and vomiting

- Etiology: ○ Swallowed blood. ○ Post-anesthetic effects if IV sedation or general anesthesia used. ○ Drug side-effects (antibiotics, analgesics).
- Diagnosis: ○ Examine for bleeding. ○ Determine type of anesthesia used for surgery. ○ Review medications.
- Management: ○ Control bleeding if present. ○ If medication-induced, discontinue or change medications to ones less associated with nausea (e.g. acetaminophen [paracetamol] instead of codeine or ibuprofen). ○ If no change or if anesthetic related, consider an antiemetic given rectally, IV or IM. For example:
 - Phenergan [Stemetil] = promethazine 25 mg PO, IM, PR, IV
 - Compazine = prochlorperazine 10 mg IV, PO, IM; 25 mg PR
 - Tigan = trimethobenzamide 250 mg PO; 200 mg IM, PR
 - Inapsine = droperidol 2.5 mg IV, IM
- [Ondansetron 4 mg IV]

ODONTOGENIC INFECTIONS

General concepts

Pain from odontogenic infections are the most common problem seen by dentists in the emergency department. In fact, because of their ubiquitous nature, pain, infection and swelling in the face and neck region should generally be assumed to be of odontogenic origin until proven otherwise. When addressed early, complications are rare and minor. When allowed to progress and when a particularly virulent organism is involved, or when the host is immunocompromised, odontogenic infections can lead to serious morbidity or even death.

Diagnosis of infection

History

The patient will commonly have a history of toothache at some point in the past, although a lifetime of pulpal regression might spare people of advanced age this particular antecedent to abscess. Swelling will usually have begun only recently and exacerbated quickly. The pain and swelling might have improved and then worsened again as the infection traverses different spaces. The

history should include the duration of the infection as well as any previous treatment and its response.

Physical examination

Swelling

- Fluctuant: fluid-filled area indicating abscess formation.
- Non-fluctuant: some organisms (e.g. streptococci) tend to cause spreading infections rather than abscesses. This is seen as a cellulitis.
- Reactive edema: the tissue surrounding the area of infection may develop moderate to severe secondary edema. Often seen in the periorbital area when associated with maxillary dental infections. Can be differentiated clinically from infection by its soft, non-fluctuant, non-tender nature.

Erythema

- Pain to palpation: an area of infection is usually quite tender. Decreasing tenderness is often indicative of the effectiveness of therapy.
- Trismus: as infections impinge on the muscles of mastication, trismus will become evident.
- Source: the source of an odontogenic infection is usually easily identified as a tooth with carious exposure of the pulp or severe periodontal condition. When an obvious source cannot be isolated, non-odontogenic sources must be considered.
- Drainage: in some cases, spontaneous purulent drainage may be evident. This is often accompanied by bad odor and taste.

Lymphadenopathy

Radiographic data. Clinically evident sources should always be confirmed with radiographic data. This could include a panoramic, periapical or occlusal radiograph (useful for children when other films not possible), or lateral oblique views in less cooperative patients, particularly those with a learning disability.

Medical management of odontogenic infections

Systemic medical evaluation

Infections of odontogenic origin are usually managed before the patient demonstrates systemic manifestations. The presence of

fever, chills, shaking and malaise – or of confusion and clouded consciousness ('delirium') in an elderly person – indicates that complete systemic evaluation is warranted. In addition, the spread of infection is related to the virulence of the organism and the state of the host's immune system. As such, patients with rapidly advancing odontogenic infections should be thoroughly evaluated for evidence of diminished immune competence.

Indications for hospitalization

- Systemic involvement: fever, dehydration with orthostasis requiring parenteral fluids and nutrition.
- Evidence of spreading tissue necrosis or cellulitis involving critical areas such as periorbital region and areas with potential airway compromise (sublingual, submandibular and/or parapharyngeal spaces).
- Immune system compromise: HIV, diabetes, steroid therapy, alcoholism, cancer chemotherapy.
- Need for intravenous antibiotics.
- Infections requiring special treatment: fungal infections, osteomyelitis, actinomycosis.
- Patients unable to manage their infections at home due to disability.
- Children who can't, won't or have not eaten, or who have unreliable parents/guardians.

Nutrition

Patients with infection are often unable to maintain their dietary and fluid intake and should receive IV maintenance fluids. Patients unable to eat for longer than 48 h should be considered for nasogastric feeding.

Culture and sensitivity (C&S) testing

In all but the most minor of fluctuant odontogenic infections (and these as well if they are resistant to initial treatment), consider sending cultures for C&S. This may be accomplished by:

- Aspiration: a 3–10 cc syringe is attached to a 14–20 gauge needle, which is then inserted through uncompromised and cleansed tissue into the area of fluctuance. May be used for both aerobic and anaerobic culturing.
- Purulence specimen: a small amount of purulence may be collected on a sterile swab and submitted for culture. This is ineffective for anaerobic infections and is subject to contamination.

- Tissue specimens: a small amount of tissue is excised and sent in a sterile container for testing. This not only allows aerobic and anaerobic evaluation but also quantitative analysis.

Principles of antibiotic therapy

- Initial therapy is usually empirical, based on the likely source and organism involved. When available, therapy should be guided by culture and sensitivity testing results.
- Should be parenteral with severe infections.
- When instituting empirical therapy, always use the least expensive, least toxic and narrowest-spectrum antibiotic that will cover the likely organisms.
- Patients must be asked about a history of drug allergy or current medications that could interact with the antibiotics used (e.g. birth-control pills, warfarin therapy and gastric-ulcer medications such as cimetidine).

Diagnostic imaging

Diagnostic imaging studies can help guide surgical therapy. They are used in cases of deep fascial space infections, rapidly spreading infections and infections impinging on vital structures such as the airway. Studies to be considered include:

- Computerized tomography (CT): useful for determining extent of infection, in both soft tissues and bone. Studies can be done with intravenous contrast, assist in determining extent of hyperemia surrounding infectious site.
- Magnetic resonance imaging (MRI): useful for determining extent of infection, especially within soft tissues. Advantage is lack of ionizing radiation exposure. Disadvantages: more expensive than CT and patients must lie still for lengthy periods because of prolonged delay for image capture.
- Ultrasound: used for locating abscess cavities within soft tissues.

Laboratory data

Aside from culture and sensitivity testing, a few laboratory tests can aid in the diagnosis and management of infections.

- Complete [full] blood count with differential:
 - Leukocytosis (WBC $>12\,000/\text{mm}^3$) indicative of infection.
 - A 'shift to the left' (presence of many immature or 'segmented' neutrophils) on differential WBC count is seen with acute

infection. Chronic infections do not have this shift and usually have a marginally increased white cell count.

- Elevated platelet count ($> 500\,000/\text{mm}^3$) in some cases.
- Chemistry studies:
 - Blood urea nitrogen (BUN) may be elevated due to dehydration.
 - Hypernatremia (Na^+) and hypochloremia (Cl^-) may also be seen with dehydration.
 - Albumin levels may drop due to malnutrition or necrotizing infections.
- Urinalysis:
 - Dehydration leads to increase in specific gravity (> 1.025).
 - Severe dehydration can lead to oliguria and acute tubular necrosis and renal failure.
 - Severe infections can demonstrate proteinuria.

Surgical management of odontogenic infections

Diagnosis

Prior to any surgical intervention it is imperative that the offending source be isolated and the specific spaces involved with infection be delineated. This can be done by clinical examination or by diagnostic imaging.

Removal of source

When possible, the offending source of the infection should be removed. In many cases this may be adequate treatment (e.g. a tooth extraction with adequate spontaneous drainage from the socket). Removal of the source may include:

- Extraction of a tooth: contrary to popular belief, the extraction of an acutely infected tooth is not contraindicated. This is the appropriate treatment, except when such removal would open up additional fascial planes and spaces to the infection, for example, removal of an impacted tooth requiring elevation of a flap.
- Pulpectomy or endodontic procedures in permanent teeth.
- Pulpotomy or pulpectomy in primary teeth.
- Removal of foreign bodies (e.g. bullet fragment).
- Removal of necrotic bone.
- Removal of infected sutures (stitch abscess).

Principles of incision and drainage (I&D)

When removal of the source is inadequate for allowing elimination of abscessed areas, surgical access is warranted to promote gravitational drainage, although this is rarely needed in children. The particular areas to be drained or explored should be determined presurgically so that they can be prepped accordingly. Basic principles of surgical drainage are:

- When in doubt, drain. With few exceptions, an I&D will only help the situation and, even when non-productive, will allow for future drainage should it begin after the procedure.
- Prior to I&D, consideration must be given to patients with bleeding disorders, those who are taking anticoagulant therapy or immunosuppressive agents.
- Extraoral incisions should be placed where they will be cosmetic and allow gravitational drainage with the patient in the supine or upright position.
- All drains should be secured to prevent premature loss.
- All incisions should be designed to prevent injury to important structures (e.g. nerves, blood vessels, ducts).
- Drains should be left in place and monitored until they are no longer productive, generally 1–3 days.

Anesthesia

- Local anesthesia injected into an abscess will usually fail because of the acidic pH of the region.
- Local anesthesia infiltrated into the mucosa or regional block injections are usually successful (e.g. mandibular block or V2 block).
- Care should be exercised to inject around an area of infection, not through it.
- If local anesthesia is not possible, general anesthesia may be necessary, especially for larger or deeper fascial space infections.
- Trismus, a common finding with infections near the muscles of mastication, is a product of pain and subsequent spasm in acute infections (not necessarily true with chronic infections, where fibrosis may have occurred). When a patient is placed under general anesthesia, mouths with acute infections will almost always open without difficulty.

Intraoral I&D (Fig. 5.1)

- Locate the area of maximum fluctuance. Provide local anesthesia with mucosal infiltration or regional anesthesia.

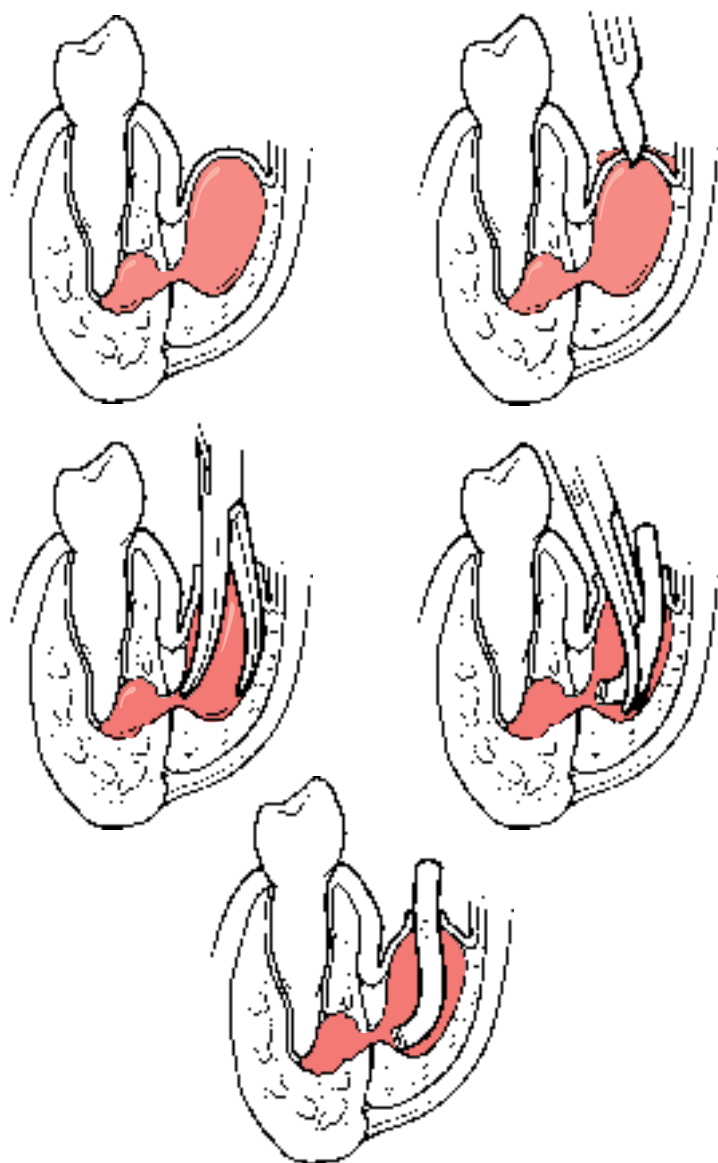


Fig. 5.1 Intraoral incision and drainage.

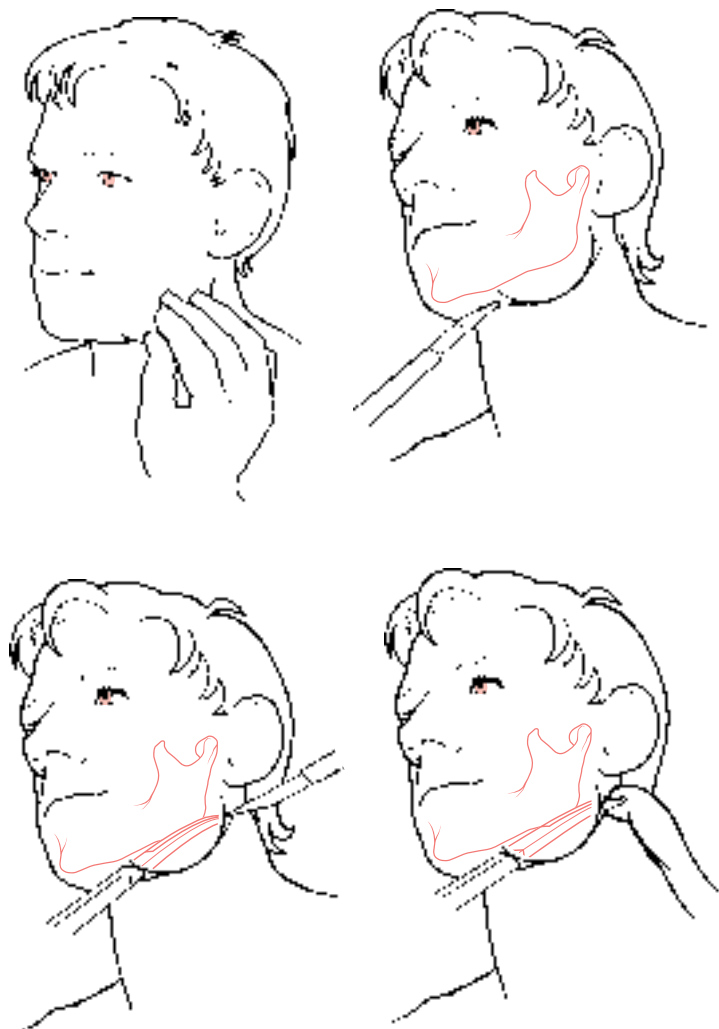


Fig. 5.2 Extraoral incision and drainage.



Fig. 5.2 Extraoral incision and drainage (*continued*).

- Using a #15 or #11 blade, make a 5 mm incision in the mucosa overlying the area of fluctuance.
- Use a mosquito hemostat to bluntly explore the abscess until purulence [pus] is obtained.
- When all the purulence [pus] has been evacuated and the I&D site irrigated with normal saline, place a small Penrose drain (a hollow latex tube) or other latex material drain well into the abscess cavity and suture it to the end of the wound with a 4-0 non-resorbable suture.
- Leave approximately 1 cm of the drain visible in the mouth.
- Encourage the patient to use saline rinses to keep the drain open.

Extraoral I&D (Fig. 5.2)

- The procedure may be performed under local anesthesia, with IV sedation or under general anesthesia. If local anesthesia is to be used, inject 2–3 cc in the region of the incision and another 2–3 cc in the path of the proposed procedure. Prep area to be drained with an iodine scrub solution and drape in sterile fashion, allowing plenty of room to work. Locate areas of fluctuance, any areas of compromised skin and an area of non-compromised skin that would allow for dependent gravitational drainage and a good

cosmetic scar. Ideal places are in skin creases or just below the mandible. Incisions should never be placed in compromised skin due to the lack of healing ability.

- Make a 1-cm incision through the skin and into the subcutaneous tissue. Using a hemostat, bluntly dissect into the abscess cavity. Open the hemostat to allow the purulence [pus] to flow freely.
- When large spaces are to be drained, it is advisable to run a $\frac{1}{4}$ " Penrose drain through the space and exit it at the other end of the space, thus creating a 'through and through' drain, which ensures that the drain is in the space and not just folded onto itself under the skin margin.
- Place the drain into the depth of the abscess cavity and suture it to the margin of the incision with any non-resorbable suture. Cover the area with a sterile, non-sticky dressing such as Telfa [Melolin] and gauze.
- A suture can be placed through the ends of the drain to secure placement.

Postoperative care

- Maintain the drain in place for as long as it is productive, generally 1–3 days. Although drains sometimes need to be left in for as long as a week (in severe infections), at some point they become a foreign body and will prolong the drainage. Therefore, removal at the earliest possible time is recommended.
- Change the dressings as often as necessary to keep the wound clean, at least once per day.
- Maintain antibiotics for at least 24 h after the pyrexia has resolved.
- Upon removal of the drain, allow the incision to granulate under a sterile dressing. Intraoral incisions require no dressing.

SALIVARY GLAND EMERGENCIES

Acute parotid infections

Etiology

Acute parotid infections are usually caused by retrograde infection from the oral cavity and are secondary to decreased salivary flow from dehydration or an immunocompromised state. The causative organisms are usually staphylococci or streptococci but many other

organisms have also been implicated. Viral acute parotitis is common in children as a bilateral swelling. The most common candidates for acute parotid infection are:

- newborns
- elderly patients
- postsurgical patients
- patients on dehydrating medications (e.g. diuretics, anticholinergics, tranquilizers, antihistamines)
- immunocompromised patients
- patients with primary or secondary Sjögren's syndrome.

Diagnosis

The diagnosis is usually straightforward due to the unique clinical presentation, which includes:

- sudden onset of firm swelling, pain and erythema of the preauricular (parotid) or floor of mouth/submandibular region (sublingual/submandibular gland)
- 20% of cases are bilateral
- temperature elevation (not always observed in an elderly person, where the infection is more likely manifested as confusion and disorientation)
- leukocytosis
- thick, purulent discharge from Stenson's duct (opposite maxillary first molar) or Wharton's duct upon milking.

Differential diagnosis

- Sialosis.
- Pneumoparotid: will demonstrate crepitus and will not have the purulent discharge.
- Mumps (bilateral).
- Lymphadenopathy: discrete enlargement without purulent discharge.

Treatment

- Intravenous rehydration is the cornerstone of treatment in most cases. Careful monitoring and control must be exercised with elderly or debilitated patients to prevent fluid overload.
- Discontinuation, if possible, of any medicines associated with xerostomia.
- Empirical antimicrobial therapy with an antistaphylococcal agent with anti-beta-lactamase activity, such as a cephalosporin or

dicloxacillin or cloxacillin. When anaerobic organisms are suspected, as in longer-standing cases, consider metronidazole.

- Culture and sensitivity testing of any purulence.
- In severe, non-responsive cases, surgical drainage may be required. This is accomplished by blunt dissection using a small submandibular or retromandibular incision and placement of a small Penrose drain. Care must be exercised to avoid the facial nerve in cases of suppurative parotiditis.

Obstructive sialadenitis

Etiology

Stones in the submandibular or parotid gland or duct are the major cause. However, ductal stricture from scarring, tumor, foreign bodies or mucous plugs can cause an identical clinical picture. Obstruction leads to back-up of saliva within the gland and a painful enlargement because the glands are bound by a restrictive, fibrous capsule.

Diagnosis

- Pain and swelling of the affected gland, usually just before mealtime.
- Gradual reduction in size within hours to days.
- More common in submandibular gland or duct.
- Milking of duct is either non-productive or produces a thick viscous discharge if the gland is secondarily infected.
- Occlusal, panoramic or facial X-rays will reveal radiopaque stones. Radiolucent stones or mucous plugs can be demonstrated with sialography.

Treatment

- Submandibular stones distal to the mylohyoid flexure (in the floor of the mouth) can be removed by making a small incision over the duct under local anesthesia. The stone is enucleated and the duct left unsutured to fistulate. A silk suture may be passed around the proximal portion of the duct prior to the procedure to prevent accidentally pushing the stone posteriorly.
- Submandibular stones proximal to the flexure or in the gland itself are usually treated by excision of the gland in the operating room [theatre] under general anesthesia.

- Stones in the parotid duct may be located by ultrasonography and enucleated through a 5-mm skin incision or, occasionally, by dilation of the duct.
- Lithotripsy, either extra corporeal or intraductal, may be attempted.

MAXILLOFACIAL TRAUMA

General principles of care

When dealing with multiple trauma, with few exceptions, facial injuries are not usually the first priority of treatment. Nevertheless, when the facial injuries are the most obvious problem, the dentist is often the first healthcare provider to see the patient. It is important to perform an overall assessment before proceeding to examine a specific oral or facial problem. As with all emergencies, the initial evaluator should always do the 'ABCs' first. Establishment of adequate respiratory and cardiac function and determination of neurologic status are paramount. Medical consultation should be obtained immediately for any aberration in the patient's condition. No analgesics, sedatives or anesthetics (or any other drug that could increase intracranial pressure) should be administered until neurologic or other medical complications have been ruled out.

The initial evaluation

Patent airway

The airway is often compromised by facial trauma as a result of fracture displacement, foreign bodies or the inability to maintain forward tongue posture:

- Assure a clear airway and normal rate and depth of breathing. Conscious patients will generally assume the body position that helps airway patency and they should be allowed to do so.
- Remove all foreign objects (e.g. pieces of teeth or restorations) from the oral cavity. Avulsed teeth may be reimplanted and then splinted if the patient is stable after medical assessment; alternatively, they can be stored in saline. Open the airway with a chin thrust, an oral or nasal airway or, if necessary, by cricothyroidotomy, if unable to place an ET tube.

Vital signs

Vital signs can be used to determine adequate circulatory function as well as indicators of intracranial injury:

- Decreased blood pressure and/or increased heart rate may indicate shock.
- Increased intracranial pressure is often associated with a decreased heart and respiratory rate in conjunction with increased blood pressure (Cushing's triad). This situation warrants immediate medical attention.

Neurologic evaluation

Careful examination can provide valuable information regarding both localized facial neurologic and intracranial injuries (see the Glasgow Coma Scale, Chapter 8.) Obtain neurosurgical consult for:

- Lack of spontaneous eye opening.
- Disorientation to verbal questioning.
- Inability to obey verbal commands.
- Rhinorrhea or otorrhea (indicative of cerebrospinal fluid leakage secondary to an anterior or middle cranial fossa fracture). Perform rapid and systematic cranial nerve examination:
 - Eyes: eye movements and sensation are used to evaluate cranial nerves (CN) III, IV, V and VI. If the eyes abduct fully, CN VI is intact. All the other eye movements (tested by having the patient follow finger movements in all four quadrants) indicate the status of CN III and IV. If the pupils are equal, round and reactive to light and accommodation (PERRLA), then CN II is unimpaired. If the patient feels a wisp of cotton on the cornea, CN V is intact. Vision can be tested grossly with a hand-held eye chart.
 - Face: CN V and VII are evaluated by examining the facial musculature and its sensation. A dental explorer or needle can be used to evaluate symmetric sensation to light touch, a function of CN V sensory division. Jaw opening without deviation can be used to evaluate the CN V motor component. However, it must be remembered that a jaw fracture can cause the jaw to deviate upon opening. Symmetry of the facial muscles on grimacing, frowning and eye closing indicates a normally functioning CN VII.
 - Speech and soft palate: if speech appears normal and the soft palate moves normally, CN IX and X are intact.

- Tongue: protrusion of the tongue without deviation from mid-line is normal for CN XII.
- Hearing: this can be tested by rubbing two fingers gently together, first behind one ear then behind the other. The auditory nerve (CN VIII) can be tested in this manner.
- Bilateral shrugging of the shoulders against pressure indicates normal function of the spinal accessory nerve innervated by CN XI.

Cervical examination

Traumatic facial injuries have a high correlation with neck injuries and it is important to maintain a high suspicion for the presence of associated cervical spine injury. Any significant facial trauma, therefore, mandates the need for a complete C-spine series of radiographs. Normal C-spine films do not completely rule out spinal cord injury; seek medical consultation. Only after ruling out cervical injury should a 'C' collar be removed and the head, neck or facial exams be carried out.

Abdominal examination

The abdomen is often injured in motor vehicle accidents. Examine for distention, tenderness and the presence or absence of bowel sounds.

Indications for immediate emergency treatment

Although facial fractures do not usually require priority emergency management, exceptions include:

- massive arterial bleeding
- airway compromise
- compound fractures should have at least temporary soft-tissue closure.

Diagnosis of facial trauma

Although the diagnosis of facial trauma is usually an obvious one, much information can be gained from a thorough history and physical examination.

History

The patient, or someone at the scene, should be questioned about details including loss of consciousness, seizures or hemorrhage. If

any of these are positive, or if the patient has no memory of the incident, suspect intracranial injury and seek appropriate medical consultation.

Ascertain the source (e.g. fists versus baseball bat), direction, number and force of the blows. This can give significant clues to potential fractures or complicating injuries. For example:

- injuries to the midline symphyseal region of the mandible often cause bilateral subcondylar fractures
- injuries to the lateral body can cause a contralateral subcondylar fracture
- bullet wounds can cause delayed tissue necrosis
- stab wounds often cause deep injuries not easily visualized on the surface
- injuries involving high density objects (e.g. baseball bat) should be suspected of comminution.

A tetanus booster will be needed if the wound is clean and the last booster was >10 years ago, or if the wound is dirty and the last booster was >5 years ago; tetanus immune globulin might be needed if no initial tetanus series was ever received.

Question the patient about pre-existing asymmetries, abnormalities or conditions. A change from the pretrauma occlusion often indicates a fracture within the facial skeleton. Also ask about pain, paresthesia or anesthesia, hearing or visual disturbance, breathing difficulty, headache, dizziness, change in occlusion, feeling of crepitus or dysphagia.

Data would suggest that head trauma in children under 2 merits a medical consult. Studies suggest children under 2 years do not react the same as older children and adults.

Head and neck physical examination

The examination should be carried out in a systematic fashion from the cranium to the clavicles.

Inspection

Careful examination for the following:

- Asymmetry or flatness.
- Ecchymosis: if this is seen in the mastoid region (Battle's sign) or periorbital areas bilaterally ('raccoon eyes') without evidence of direct trauma, it is indicative of a basilar skull fracture. Ecchymosis in the floor of the mouth is considered pathognomonic of a mandibular fracture.

- Lacerations that could indicate underlying fractures.
- Obvious proportional changes of facial dimensions. Changes in facial height or width, intercanthal width (normally < 35–40 mm) or apparent ramus height can indicate fracture.
- Examine occlusion carefully for any changes from the preoperative state noted. Broken teeth, steps in the occlusion, tooth mobility and an anterior open bite are all signs of fracture.

Palpation

Whenever possible, palpate in a bilateral, bimanual fashion (placing the area to be examined between one hand or finger and another). This aids in determining small discrepancies:

- Extraoral: palpate all facial bones for 'steps', mobility or crepitus from displaced fractures. Palpation should begin in the frontal region and progress to the orbital rims, zygomatic arch, malar buttress and entire inferior border of the mandible.
- Intraoral: palpate bimanually to feel for steps, hematoma or mobility. Carefully palpate the malar buttress for tenderness or steps, both indicative of a zygoma or maxillary fracture. Examine for maxillary fractures by placing the thumb and index finger of the 'reference hand' on either side of the nasal bridge while the other hand is used to grasp the anterior maxillary ridge above the teeth:
 - movement of the maxilla in the non-reference hand only indicates LeFort 1
 - movement of the maxilla in the reference hand only indicates LeFort 2 or 3
 - movement of the maxilla in both hands indicates multiple fractures of the midface
 - movement at the lateral orbital rim indicates a LeFort 3 fracture or combined fractures with a zygoma fracture.
- Ask the patient to open and close the mandible. Maximum opening between the incisal edges, deviation on opening and joint sounds are noted. The joint is felt by placing two fingers over the preauricular area, or in the ear canals, during excursions. Tenderness, popping, crepitus or clicking can indicate internal trauma to the joint or a condylar fracture.
- Air emphysema in the tissues is manifested by a 'crinkling' feeling and sound and indicates a fracture of a sinus or a laryngeal injury.

Radiographic evaluation

Although careful physical examination is certainly the best diagnostic tool for facial fractures, radiographic imaging can provide confirmation of clinically suspected fractures as well as additional information.

Mandibular fractures

- Right and left lateral oblique views: show the body and angle of the mandible and the position of the condyle.
- Submental vertex ('jug handle') view: shows the inferior border of the mandible and the zygomatic arches.
- Posterior–anterior (PA) view: shows the symphyseal region.
- Towne's view: provides an excellent view of the condyles and condylar necks including their position in the fossa.
- Panoramic: provides an excellent overall view of the mandible. Also provides a slightly better view of the symphyseal region and a good view of the subcondylar and coronoid regions.
- Occlusal view: when a midline fracture or a fracture involving the alveolus is suspected, an occlusal view may be helpful.
- Periapical films: used to show undisplaced fractures of alveolar bone and tooth root fractures.

Maxillary fractures

- Lateral skull: shows the frontal sinus, nasal bones, anterior nasal spine and profile of the anterior maxilla.
- Water's [occipitomenal] view: shows the maxilla, maxillary sinus, frontal sinus, orbital rims, zygomatic bones and frontal processes of the maxilla. Give special attention to comparing the volumes of the orbits. Asymmetries indicate orbital fracture. An airfluid level in the sinus indicates a fracture of the sinus wall.
- Panoramic.
- Occlusal and periapical views.
- Posterior–anterior skull.

Zygomatic fractures

- Water's [occipitomenal] view.
- Submentovertebral view.

Multiple facial fractures

- CT scan: use with 5 mm cuts if frontal bone fractures or multiple facial bone fractures are suspected, as this generally provides more accurate and detailed information than plain films. For even greater detail and information, 2 mm cuts allow three-dimensional reconstruction and computer manipulation.
- Angiography: penetrating injuries, such as a gunshot or knife wound to the region below the inferior border of the mandible, require angiographic determination of the extent of vascular injury. If located between inferior border of mandible and clavicular head, they will also need surgical exploration.

Treatment options for facial fractures

The aim is reduction of the fracture, fixation for an adequate period to allow for bone repair and general supportive and rehabilitative care.

Temporary stabilization

Mobile fractures of the facial skeleton are painful. It is often necessary, for practical or medical reasons, to delay definitive treat-

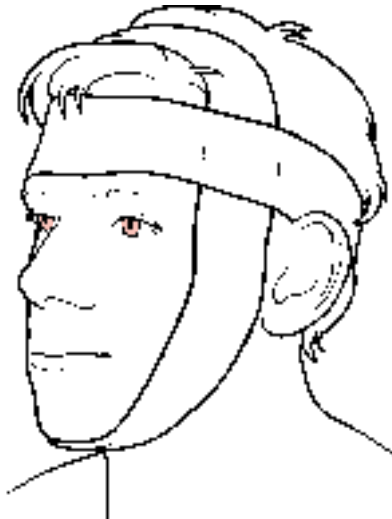

Fig. 5.3 Barton bandage.

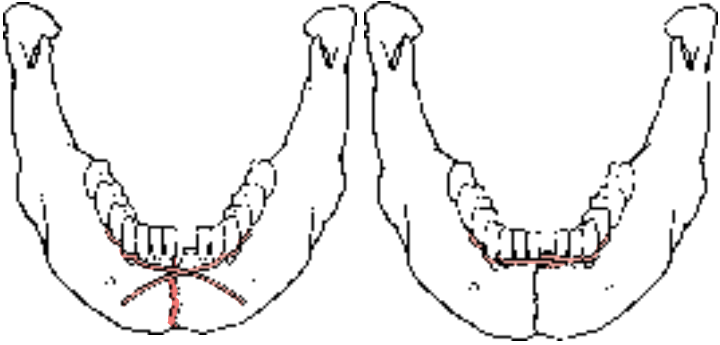


Fig. 5.4 Risdon wire technique.

ment for hours or even days. To decrease the discomfort, temporary stabilization may be utilized.

- Barton bandage: a simple bandage wrap composed of 24" gauze that is wrapped first vertically around the head several times and then horizontally around the forehead several times. This bandage is a simple and rapid mechanism for preventing mandibular opening (Fig. 5.3).
- Risdon wire: for anterior mandibular fractures, a 24-gauge wire twisted around each canine and then twisted to each other in the midline will approximate the fracture and prevent localized mobility. This can also be used with the Barton bandage. Alternatively, a single 24-gauge wire can be wrapped around all the anterior teeth and twisted to itself in the midline (Fig. 5.4).

Definitive reduction and fixation

The gold-standard is open reduction with internal fixation with miniplates. When undisplaced fractures occur behind the teeth, or when fractures occur within the dentate segment, closed reduction with intermaxillary fixation (IMF) for 4–6 weeks will often suffice for definitive treatment.

- Closed reduction with Ivy loops: a rapid method of obtaining fixation, used only for short-period IMF (Fig. 5.5). This can easily be performed in the emergency department [A&E] or clinic under local anesthesia.

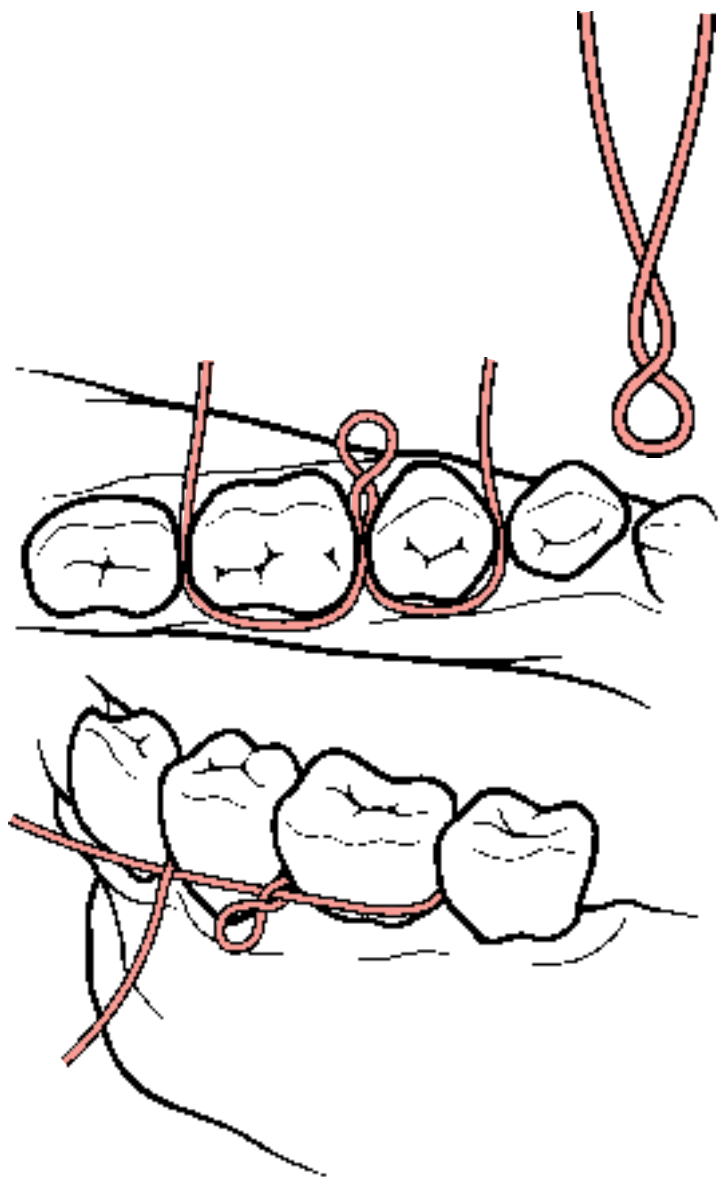


Fig. 5.5 Closed reduction with Ivy loops.

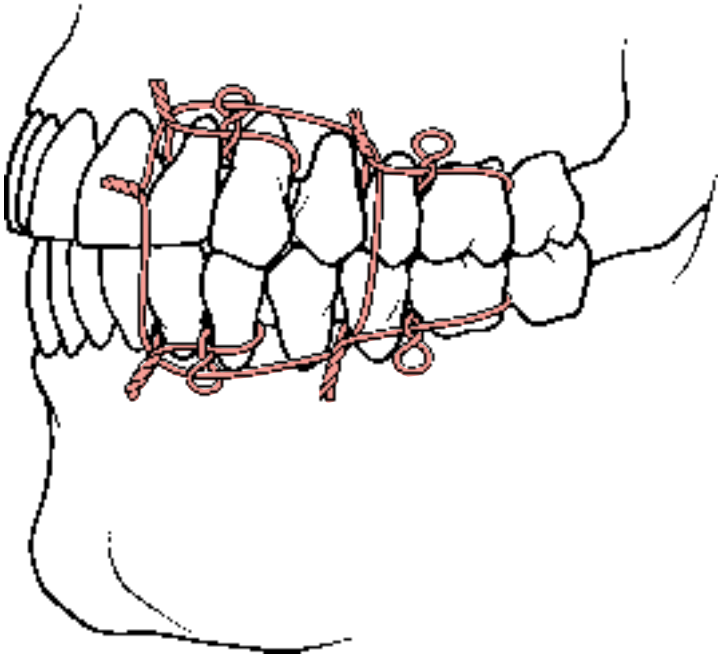


Fig. 5.5 Closed reduction with Ivy loops (*continued*).

- Erich arch bar maxillomandibular fixation (MMF): the best and most common way to obtain MMF. A 24-gauge wire is passed around the neck of each tooth using a wire twister. The wire is then twisted down over the arch bar with the lugs facing up in the maxilla and down in the mandible. The lugs can then be used to place interarch elastics or a box-type wire (Fig. 5.6). This procedure can be performed with local anesthesia/IV sedation or general anesthesia.

Dental and dentoalveolar trauma

Traumatic injuries to the teeth and supporting structures are a common ED [A & E] emergency (affecting some 5% of all school age children). A brief but comprehensive assessment of the overall

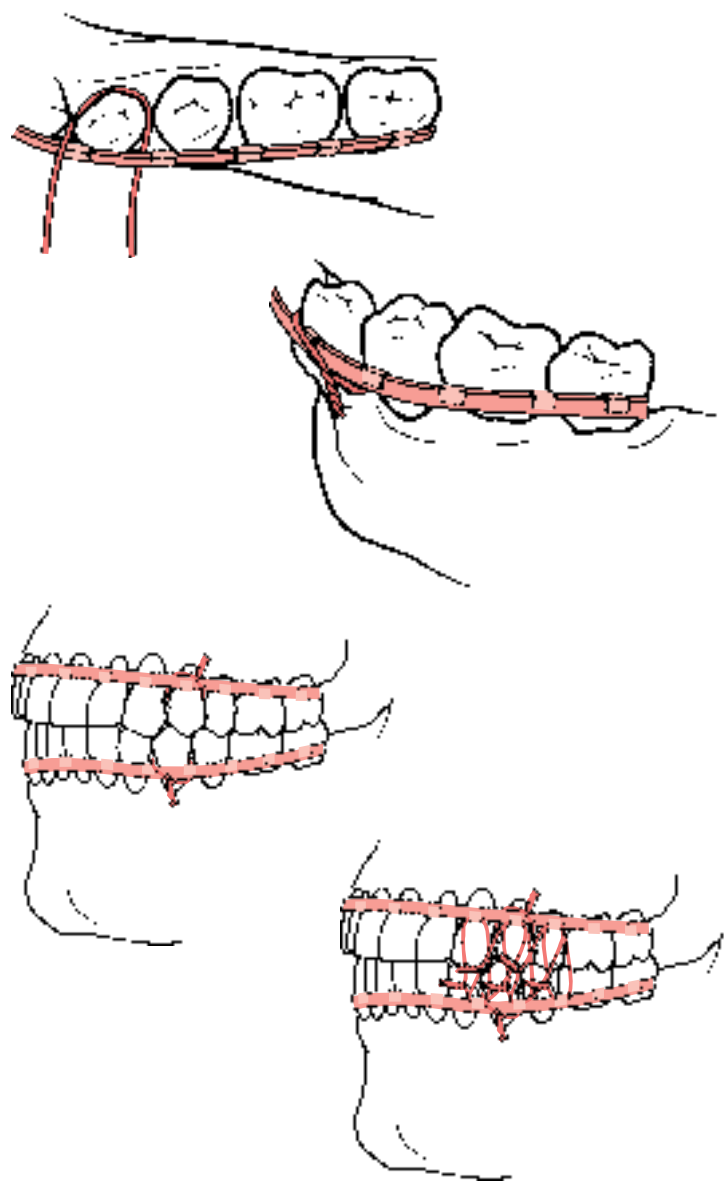


Fig. 5.6 Erich arch bar technique.

patient should be made to rule out other less obvious concomitant injuries. Intracranial, cervical or facial bone injuries often accompany dental trauma and can be overlooked. Although dental trauma is not the first priority for multiply injured patients, successful management of many dental injuries requires proper diagnosis and treatment within a limited period of time.

History and physical examination

A good history is important to determine the nature and time of the injury, the likely dental injuries from that type of trauma, other possible secondary injuries and any pre-existing dental problems (e.g. malocclusion, previous dental trauma). The physical examination should include a rapid, but adequate, general examination as well as detailed head and neck and oral examinations:

- View with suspicion any alteration in dental occlusion from the patient's stated normal as evidence of displaced teeth, dento-alveolar fracture or facial bone fractures.
- Account for all the teeth. Teeth unaccounted for at the scene or on examination should be considered to have been aspirated, swallowed or displaced into the soft tissues or sinuses. Appropriate radiographs (soft tissue neck, PA and lateral skull, chest X-ray and/or flat plate of the abdomen) should be ordered to localize the fragments. Perform a thorough search for any foreign bodies, teeth fragments or debris in the soft tissues of the lips or floor of the mouth. This is a particularly common finding and is associated with a high incidence of infection.
- Perform a careful examination to determine which teeth are traumatized, the presence of mobility, the direction and magnitude of any displacement, presence of crown or root fractures, evidence of pulpal involvement such as bleeding of pulpal tissue and empty sockets. The color of the involved teeth and initial percussion sensitivity should be noted. Pulp testing is of limited value in acute injuries. Differentiate between tooth displacement or fracture and dentoalveolar trauma, where the alveolus itself is also fractured. Grasp the involved ridge between the thumb and forefinger of one hand while grasping an adjacent, unaffected area with the other hand to check relative mobility. There may be mobility of the entire alveolus with teeth intact, one alveolar plate with teeth intact, one or both cortical plates with teeth also mobile within the segment, or just tooth mobility with intact

cortical plates. Examine thoroughly for any mandibular or maxillary fractures.

Radiographic examination

Should include a panoramic radiograph and periapicals of the involved teeth, if possible. In small children, or uncooperative adults, occlusal X-rays are often easier to obtain and are clinically useful. When dental fractures are suspected, a second film from another angle is often useful in diagnosis. When fragments are suspected to be lodged in the lip or floor of the mouth, a soft tissue film (exposure time with KVP turned down to $\frac{1}{4}$ normal) might demonstrate the foreign bodies. For dentoalveolar trauma, examine the radiographs for:

- root fractures
- degree of extrusion or intrusion
- pre-existing periodontal disease
- degree of root development
- dimension and location of pulp chamber and root canals
- alveolar or jaw fractures
- foreign bodies (e.g. tooth fragments) lodged in soft tissues.

Classification and treatment (Fig. 5.7)

Crown infraction, craze line or crack

- Does not involve loss of tooth structure.
- No treatment usually necessary.
- Due to propensity for future fracture, should have continued follow-up.

Uncomplicated crown fracture

- Involves enamel or enamel and dentin only.
- Treatment: ○ Account for missing segment (radiograph of soft tissue may be necessary) ○ Smooth off sharp edges.
- Place temporary glass-ionomer cement/compomer bandage or permanent restoration, depending on depth.
- Follow-up important to monitor pulp and periodontal health.
- The tooth should be pumiced, cleaned, dried and etched. The area should be coated and/or built up with a protective restoration such as unfilled resin. Alternatively, reattach the tooth fragment (if available) using composite resin and dentin bonding agents.

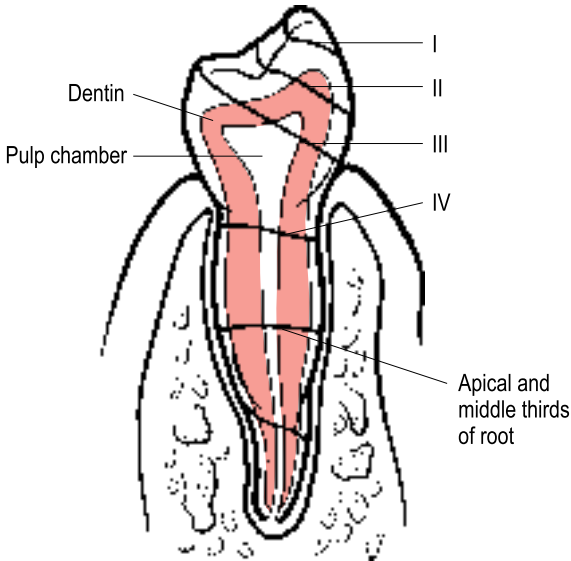


Fig. 5.7 Tooth fracture classification.

Complicated crown fracture

- Involves enamel, dentin and pulp.
- Direct pulp cap: calcium hydroxide (CaOH_2) is placed on exposed pulp tissue if injury is within 24 h and a very small exposure.
- Careful follow-up of pulp vitality and periodontal health.

Complicated crown–root fracture

- Involves enamel, dentin and pulp.
- If perforation of pulp is < 1 mm and less than a few hours old, CaOH_2 can be placed over the exposure and a restoration placed as for a class II fracture.
- If pulpal exposure is larger than 1 mm or more than 24 h old, pulpectomy followed eventually by conventional endodontics.
- With large exposure and open apex, make access to the vital pulp. Amputate 2 mm of pulp and surrounding dentin in teeth fractured from 1 h to 90 days. More amputation might be necessary in the case of a partially necrotic pulp. Direct pressure should be applied to obtain hemostasis and CaOH_2 should be applied directly to the

pulp stump. A composite 'sling' is placed over the CaOH_2 . Copious irrigation should be used. Pulpotomy or pulpectomy of primary teeth can be performed with 5-min application of formocresol for a pulpotomy technique or filling of the root canals, after pulpectomy, with a resorbable paste.

- For primary anterior teeth with a fracture extending into the pulp, a pulpectomy with zinc oxide eugenol is indicated if cooperation is good and provided that there is not significant root resorption, or an extraction if not.

Root fracture

- Fracture apical to the cemento-enamel junction (CEJ) that involves dentin, cementum and pulp.
- If a permanent tooth is injured at or coronal to the crestal bone (e.g. the cervical $\frac{1}{3}$), the coronal portion should be removed and endodontics begun. The endodontic procedure is completed, the restoration is made with a post and core. The root is extruded orthodontically and the crown is fabricated. Alternatively, periodontal surgery may be used for the crown lengthening.
- If the fracture is in the middle $\frac{1}{3}$ of the root, the coronal fragment should be repositioned, if displaced and splinted for 1 month to the adjacent teeth. This allows healing by the formation of calcified tissue, bone, connective tissue or granulation tissue. Pulpectomy and conventional endodontic therapy should be begun within 7–10 days if evidence of pulpal pathology is apparent. Endodontic therapy can be done on the coronal portion only if there is no evidence of periapical pathology. If the fragments are widely displaced or tooth is persistently mobile, extraction should be considered.
- If the fracture is in the apical $\frac{1}{3}$ of the tooth or root, the fragments should be left alone and observed carefully for development of periapical pathology or signs of pulpal necrosis. If the coronal portion is mobile it may need to be removed for patient comfort.
- Fractures of the root in deciduous teeth, with the exception of those in the apical $\frac{1}{3}$, which require only observation, are an indication for extraction. Care must be taken to avoid damage to the developing permanent tooth bud. Small pieces of root can be left behind if their removal would jeopardize the permanent tooth. These injuries should be followed radiographically to confirm resorption of the fragment and eruption of the permanent tooth.

Subluxation

The tooth is in the socket but shows greater than physiologic mobility after trauma.

- If mobility is mild, a soft diet and occlusal adjustment to take the tooth out of occlusion are often sufficient.
- If mobility is moderate to severe, splint to adjacent teeth (one tooth on either side) with non-rigid material (acid-etched composite and thin orthodontic wire or fishing line) for 7–10 days.
- Obtain baseline radiograph, with repeat radiographs at 1, 2, 6 and 12 months post-trauma.
- Perform CaOH_2 pulpectomy if external/internal resorption or periapical pathology develops.
- Observe primary teeth with slight mobility radiographically. If the tooth becomes non-vital, treat with pulpectomy or extraction. For moderate to severe mobility, primary teeth should be extracted.

Intrusion

Tooth is pushed further into the socket following trauma. This means that the tooth may have perforated the buccal or palatal plates, or has perforated the floor of the nose or sinus.

- Observe the tooth for re-eruption, but if this does not occur spontaneously, apply gentle orthodontic traction at the rate of approximately 0.3–1.0 mm per week. Surgical repositioning and splinting may be indicated if there is interference with occlusion.
- With moderate intrusion of tooth with open apices, endodontic therapy may be delayed until loss of vitality is suspected. For fully formed roots, start CaOH_2 pulpectomy within 7–10 days of injury and fill permanently with gutta percha after 6–12 months if resorption is arrested or non-existent.
- Allow primary teeth that are minimally displaced and that do not appear to be involving the permanent tooth to re-erupt spontaneously. Extract the tooth if gingival infection, ankylosis or permanent tooth bud impingement is suspected.

Partial extrusion

The tooth is partially avulsed or otherwise displaced in the socket.

- Digitally manipulate the permanent tooth back into the socket as soon as possible. Place one finger over the apical region to help prevent lateral perforation. Then splint with a non-rigid material such as monofilament nylon or 28-gauge wire to the adjacent

teeth to prevent ankylosis.

- Due to the high probability of pulpal necrosis, perform careful clinical and radiographic evaluation frequently or begin endodontics soon after the injury (7–10 days).
- Extract primary teeth to prevent damage to the permanent tooth and interference with the occlusion.

Avulsion

The tooth has been totally displaced out of the socket. This is a true dental emergency because the treatment and prognosis are extremely time dependent. The success of reimplantation is inversely related to the storage material and the time the tooth is out of the mouth. Teeth reimplanted within 30 min have a good chance of surviving, whereas those reimplanted after 2 or more hours have a more limited survival. The goals of reimplanting teeth are to maintain the viability of periodontal ligament cells and impede resorption of the tooth. Milk, or contact lens solution in an emergency, are satisfactory storage media if the tooth cannot be stored in the patient's buccal sulcus.

- If dirty, the tooth should be grasped by the crown and rinsed gently in saline, tap water or milk at the scene of the injury. Do not scrub off, brush the tooth or handle the root.
- Immediately place the tooth back in the socket and hold in place with light pressure en route to the treating facility. There is no need to physically debride the socket prior to replacement. Gentle saline irrigation will remove debris.
- If the tooth cannot be replaced at the scene, it should be stored in the buccal vestibule or floor of the mouth for transport. If this is not possible, the tooth should be stored in a cup with the Hanks Balanced Salt Solution (HBSS), the patient's saliva, milk, saline or water. Do not wrap tooth in tissue, towel or foil or allowed to dry out.
- Once the tooth is reimplanted in a gently saline-irrigated socket, splint it to the adjacent teeth with a non-rigid or semi-rigid splint for 7–10 days. If a concomitant alveolar fracture is present, maintain the splint for 2–8 weeks. Longer splinting periods are required for more extensive fractures.
- In a permanent tooth with an open apex that has been replanted 2 h after avulsion, radiographs and clinical exam should be

performed in 3–4 weeks to look for evidence of pulpal pathology versus revitalization. If pathosis is noted, root canal therapy should be instituted immediately. The canal should be cleaned and filled with CaOH_2 until apexification has occurred (usually 6–24 months). Then obturation with gutta percha is indicated.

- For a permanent tooth with a partially to completely closed apex and less than 2 h dry time, the pulp should be removed in 7–14 days. The canal is cleaned and CaOH_2 is placed. The new American Association of Endodontics guidelines recommend only 7–14 days of CaOH_2 treatment and immediate obturation of the canal with gutta percha and sealer. These new recommendations to obturate a tooth so quickly after trauma are controversial.
- For permanent teeth with partially to completely closed apices and greater than 2 h extraoral time, root canal therapy can be performed immediately. These teeth will eventually be lost to resorption but may be retained short term and are likely to ankylose. The tooth, once the canal has been extirpated extra-orally can be soaked in sodium fluoride solution to discourage resorption once reimplanted.
- Do not replant primary teeth.
- Consider tetanus prophylaxis and antibiotics (penicillin VK 500 mg QID, clindamycin 150–300 mg QID or erythromycin 250 mg QID) for 7–10 days and place the patient on a soft diet.

Mandibular trauma (Fig. 5.8)

Condylar (intracapsular)

Fractures that occur high on the condylar head (< 8–10 mm from the articular surface). Usually caused by injuries to the symphyseal region (especially bilateral condylar fractures) or contralateral body region. Because the condylar head is a growth site of the mandible, the primary concern for this fracture is eventual ankylosis, especially in children. Treatment is usually confined to careful observation and maintenance of mandibular function to prevent ankylosis.

Subcondylar or condylar (extracapsular)

Fractures that occur below the attachment of the TMJ capsule. The etiology is the same as for intracapsular fractures. Treatment is dependent on the degree of displacement and dysfunction. If the occlusion is normal and there is no deviation upon opening, obser-

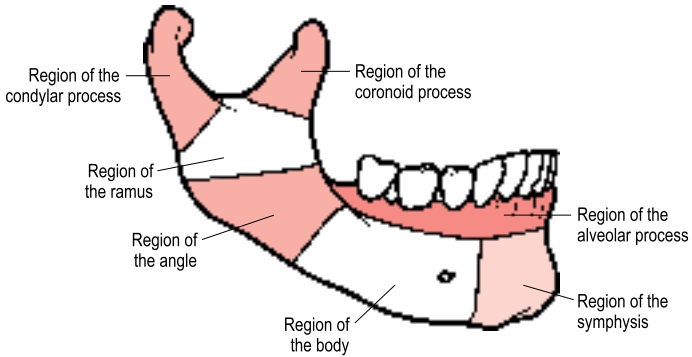


Fig. 5.8 Regions of mandibular trauma.

vation is adequate. If dysfunction is moderate, use Ivy loops with guiding elastics for 2 weeks. Open reduction is indicated if there is a foreign body in the joint, displacement laterally or into the middle cranial fossa, or if bilateral and associated with comminuted mid-facial fractures.

Coronoid

Fractures of the coronoid process are rare. They are caused by a direct blow to the area when the mouth is in the open position which brings the coronoid below the zygomatic arch. Treatment is usually unnecessary except for associated fractures.

Ramus

Fractures below the condylar neck but above the angle region. The etiology is usually a direct blow to the ramus (often seen with bullet wounds). They may be simple, but are often comminuted. Simple horizontal fractures require only short-term IMF. Displaced fractures require open reduction.

Angle and body

Fractures of the angle region (e.g. distal to the second molar but below the ascending ramus) are very common. They are usually caused by direct injury. Treatment is usually open reduction and fixation with miniplates but the use of IMF versus miniplates varies in different clinical settings and in different geographic locations.

Parasympysis

The area between the mandibular canines (the symphysis is the midline between the central incisors). Caused by direct injury. Treatment is complicated by muscle effects and, therefore, displaced fractures require either open reduction or closed reduction with a lingual splint to prevent splaying of the inferior border when IMF is applied. Non-displaced and non-mobile fractures can be managed with IMF alone for 4–6 weeks.

Midface trauma

Although isolated midfacial and LeFort injuries do occur, it is common to see multiple fractures that may involve several levels (Fig. 5.9).

LeFort 1

The entire alveolar process of the maxilla up to the floor of the nose, extending from the anterior nasal spine to the pterygoid plates, is fractured in a horizontal manner. If minimal or non-mobile, IMF may suffice as treatment. If mobile, open reduction or suspension wiring in addition to IMF is warranted.

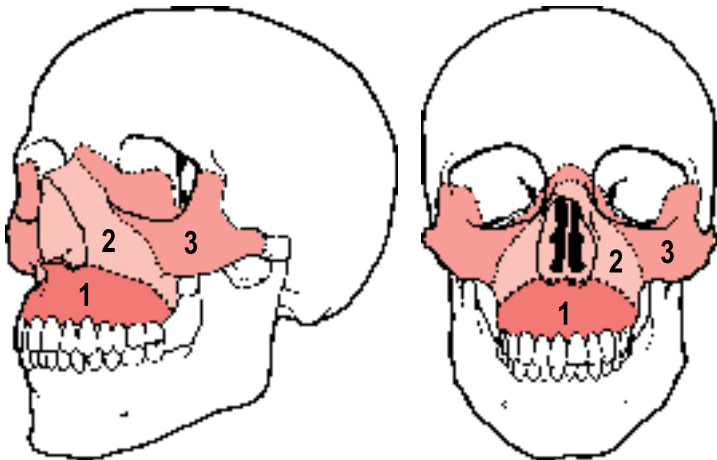


Fig. 5.9 LeFort midface fractures.

LeFort 2

Also called a 'pyramidal fracture' because of its triangular shape, this fracture crosses the maxilla obliquely from the pterygoid plates to the frontonasal area bilaterally. Thus, the maxilla moves at the level of the nasal bridge and infraorbital regions (zygomatico-maxillary suture). If displaced, treatment is open reduction.

LeFort 3

Also called 'craniofacial dysjunction' because of the separation of the midfacial bones from the skull. Begins at the pterygoid plates and involves the lateral orbital rim (frontozygomatic suture), zygomatic arch (zygomatico-maxillary suture), the orbital floor and the frontonasal areas bilaterally. Thus, the entire face will move under the skull at the level of the orbits. Treatment requires open reduction.

Zygomatic arch

Often fractures from a direct blow. Fractures usually occur at the junction of the temporal process of the zygoma and the zygomatic process of the temporal bone. This can create the classic 'W' fracture. Fracture of the zygoma proper will also involve this region but is usually linear and does not produce the 'W'. Treatment usually involves popping the fractured arch out with a long flat instrument via an intraoral or extraoral hairline (Gillie's) incision.

Zygoma

Also called a 'tripod' fracture because of its three clinically evident suture fracture lines (fronto-zygomatic, temporozygomatic and zygomatico-maxillary). Results from a direct blow. The clinical findings are of great importance and include:

- periorbital edema and ecchymosis
- subconjunctival hemorrhage and ecchymosis
- occasional entrapment of muscles with subsequent restriction of movement and diplopia
- occasional displacement of Whitnall's tubercle and the lateral canthus. Treatment begins with an ophthalmologic examination and, if displaced, usually requires open reduction.

Soft tissue wounds

Oral and facial lacerations are a common presentation in the emergency department. Diagnosis and management are usually

simple and uncomplicated, but patience and care are needed to ensure good functional and cosmetic results and avoid or minimize damage to vital structures.

Assessment

Because lacerations indicate some form of traumatic injury, perform a complete evaluation with special emphasis on neurologic or cervical damage. Following this, evaluate for the following:

- Magnitude of the laceration: with or without anesthesia, gently probe the wound. Extensive or complicated wounds may often be better managed in an operating room [theatre] if the tissue damage is great, if extensive debridement is needed or if the patient is not, or cannot be, cooperative.
- Appearance of the wound: irrigate and clean dirty or contaminated wounds thoroughly prior to closure. Particulate matter may require gentle scrubbing for removal. Crushed or non-vital edges should be 'freshened' by sharply excising a small amount of tissue from the margins.
- Time sequence: increased time since the injury may increase complications. Unlike lacerations of other areas of the body, the excellent blood supply of the face and oral cavity allows primary closure many hours after injury. In such cases, conservative debridement of the wound margins can often produce a more cosmetic result. In addition, high-velocity wounds (such as a shotgun injury) often undergo delayed tissue necrosis. It is sometimes wise to clean and debride the wound initially and close it a few days later when the extent of tissue necrosis can be better assessed. If closure must be delayed, the wound should be grossly debrided, irrigated and dressed with saline-soaked sponges.
- Damage to vital structures: examine for cranial nerve injury (especially branches of the facial nerve). If the ends of the nerve can be located but not primarily repaired, gently tag with a non-resorbable suture for later identification and grafting. Parotid duct injuries may be seen by direct visualization or by injecting 1 cc of $1/2$ -strength methylene blue through a 20-gauge catheter passed into Stenson's duct. Dye-filling the wound indicates ductal injury and requires correction and stenting. Tamponade large bleeding vessels until they can be isolated and ligated under proper and optimal conditions (never probe a bleeding wound

with a hemostat searching for a bleeder – you will just as likely grab an adjacent vital structure).

- Cosmetic considerations: carefully evaluate large, jagged wounds that cross flexion creases or traverse critical anatomy (such as the vermilion border or eyelid).

Treatment

Closure may require alteration of the wound (e.g. Z-plasty) and, if extensive, may be better performed in the operating room [theatre] under general anesthesia.

Anesthesia

If local anesthesia is to be used, this should be undertaken first with an anesthetic that is lasting and profound to accomplish good cosmetic and functional results. Lidocaine 2% with 1:100 000 [1:80 000] epinephrine is usually an excellent choice with the exception of the tip of the nose and the pinna of the ear, where caution must be exercised not to cause tissue necrosis secondary to the vasoconstrictor. A sterile dental syringe or a standard 3–5 cc Luer lock and 25-gauge needle can be used to obtain a block injection, infiltration or ring injection. Infiltrations may be performed either by injecting through the skin parallel and adjacent to the wound, or directly into the wound margins. It is usually best to insert the needle and then inject on the way out.

Preparation

When adequate anesthesia has been achieved, remove any obvious, large foreign bodies (e.g. big pieces of glass). Irrigate with large volumes of saline, lactated Ringer's or an antibiotic solution (but not sterile water because of its hypotonicity). The choice of solution is not as important as the volume (250 cc to 1 L, depending on the site of the wound) and the pressure used. Use a 50-cc syringe and an IV catheter (without the needle) placed directly into the wound. A pressure irrigator or water-jet lavage is particularly useful for grossly contaminated wounds. Next, clean the wounds with a surgical soap and irrigate again. Paint the wound with povidone-iodine for an area around the margins of at least 5 cm. Place sterile towels (four, placed in a square fashion or a round hole cut into a disposable paper towel drape) to isolate the wound within the prepped area.

Hemostasis

The initial management for all heavy bleeding should be pressure with sterile gauze until the wound can be examined carefully under sterile, well-lit, well-equipped (e.g. suction available) conditions. Injudicious attempts at clamping vessels prior to this often leads to inadvertent damage to adjacent important structures. Large venous or arterial bleeders may be clamped with a mosquito hemostat and ligated (e.g. 4-0 chromic suture) or electrocoagulated. Intermittent packing of the wound for 5 min with moist gauze will help control profuse bleeding.

Debridement

Examine the wound carefully for any remaining dirt or foreign bodies. Excise any devitalized or necrotic soft or hard tissue. Remember, however, that the excellent blood supply of the face mandates that debridement be conservative. Remove only tissue that is obviously ischemic or necrotic. Also at this time, probe the wound to determine the extent of the injury and look for any unexpected findings such as:

- fractures of the underlying bones
- parotid or submandibular duct transection
- nerve injuries
- cartilage involvement in the ear and nose
- tissue avulsion
- injuries to the canalicular or nasolacrimal system, globe, medial or lateral canthal ligaments, or lacerations that penetrate the tarsal plate of the eyelid.

Abrasions and injuries resulting from being dragged along the ground require special treatment. After thorough examination for embedded foreign bodies, carefully scrub the wound using a soft brush (an operating room scrub brush/sponge works well) and a mild surgical soap solution. Remove all particles from the wound, regardless of size, to obtain good, long-term, cosmetic results.

Primary repair of lacerations

Choice of suture material. There are two basic types of suture material – resorbable and non-resorbable. Resorbable sutures are used for closure of all tissues below the skin, for ligating small vessels and for mucosal closure. Non-resorbable sutures are used for skin closure, for mucosal closure and for ligating larger vessels.

Sutures can also be monofilament or multifilament. Monofilamentous sutures are not generally as strong as multifilamentous but are less likely to convert contamination to infection by tracking bacteria into the wound (see Chapter 8). The choice of suture is based on:

- location of laceration
- desired time for tensile strength
- ability and availability of suture removal.

The choice of suture needle. Four aspects of the suture needle that influence selection.

- Shape: three-eighths circle is the most popular. A half circle is easier to use in confined locations.
- Size: diameter should match the suture size.
- Point: cutting or reverse-cutting (the most popular), which are triangular in cross-section, are used in tough tissue (skin and mucosa). Taper-point needles are used in easily penetrated tissue.
- Method of attachment: swagged needles are the most common in use but controlled-release (or pop-off) needles can be used for single stitches when easy removal of the needle from the operating environment is desired.

Choice of suture technique.

- Simple deep suture: used to close deep layers below the skin or mucosa. This is a simple, interrupted, resorbable suture such as Vicryl, Dexon or gut (Fig. 5.10).
- Inverted simple suture: placed so that the knot is deep to the loop of the suture. It is used to close the subcutaneous tissues so that the knot does not protrude through the wound. This closure is carried out just prior to skin or mucosal closure and is of great importance in obtaining a cosmetic closure (Fig. 5.11).
- Running subcuticular suture: a continuous suture placed in a horizontal fashion just below the epidermis. The ends are carried through the skin just beyond the extent of the wound and either taped down or tied to themselves. This can be used as the final closure if skin sutures are not desired (Fig. 5.12).
- Simple interrupted skin suture: used to close the skin or mucosa. Has the advantage that if an infection ensues, one or two sutures can be removed to allow placement of a drain without dehiscing the entire wound (Fig. 5.13).
- Vertical mattress suture: placed so that there is a deep loop and a superficial loop that everts the skin edge. Most useful when

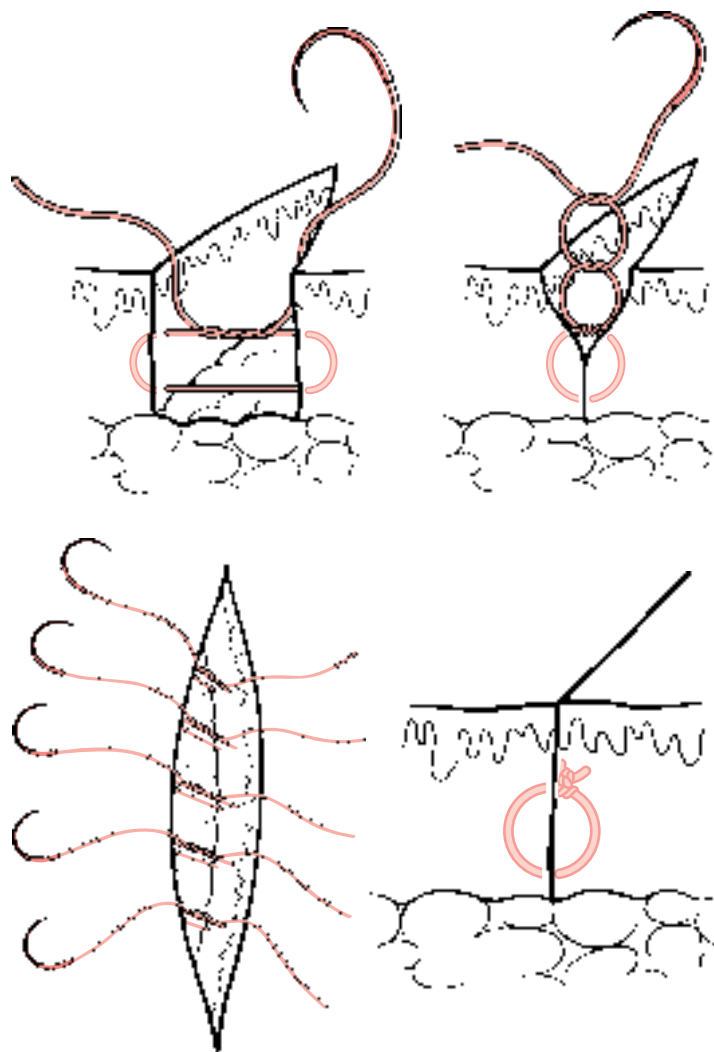


Fig. 5.10 Simple, deep suture.

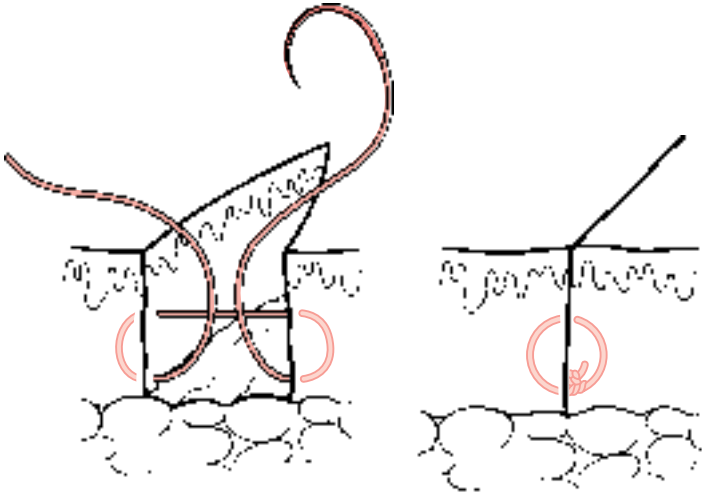


Fig. 5.11 Inverted simple suture.

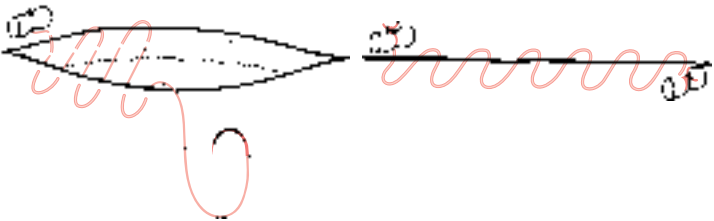


Fig. 5.12 Running subcuticular suture.

eversion of skin edges is mandated or for single layer closure of large amounts of tissue (e.g. scalp lacerations) (Fig. 5.14).

- Running epithelial suture: a continuous skin suture used to obtain rapid final closure of the wound edges. Sometimes also called a 'baseball stitch', this technique works well on straight line wounds but is difficult with angled or curved wounds (Figure 5.15).

Standard closure technique for facial lacerations.

- Close deep layers (e.g. periosteum, deep fascia) with resorbable suture (e.g. 3-0 Vicryl, Dexon or chromic gut) using a simple deep

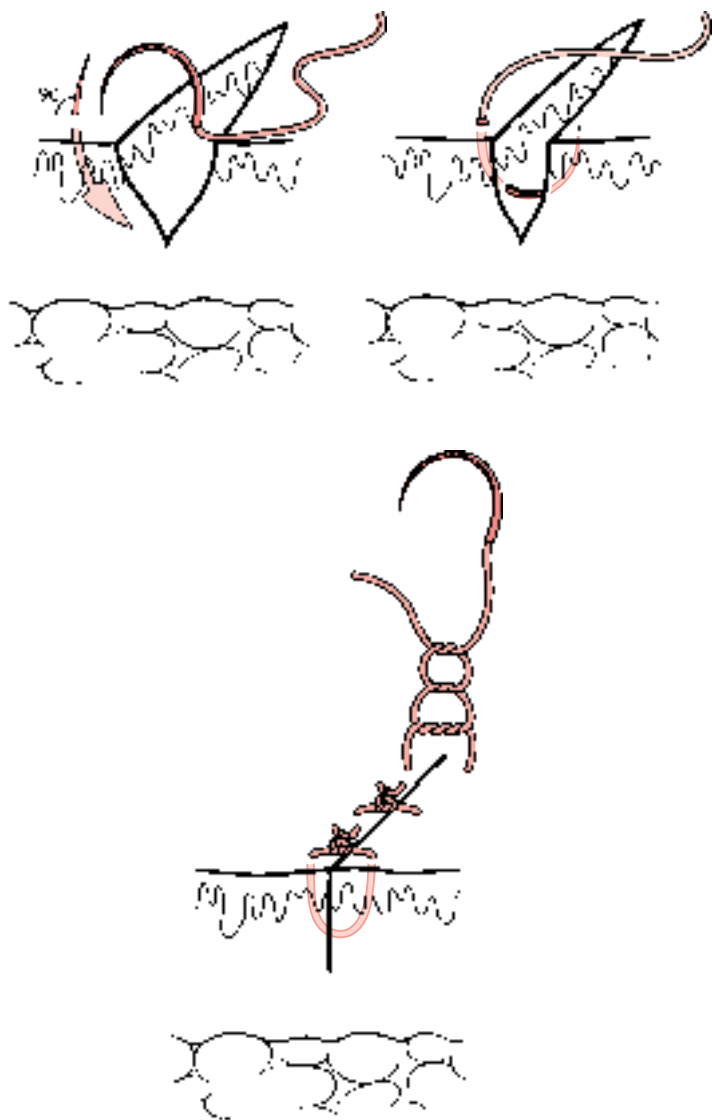


Fig. 5.13 Simple interrupted skin suture.

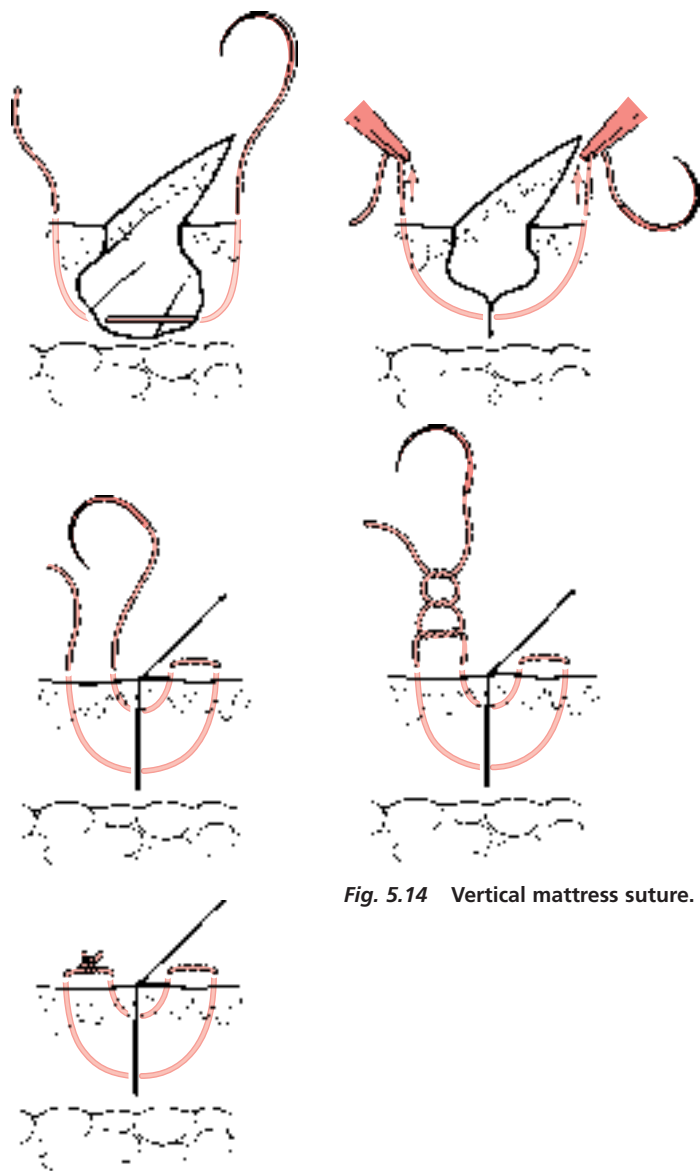


Fig. 5.14 Vertical mattress suture.

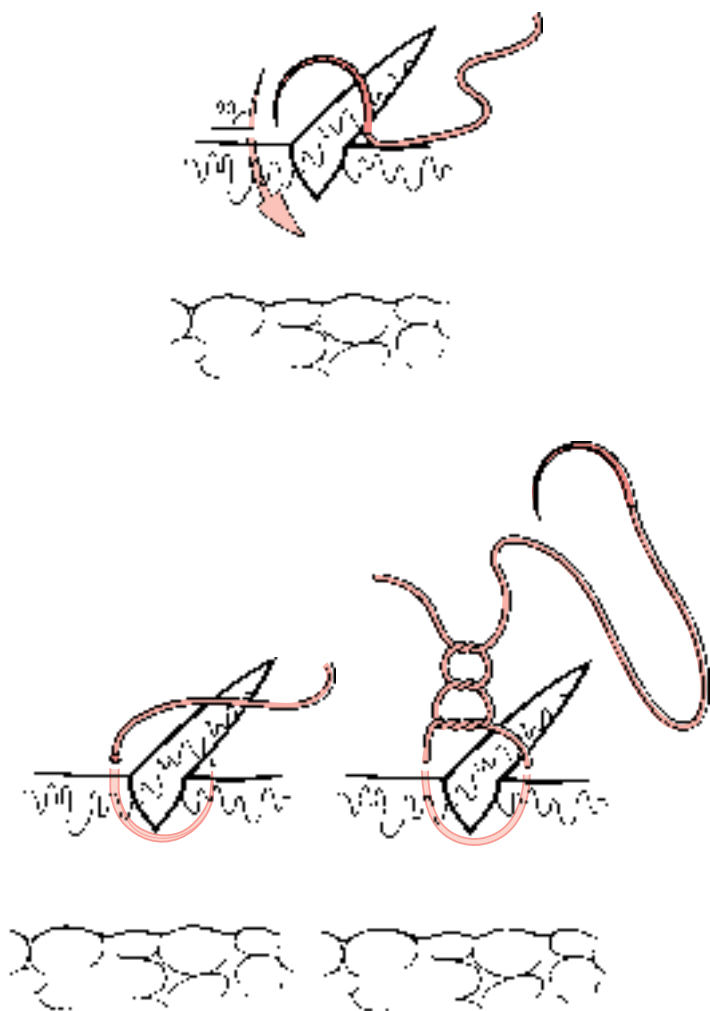


Fig. 5.15 Running epithelial suture.

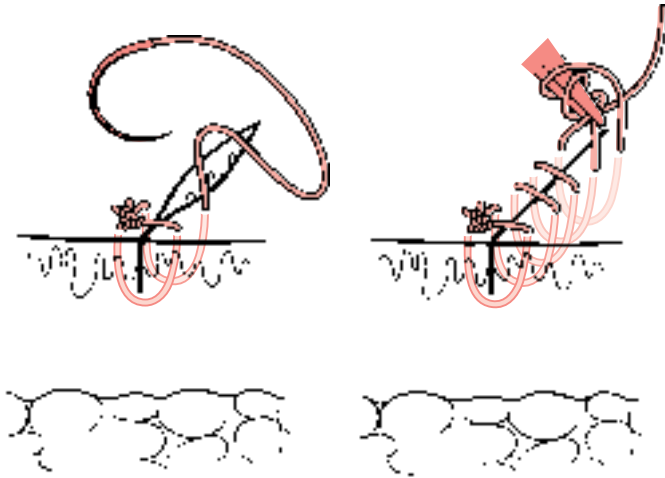


Fig. 5.15 Running epithelial suture (*continued*).

interrupted suture. Close muscle by suturing together the fascia layer enveloping the muscle. Eliminate all dead space in layers to prevent hematoma formation (Fig. 5.16).

- Close the subcutaneous layer with a resorbable suture as above but using an inverted simple suture. After tying the knot, pull the knot to one side to place it deep to the suture loop and thus out of the wound margin. The long-term strength of the closure is based on this layer of closure and it is, therefore, imperative to obtain excellent approximation of this layer. A suture that will retain its tensile strength for at least 21 days is also important.
- Close the skin at this point with a running subcuticular suture (e.g. 5-0 non-resorbable suture such as Prolene), a running skin suture (usually 5-0 or 6-0 nylon) or multiple simple interrupted or inverted mattress skin sutures (usually 5-0 or 6-0 nylon). This choice is based on personal preference, except for scalp lacerations, where a 4-0 nylon or Prolene inverted mattress suture is preferred because it will engage the galea layer of the scalp, thereby providing additional strength to the wound closure.

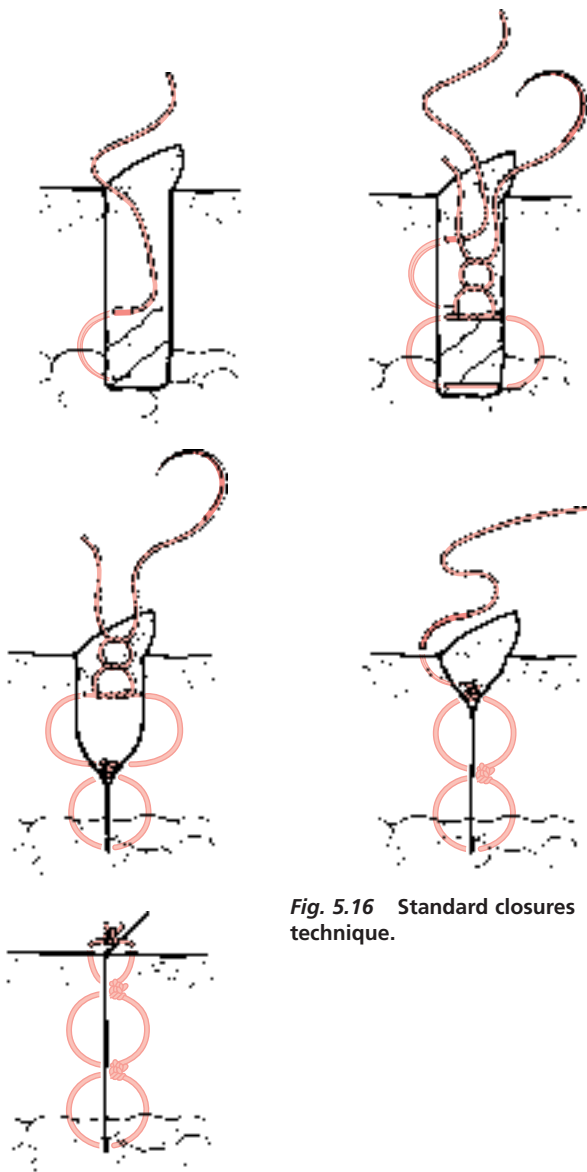


Fig. 5.16 Standard closures technique.

Standard mucosal closure technique.

- Close deeper layers (e.g. periosteum and deep fascia) with resorbable sutures as for the skin closure.
- There is usually no need for submucosal closure in the oral cavity.
- Close mucosa with either a non-resorbable suture (e.g. 3-0 or 4-0 silk or 5-0 nylon) or a resorbable suture (3-0 or 4-0 plain gut, chromic gut, Vicryl or Dexon).

Standard 'through and through' (mucosal-epidermal) closure.

- After initial irrigation as usual, close the intraoral mucosa in routine fashion. A watertight closure should be obtained, if possible.
- Then copiously irrigate the wound again from the extraoral side and prep in the standard sterile fashion for a skin closure.
- Close the deep layers and skin as for a normal skin closure.

Unusual circumstances.

- When closing around lacerated cartilage (e.g. nose or ears), close the tissue deep and superficial to the cartilage to approximate the cartilage, if possible. This is because of the lack of blood supply and therefore healing capacity of cartilage. If absolutely necessary, a few small tacking sutures may be placed in the cartilage to hold the shape of the anatomical area.
- Scalp wounds bleed profusely but will stop quickly once the galea is approximated. This can be done easily by using deep-bite vertical mattress sutures. Staples are very popular for scalp lacerations, especially for children.
- Avoid using electrocoagulation when suturing hair-borne areas (e.g. eyelid, scalp) because this will cause loss of hair follicles. Any incisions made to freshen the edges of the wound should be made very conservatively and along the long axis of the hair follicles (e.g. not necessarily perpendicular to the wound margin) to prevent loss of the follicle.
- Never shave around the eyebrows to better visualize a laceration. Eyebrows do not always grow back!
- Always approximate important anatomical structures first (e.g. eyebrow, commissure or vermillion border of lip). This should be done with tacking sutures even prior to subcutaneous closure to allow for proper alignment.
- Other than scalps and eyebrows, convert beveled wounds to perpendicular margins to avoid raised areas after healing.

- With jagged wounds it is usually better to convert the wounds to several linear portions by conservative excision.
- To obtain primary closure without tension, the wound may be undermined by piercing the deep subcutaneous tissue with a sharp scissor and then opening them as the instrument is withdrawn from the wound. Separation of these layers allows the skin to “slide” on the underlying tissues and aids in easy closure.

Postoperative care.

- Wound dressing: wipe the wound with a saline soaked gauze after final suturing to remove any residual blood, suture material, or iodine. Place a thin layer of an antibiotic ointment on the suture line and cover it with a non-sticky dressing (e.g. Telfa, Xeroform, Melolin). Intraoral wounds require no special dressing.
- Leave skin wounds alone for 48 h. Following this, they should be cleaned gently twice daily with warm water and soap or hydrogen peroxide to remove any crusted blood or other debris. It is important to remove dried blood and debris around the sutures. Follow this with another layer of antibiotic ointment. Rinse intraoral wounds with saline several times per day.
- Antibiotic coverage: as with all infections, the choice of antibiotic therapy should be guided by culture and sensitivity testing. Prophylactic coverage for dirty lacerations, however, may be initiated with the following:
 - Deep or dirty skin wounds: staphylococcal coverage is warranted and provided by either dicloxacillin (500 mg QID) or a cephalosporin (e.g. Keflex 500 mg QID) for 7 days.
 - Intraoral wounds: penicillin VK 500 mg QID or, if penicillin allergic, erythromycin 500 mg QID for 7 days. Older or infected wounds are often colonized by anaerobic organisms and are sometimes better treated by adding metronidazole 200–500 mg tds or QID to the penicillin or switching to clindamycin 150–300 mg QID.
- Tetanus prophylaxis: consider any patient with a laceration of traumatic origin for antitetanus therapy:
 - If clean wound and patient has had initial immunization as a child: give tetanus toxoid booster (0.5 cc IM) if no booster injection within last 10 years.
 - If contaminated or dirty wound and patient has been initially immunized: give tetanus toxoid booster if no booster injection within last 5 years.

- If patient has not had initial immunization: give toxoid booster (should continue this at 1, 2 and 6 months for immunization) and give 250 U of tetanus immune globulin IM in opposite deltoid muscle.
- Suture removal:
 - Remove intraoral, non-resorbable sutures or resorbable sutures that are uncomfortable 5–9 days after placement.
 - Skin sutures: these should be removed at different times depending on the thickness of the tissue, type of closure and degree of tissue tension.

In general, nylon facial sutures are removed at 4–6 days. Nylon sutures in the eyelids, ears, nose or other thin tissue should be removed at 3–5 days. Running subcuticular sutures may be left an additional day or two without consequence.

TEMPOROMANDIBULAR JOINT (TMJ) EMERGENCIES

True TMJ emergencies are rare. The most common emergency is condylar trauma, which is covered on p. 242.

Acute condylar dislocation

History

- Sudden inability to close the mouth.
- Precipitating event is usually wide mouth opening, as during a yawn or trauma.
- Can be unilateral or bilateral.
- Often has history of chronic recurrence.
- May or may not be painful.

Examination and diagnosis

- Anterior open bite, which may be asymmetrical if unilateral.
- Panoramic or lateral oblique of mandible shows condyle(s) significantly anterior and superior to eminence.

Treatment

- Stand in front of the patient. Place thumbs bilaterally along external oblique ridges (Fig. 5.17).
- Gently, traction the mandible inferiorly first, then posterior–superiorly until condyle sits in condylar fossa.

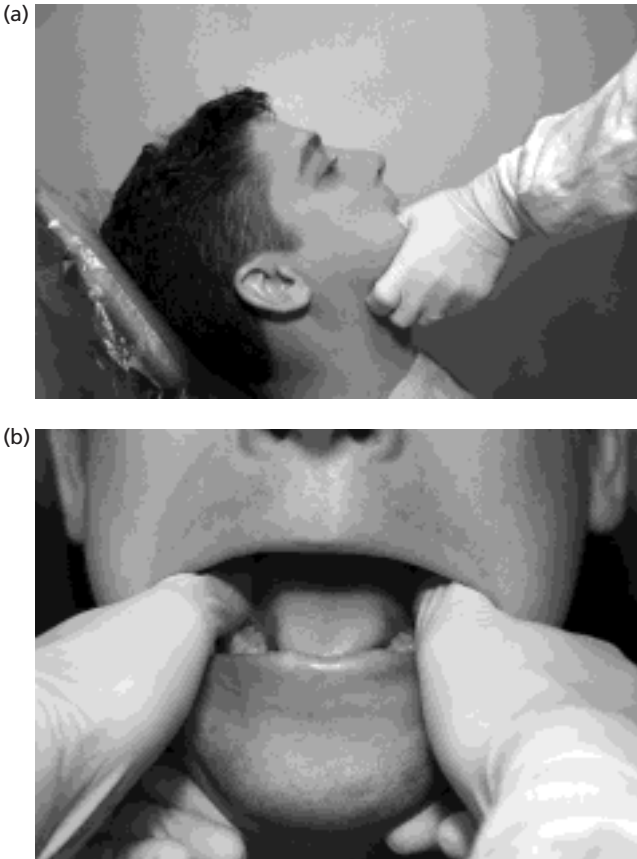


Fig. 5.17 (a) Stand in front of the patient, whose head is against the headrest; (b) place thumbs on the oblique ridges to avoid rapid closure of the teeth against the thumbs.

- If bilateral, do each side separately.
- If unable to reduce, consider injecting 1–2 cc lidocaine without vasoconstrictor near lateral pterygoid muscle to break spasm or premedicating the patient with 2–5 mg of diazepam before trying again.
- Limit function and wide opening of the jaw for 2 weeks.

Acute myofascial pain

History

- Acute but diffuse pain in muscles of face, neck and head.
- Limitation of mandibular motion.
- Difficulty eating.
- Often related to acute stress.

Diagnosis

- No radiographic evidence of joint pathology.
- Pattern of diffuse, non-localized pain
- Pain on masticatory muscle palpation.
- May see mandibular deviation on opening.

Treatment

Generally aimed at breaking muscle spasm, stress reduction and acute pain relief:

- anti-inflammatory agents (e.g. ibuprofen 600 mg QID)
- warm compresses to face 6–8 times per day
- soft non-chewy diet
- consider muscle relaxants (e.g. diazepam 5 mg BID)
- stress reduction
- consider 1–1.5 cc lidocaine without vasoconstrictor injected into trigger areas.

Traumatic hemarthrosis

History

- Recent trauma to mandible.
- Limitation of opening.
- Acute joint pain.
- Patient complains of ‘bite’ being off.

Diagnosis

- Acute open bite malocclusion on affected side.
- May have swelling in joint region.
- No radiographic evidence of fracture.
- May see increased articular space on radiograph.

Treatment

- Soft diet.
- Ice to the area for first 24 h, then warm compresses 6–8 times per day.
- Anti-inflammatory agents.
- Reassurance and observation for improvement.