

See discussions, stats, and author profiles for this publication at: <https://www.researchgate.net/publication/51168414>

Considerations of maxillary tuberosity fractures during extraction of upper molars: A literature review

Article in *Dental Traumatology* · May 2011

DOI: 10.1111/j.1600-9657.2011.01012.x · Source: PubMed

CITATIONS

13

READS

7,703

2 authors:



Bruno Chrcanovic

Malmö University

167 PUBLICATIONS 2,902 CITATIONS

[SEE PROFILE](#)



Belini freire-maia

Pontifícia Universidade Católica de Minas Gerais

37 PUBLICATIONS 483 CITATIONS

[SEE PROFILE](#)

Some of the authors of this publication are also working on these related projects:



Nanostructured materials for biomedical applications [View project](#)



Maxillofacial trauma [View project](#)

Considerations of maxillary tuberosity fractures during extraction of upper molars: a literature review

REVIEW ARTICLE

Bruno Ramos Chrcanovic, Belini Freire-Maia

Department of Oral and Maxillofacial Surgery,
School of Dentistry, Pontifícia Universidade
Católica de Minas Gerais, Belo Horizonte,
Brazil

Correspondence to: Bruno Ramos
Chrcanovic, Av. Raja Gabaglia 1000/1209,
Gutierrez, Belo Horizonte, Minas Gerais
CEP 30441-070, Brazil
Tel.: +55 31 32920997
Fax: +55 31 25151579
e-mail: brunochrcanovic@hotmail.com
Accepted 14 April, 2011

Abstract – *Background:* Maxillary tuberosity fractures during molar teeth extraction commonly occur in dental practice; however, very few cases have been reported and discussed in the literature. A correct preoperative radiographic interpretation, coupled with the anatomical knowledge of the structures involved, is essential to prevent such complications. *Aim:* The purpose of this paper is to enumerate the predisposing and etiological factors of maxillary tuberosity fractures during the extraction of upper molars, discuss the procedures that need to be taken when small or large fractured fragments of the tuberosity are evident during surgery, and suggest appropriate recommendations. This study is based on a thorough literature review.

Conclusions: Upon discovering that a maxillary tuberosity has fractured, the dentist must first halt the procedure before inadvertent laceration of the adjoining soft tissue occurs and then determine the extent of the fracture by palpating the mobile fragment. After performing the dissection of the soft tissues, immediate removal of the small fractures, including the tooth with small bony fragments, may be the best option, because of the difficulty incurred when attempting to retain the bone. When a large bony fragment is present, it is recommended (i) that the extraction be abandoned and surgical removal of the tooth be performed using root sectioning, (ii) that the dentist tries to detach the fractured tuberosity from the roots, or (iii) that the dentist stabilizes the mobile part(s) of the bone by means of a rigid fixation technique for 4–6 weeks and, at a future moment, attempts a surgical removal without the use of a forceps.

Occasionally, during the course of maxillary molar extraction, the maxillary tuberosity may be fractured and may seem to be loosening when grasped by the forceps. The operator is then confronted with the problem of whether or not to proceed with the extraction (1).

The incidence of tuberosity fracture during upper molar extraction is relatively low. In a study conducted to investigate and compare the prevalence of complications of 8455 simple tooth extractions, 0.15% of the complications proved to be tuberosity fractures (2). In a retrospective study conducted to analyze pre- and postoperative complications associated with third molar extraction, the most frequent complications included the tuberosity fracture and the bucco-sinus communication within the maxilla (3), as compared to only 0.08% of tuberosity fracture in similar study (4).

Fracture of the alveolar process can be seen during tooth extractions. These fractures occur most often in the anterior or premolar regions of jaws in youth and adults (5). When the maxillary sinus is enlarged between the roots of upper molars and the maxillary tuberosity, these types of fractures can be seen during upper molar

extraction. Such a complication may lead to oroantral fistula (6) or serious infection, which may result in maxillary necrosis or deafness (7).

The extraction of a tooth requires that the surrounding alveolar bone be expanded to allow an unimpeded pathway for tooth removal. However, in general, the small bone parts are removed with the tooth rather than being expanded (1, 8, 9). Fracture of a large portion of the bone in the maxillary tuberosity area is a situation of special concern. Maxillary tuberosity is especially important for the stability of maxillary dentures (8). Large fractures of the maxillary tuberosity should be viewed as severe complications. The major therapeutic goal of management is to salvage the fractured bone by maintaining it in place and to provide the best possible environment for healing.

The aim of this paper is to enumerate the predisposing and etiological factors of maxillary tuberosity fractures during upper molar extractions, suggest appropriate recommendations, and discuss the procedures that need to be taken when small or large fractured fragments of the tuberosity become evident during surgery.

Literature review

The floor of the maxillary sinus extends either between adjacent teeth or between individual roots in approximately half of the population (10), creating elevations in the antral surface (commonly referred to as 'hillocks') (11) or protrusions of root apices into the sinus. In these cases, the thickness of the sinus floor is markedly reduced. A study (12) performing a computer-based three-dimensional reconstruction to clarify the morphological and clinical characteristics of the maxillary sinus showed that most posterior limits of the maxillary sinus were located within the third molar and maxillary tuberosity areas (94%); the others were located at the maxillary second molar area (6%). These anatomical characteristics favor the 'weakening' of the maxillary tuberosity.

Radiological examinations can also aid in preoperative planning, in an attempt to avoid possible complications. If a preextraction radiograph reveals the presence of a large antrum, sectioning of the tooth and removal of one root at a time would be the appropriate technique to avoid a tuberosity fracture (13). Periapical radiographs are conventional, yet better detailed radiographs and are therefore quite suitable for this means. Moreover, with these radiographs, the structures can be viewed more easily before performing any surgical procedure. Panoramic radiographs in one such study illustrated that the root projection length in the maxillary sinus cavity was found to be, on average, 2.1 times larger than the actual root protrusion length into the sinus in computed tomography (CT) images (14). This result is explained by the bidimensionality of the panoramic radiograph and tends to occur when sinus recesses penetrate the interradicular area. In these cases, the panoramic radiograph will show a significant part of the root projecting into the sinus, whereas the CT will show that only the apical part of the root (48% of the measured projection depth in the panoramic radiograph) (14) penetrates the sinus, while the remainder stays medial/lateral to it. CT and cone-beam CT (CBCT) should take part as an appropriate radiography technique when other radiographic methods are inadequate (15). The CT and CBCT solve the limitations of the panoramic radiograph by providing multiplanar views with uniform low magnification. However, its disadvantages include limited availability, high cost, and higher doses of radiation (16). The radiological examination can also help the dental professional determine the real extension of the fracture and, therefore, the proper treatment in cases of questionable extension of the fracture. Figures 1–3 show radiological evidence of maxillary tuberosity fractures in CT coronal sections, CT axial sections, and three-dimensional tomography, respectively.

Dental anomalies of the maxillary molars may also be contributory, including tooth fusion, tooth isolation, over-eruption, ankylosis, hypercementosis, chronic periapical infection, and widely divergent roots (9). Cohen (1) reported a case of tuberosity fracture that occurred when the extraction of a third molar with five roots was carried out. A chronic apical infection of the affected tooth may result in bone sclerosis and render the

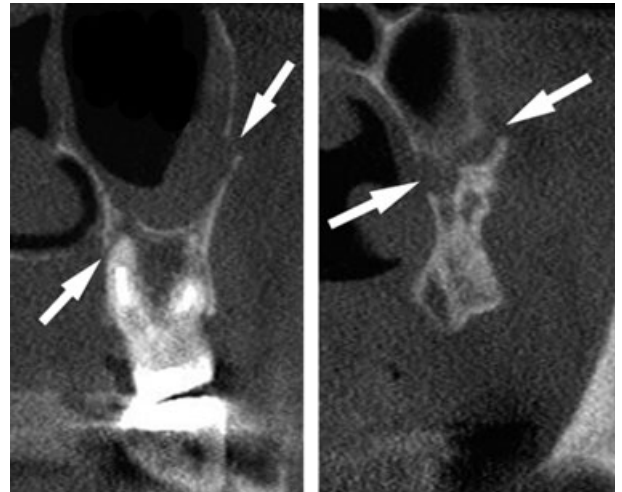


Fig. 1. Computed tomography coronal sections of the maxillary tuberosity region showing evidence of fractures (arrows).

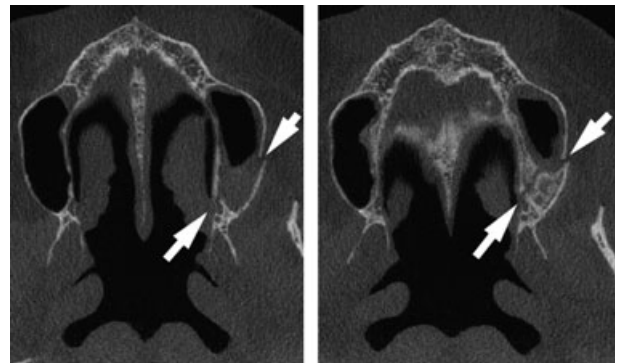


Fig. 2. Evidence of fractures (arrows) in the maxillary tuberosity region in computed tomography axial sections.

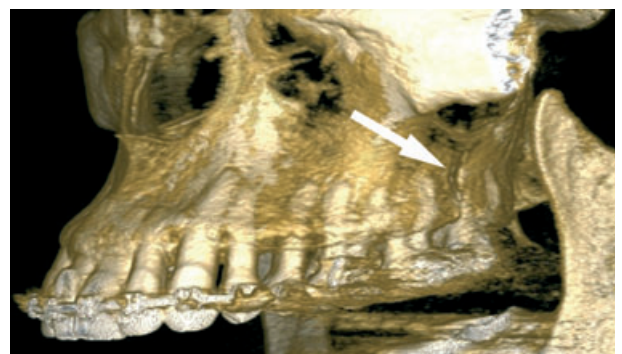


Fig. 3. Three-dimensional tomography showing the line of fracture (arrow).

tuberosity bone more susceptible to fracture (1, 8, 9, 17). In 1962, Burland (18) reported on 30 such cases, in which force was not a factor and where the anatomical characteristics of the tooth and the antrum were the main factors involved. In only three cases was there any evidence of ankylosis.

One study (19) quantitatively evaluated the density of the alveolar and basal bones of the maxilla and the mandible. In the maxilla, the buccal cortical bone density of the alveolar bone in the premolar area proved to be the highest of all measurements of the alveolar bone. Bone density at the maxillary tuberosity was the lowest. Regarding the palatal cortical bone, tuberosity presented the lowest bone density, and no statistically significant difference among the other areas could be observed. In the maxillary basal cortical bone, the highest bone density was evident in the canine and premolar areas, whereas the tuberosity area presented the lowest density. No statistically significant difference in density of the alveolar cancellous bone between the incisor, canine, and premolar areas could be identified; however, the maxillary tuberosity did show a statistically significant low density. For the basal cancellous bone, the bone density at the maxillary tuberosity was lower than that at other sites. Thus, the density at the maxillary tuberosity was lower than that at all other sites. This may make the tuberosity bone better for luxating a tooth, but may also cause a higher susceptibility to fracture under lower applied forces.

In sum, the etiological factors listed in the literature that are responsible for a fractured maxillary tuberosity during upper molar extraction include:

- 1 Large maxillary sinus with thin walls/sinus extension into the maxillary tuberosity and/or large projection lengths of root apices in the sinus cavity (1, 8, 9, 17, 18, 20). Sectioning of the tooth and removal of one root at a time would be the most appropriate technique in these cases (8, 13, 21). It is also important to support the alveolar bone segment of the maxillary molar teeth during extraction with the fingers (20), thus enabling greater stability during bone dislocation;
- 2 Early loss of a maxillary tooth (frequently the first molar) may be followed by a resorption of the alveolar process, bringing the antral lining into close or immediate proximity with the oral mucoperiosteum. This resorption may isolate the second and third molars, and any attempt at extraction may fracture the tuberosity bearing these two teeth (8) (Fig. 4);

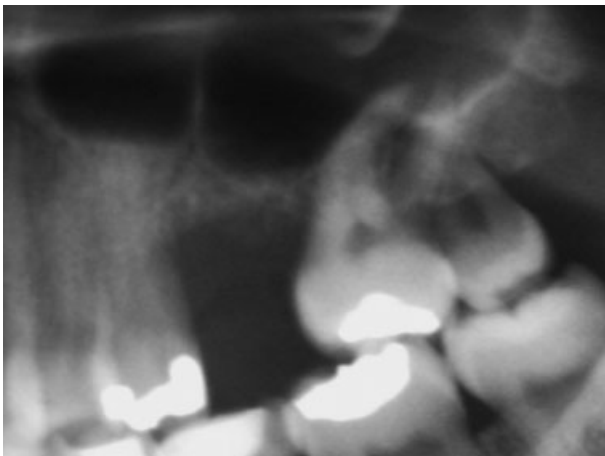


Fig. 4. Alveolar resorption following early loss of first maxillary molar.

- 3 The maxillary third molar may be unerupted and may even be fused to the second molar, creating a further source of weakness in the tuberosity region (8);
- 4 Isolated tooth (9, 13, 20);
- 5 Teeth with large divergent roots (1, 8, 9, 18, 20);
- 6 Teeth with an abnormal number of roots (1, 8, 20);
- 7 Teeth with prominent or curved roots (9, 13, 20);
- 8 Teeth with dental anomalies, such as tooth fusion and over-eruption (9, 13, 20);
- 9 Tooth ankylosis (8, 9, 13, 18);
- 10 Hypercementosis of upper molar teeth (8, 9, 13, 20);
- 11 Chronic periapical infection (1, 8, 9, 13, 17, 20);
- 12 Radicular cyst (9, 13, 20);
- 13 Multiple extractions (8). It is desirable that a correct order be followed in multiple extractions to ensure that the maxillary tuberosity receives maximum support;
- 14 Malpractice by the dentist: inadequate planning related to excessive force during the tooth luxation (8, 20).

The most commonly required radiographs for tooth extractions are periapical and panoramic radiographs. If one of the items listed above appears on these radiographs, it is recommended that the dental professional uses imaging methods that allow for the viewing of structures without overlapping, such as CT or CBCT, so that a better preoperative study can be performed.

It should be emphasized that a referral to an oral surgeon is necessary if such cases are found by general dentists who are not experienced in minor oral surgery, or as soon as they face difficulties, given that a specialist is most likely more comfortable with and more experienced in dealing with the problem (13).

On discovering that a maxillary tuberosity has fractured, the dentist must (i) halt the procedure before inadvertent laceration of the adjoining soft tissues occurs and (ii) determine the extent of the fracture by palpating the mobile fragment (13).

If the fractured tuberosity is small, with only one or two teeth, or if the tooth is infected or symptomatic at the moment of fracture, the fragment must not be left *in situ*. In this case, because of the difficulty in attempting to retain the bone (17, 20), the only available recourse is to remove the molar together with the attached tuberosity (Fig. 5) (8, 9). Some authors believe that the symptoms of the tooth to be extracted will continue or that the fractured complex will not recover because of infection, which commonly sets in after a tuberosity fracture (8, 9).

When a large bony fragment is present (Fig. 6), four procedures can be followed, depending on the experience of the practitioner and the clinical situation.

First, it is recommended that the extraction should be abandoned and surgical removal of the tooth performed by means of root sectioning (20).

Second, the dentist may try to detach the fractured tuberosity from the roots. One frequently stated reason for conserving the fractured tuberosity is that its removal makes later denture reconstruction difficult, although this finding has been questioned in some

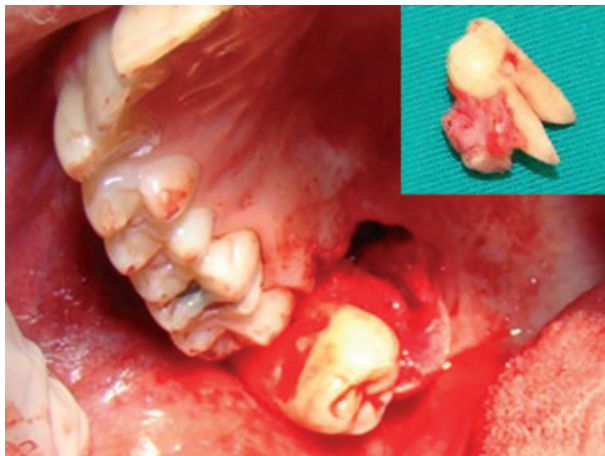


Fig. 5. Removal of the tooth including the small bony fragment of the maxillary tuberosity.

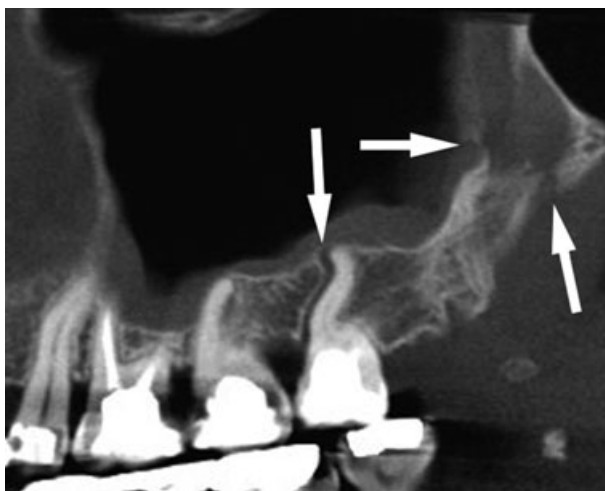


Fig. 6. Radiological (computed tomography) evidence of fractures (arrows) in the maxillary tuberosity region. This is a large fragment.

studies (8). The preservation of the alveolar bone in the maxillary tuberosity area can also provide a better osseous support for later rehabilitation through dental implants.

Attempts to twist or remove the tooth and fractured fragments will tear the mucous membrane (22). Severe tears can lead to sloughing of the tissues and a large oroantral communication (OAC). The greater palatine vessels may also tear, resulting in substantial blood loss. Dissecting out the tooth and the entire tuberosity (22), in an attempt to more accurately understand the extent of the fracture and the chances of saving the fragment, were once common practice. However, by raising a large flap, the operator also runs the risk of stripping the fractured maxillary tuberosity of its blood supply, especially if the underlying bone and the mucoperiosteum of the palate are also torn (13). Ngeow (13) suggested that the tooth to be extracted must be grasped with a pair of molar forceps. In this manner, the fractured tuberosity

fragment is stabilized, and a sharp Coupland periosteal elevator is then inserted into the distobuccal cervical area of the tooth and used to separate the alveolar bone segment from the roots of the tooth. The rationale for this procedure is to keep the remaining bone attached to the periosteum so that it will be continuously perfused and the chance of necrosis will be reduced. The technique also avoids the need to close the OAC with a mucoperiosteal flap. The vascularized bone is then compressed into the sinus communication area (13).

Third, provided that adequate periosteal attachment has been maintained, the dentist may attempt to stabilize the mobile part(s) of the bone using a rigid fixation technique for 4–6 weeks and later try to surgically remove the tooth (or teeth) without the use of a forceps (8, 17). The successful treatment of alveolar fractures is based on proper reduction, the repositioning of the fractured segment, and its satisfactory stabilization. Either closed or open reduction techniques can be used. The segment can be held together by appropriate suturing to allow bone union to take place. The state of the tooth, its dental pulp, and its location in occlusion must also be managed. The tooth may need occlusal grinding to prevent premature contact with the opposing tooth or teeth (23). Attention must be given to any communication established with the maxillary sinus (8). Following adequate healing, the splint is removed, and the tooth is sectioned and delivered. An attempt at forceps extraction would be most imprudent at this juncture and would very likely cause the refracture of the tuberosity (8).

However, if the tooth is infected or symptomatic at the moment of tuberosity fracture, the extraction should be continued by loosening the gingival cuff and removing as little bone as possible while attempting to avoid the separation of the tuberosity from the periosteum. If the attempt to remove the attached bone is unsuccessful and the infected tooth is removed with the attached tuberosity, the tissues should be closed with watertight sutures, as a clinical OAC may not have occurred properly. The surgeon may choose to graft the area after 4–6 weeks of healing and postoperative antibiotic therapy. If the tooth is symptomatic but there is no frank sign of purulence or infection, the surgeon may attempt to use the attached bone as an autogenous graft (24).

Fourth, when a large fragment is already detached from the maxilla, the segment may, in some cases, not be properly repositioned, because primary stabilization may not have been achieved (17). It is commonly advised that if a decision is made to remove the fractured large tuberosity, the soft tissue attachments should be carefully removed from the hard tissue fragment (9). This soft tissue is important for the proper closure of the region to avoid excessive traction of adjacent soft tissues.

When the removal of a large bony fragment is impossible to avoid, some advice must be given to patients. In addition to the usual postextraction instructions, patients must also be advised that they should avoid blowing their nose for 2 weeks to help prevent an oroantral fistula from developing (1, 9, 13). As tuberosity fractures involve the maxillary sinus, antibiotics, nasal decongestants, and anti-inflammatory analgesics should

be prescribed to help prevent the development of maxillary sinusitis. The patient should also be advised not to rinse his mouth forcibly (1). Furthermore, the patient should be made aware that slight bleeding from the nostril on the affected side for one or 2 days is a common side effect (1). For a short postoperative period, the maxillary sinus of the affected side will show an increased radiopacity; however, unless symptoms of infection develop, no treatment is required (8). It is advisable that the sutures be removed after 2 weeks and that follow-up radiographs of the affected sinus be requested after 2 months to determine whether or not healing has occurred satisfactorily (1).

Some complications may occur with the removal of the fractured maxillary tuberosity. The removal of a tuberosity will most likely increase the difficulty of future denture fittings (1, 13) and may also make a later rehabilitation with dental implants more difficult.

Communication between the maxillary sinus and the oral cavity may also occur. The maxillary sinus reaches its largest size during the third decade of life (25); consequently, the incidence of OAC in oral surgery is commonly higher after the third decade of life. This type of communication can also occur after the removal of the fractured maxillary tuberosity if appropriate measures are not taken. Although smaller defects of <5 mm in diameter may close spontaneously, larger communications generally require a proper surgical closure (26). Techniques that are particularly useful in the correction of defects in the tuberosity region have been described in prior literature (27, 28). If the communication fails to be diagnosed and managed properly, there is a high risk of developing an epithelialized permanent oroantral fistula, and maxillary sinusitis then becomes a prevalent complication (26).

Deafness, the most frightening complication, may also occur because of tuberosity fracture. Cattlin (7) reported that, after maxillary tuberosity fracture, deafness occurred from the disruption of the pterygoid hamulus and the tensor veli palatine, in turn collapsing the opening of the eustachian tube. The patient also suffered permanent restricted mandibular movements because of the disruption of the pterygoid muscles and ligaments.

Conclusions

Considering that the anatomy of the maxillary tuberosity faces the constant presence of root projections in the maxillary sinus and the constant extension of the maxillary sinus to the most posterior region of the maxilla, care for third molar extractions must be intensified so as to avoid tuberosity fracture. Dental professionals must inform their patients of the potential risks and possible benefits of treatment alternatives before determining the final treatment plan. A proper preoperative radiographic interpretation, coupled with the anatomical knowledge of the structures involved, is essential to prevent such complications. CT and CBCT should be considered appropriate radiographic diagnostic techniques when other radiographic methods are deemed inadequate. If it is believed that a high risk of a

maxillary tuberosity fracture may occur, then a surgical extraction of the molar is generally recommended. Prevention of this complication is the best option and should include a proper preoperative examination and appropriate surgical plan.

Acknowledgements

We thank Dr Carlos Henrique Bettoni Cruz de Castro and Dra Priscila Jales Oliveira.

References

- Cohen L. Fractures of the maxillary tuberosity occurring during tooth extraction. *Oral Surg Oral Med Oral Pathol* 1960;13:409–11.
- Baniwal S, Paudel KR, Pyakurel U, Bajracharya M, Niraula SR. Prevalence of complications of simple tooth extractions and its comparison between a tertiary center and peripheral centers: a study conducted over 8,455 tooth extractions. *JNMA J Nepal Med Assoc* 2007;46:20–4.
- Christiaens I, Reyckler H. Complications après extraction de dents de sagesse. Etude rétrospective de 1213 cas. *Rev Stomatol Chir Maxillofac* 2002;103:269–74.
- Arrigoni J, Lambrecht JT. Komplikationen bei und nach operativer Weisheitszahnentfernung. *Schweiz Monatsschr Zahnmed* 2004;114:1271–9.
- Marciani RD, Hendler BH. Trauma. In: Fonseca RJ, editor. *Oral and maxillofacial surgery*, 1st edn. Philadelphia: W.B Saunders; 2000. p. 71–5.
- Punwutukorn J, Waikakul A, Pairuchvej V. Clinically significant oroantral communications—a study of incidence and site. *Int J Oral Maxillofac Surg* 1994;23:19–21.
- Cattlin W. A paper on the form and size of the adult antrum and on the diagnosis and treatment of inflammation of the lining membrane. *Tr Odont Soc* 1858;2:31–46.
- Norman JE, Cannon PD. Fracture of the maxillary tuberosity. *Oral Surg Oral Med Oral Pathol* 1967;24:459–67.
- Shah N, Bridgman JB. An extraction complicated by lateral and medial pterygoid tethering of a fractured maxillary tuberosity. *Br Dent J* 2005;198:543–4.
- Hauman CH, Chandler NP, Tong DC. Endodontic implications of the maxillary sinus: a review. *Int Endod J* 2002;35:127–41.
- Waite DE. Maxillary sinus. *Dent Clin North Am* 1971;15:349–68.
- Kim HJ, Yoon HR, Kim KD, Kang MK, Kwak HH, Park HD et al. Personal-computer-based three-dimensional reconstruction and simulation of maxillary sinus. *Surg Radiol Anat* 2002;24:393–9.
- Ngeow WC. Management of the fractured maxillary tuberosity: an alternative method. *Quintessence Int* 1998;29:189–90.
- Sharan A, Madjar D. Correlation between maxillary sinus floor topography and related root position of posterior teeth using panoramic and cross-sectional computed tomography. *Oral Surg Oral Med Oral Pathol Oral Radiol Endod* 2006;102:375–81.
- Dölekoğlu S, Fisekcioğlu E, Ilgü D, Ilgü M, Bayirli G. Diagnosis of jaw and dentoalveolar fractures in a traumatized patient with cone beam computed tomography. *Dent Traumatol* 2010;26:200–3.
- Tyndall AA, Brooks SL. Selection criteria for dental implant site imaging: a position paper of the American Academy of Oral and Maxillofacial Radiology. *Oral Surg Oral Med Oral Pathol Oral Radiol Endod* 2000;89:630–7.
- Altuğ HA, Sahin S, Sencimen M, Dogan N. Extraction of upper first molar resulting in fracture of maxillary tuberosity. *Dent Traumatol* 2009;25:e1–2.

18. Burland JG. Fracture of the maxillary tuberosity during tooth extraction. *Dent Practitioner* 1962;12:313–21.
19. Park H-S, Lee Y-J, Jeong S-H, Kwon T-G. Density of the alveolar and basal bones of the maxilla and the mandible. *Am J Orthod Dentofacial Orthop* 2008;133:30–7.
20. Polat HB, Ay S, Kara MI. Maxillary tuberosity fracture associated with first molar extraction: a case report. *Eur J Dent* 2007;1:256–9.
21. Altonen M, Rantanen AV. Factors increasing the risk of fracture of the maxillary tuberosity during tooth extraction. *Pro Finn Den Soc* 1976;72:163–9.
22. Seward GR, Harris M, McGowan DA. Killey and Kay's outline of oral surgery. Part I, 2nd edn. Bristol: Wright; 1987. p. 252–3.
23. Andreassen JO. Fracture of the alveolar process of the jaw: a clinical and radiographic follow-up study. *Scand J Dent Res* 1970;78:263–72.
24. Fonseca RJ. Oral and maxillofacial surgery, Vol 1. Pennsylvania: W.B. Saunders; 2000. 430 pp.
25. Sedwick HJ. Form, size and position of the maxillary sinus at various ages studied by means of roentgenograms of the skull. *Am J Roentgenol* 1934;32:154–60.
26. Güven O. A clinical study on oroantral fistulae. *J Craniomaxillofac Surg* 1998;26:267–71.
27. Salins PC, Kishore SK. Anteriorly based palatal flap for closure of large oroantral fistula. *Oral Surg Oral Med Oral Pathol Oral Radiol Endod* 1996;82:253–6.
28. Lee JJ, Kok SH, Chang HH, Yang PJ, Hahn LJ, Kuo YS. Repair of oroantral communications in the third molar region by random palatal flap. *Int J Oral Maxillofac Surg* 2002;31:677–80.