

# We are IntechOpen, the world's leading publisher of Open Access books Built by scientists, for scientists

4,500

Open access books available

118,000

International authors and editors

130M

Downloads

Our authors are among the

154

Countries delivered to

TOP 1%

most cited scientists

12.2%

Contributors from top 500 universities



WEB OF SCIENCE™

Selection of our books indexed in the Book Citation Index  
in Web of Science™ Core Collection (BKCI)

Interested in publishing with us?  
Contact [book.department@intechopen.com](mailto:book.department@intechopen.com)

Numbers displayed above are based on latest data collected.  
For more information visit [www.intechopen.com](http://www.intechopen.com)



---

# **Surgical Exposure and Orthodontic Alignment of Impacted Teeth**

---

Mohammad Hosein Kalantar Motamedi

Additional information is available at the end of the chapter

<http://dx.doi.org/10.5772/58956>

---

## **1. Introduction**

Tooth impaction is a condition in which the tooth is embedded in the tissues such that its eruption is prevented.[1, 2] Management of impactions is usually either by surgical exposure and forced eruption or surgical extraction; the decision depends upon a multitude of factors that need to be assessed via clinical and radiographic evaluations of the patient before formulating the overall treatment plan. The clinical evaluation includes assessment of:

- Patient age
- Oral hygiene and dental caries
- Depth of the impaction
- Displacement of the impaction and associated pathologies
- Esthetics and morphological suitability of the impaction
- Functionality of the impacted tooth
- Length of orthodontic and surgical treatment and costs
- Worthiness of salvaging the impacted tooth
- Treatment options for the impaction
- Feasibility of surgical exposure and orthodontic alignment

These factors are among the issues that are influential in deciding whether to expose or to extract the impacted tooth. Patient cooperation and compliance are additional determinants which should be considered before commencing treatment. [3, 4]

## **2. Clinical evaluation**

### **2.1. Patient age**

The best age for tooth exposure and forced eruption or surgical extraction is in childhood and adolescence; because as age increases, the impacted tooth often develops ankylosis (fusion to bone) precluding the possibility to move it into the dental arch orthodontically. The inability to move the impaction may not be readily diagnosed preoperatively; and may become evident only when the tooth fails to move after it has been exposed and orthodontic traction has been applied for several weeks or more. Aside from age, ankylosis may occur following dentoalveolar trauma in childhood or adolescence. Trauma to the primary dentition in childhood can lead to damage to the dental germ resulting in deformation or displacement. Premature loss of a primary tooth may also result in delayed or barred eruption of the permanent tooth due to bone or dense fibrous tissue formation in the normal path of eruption.

### **2.2. Oral hygiene and dental caries**

Tooth exposure, forced eruption and orthodontic therapy of an impaction may not be indicated if the patient has rampant caries, poor oral hygiene, lacks motivation or is uncooperative. If the impacted tooth is decayed, it may be an indication for removal of the impaction.

### **2.3. Depth of the impaction**

Impactions that are very deep may not be amenable to exposure and orthodontic therapy. Sometimes even surgical removal of such teeth is not indicated especially when harm may be inflicted upon vital structures or teeth in the course of the procedure. Such cases may be left alone and followed periodically with radiographs every 6-12 months for changes in the follicle of the impaction. Removal of the crown only (coronectomy) is another option.

### **2.4. Displacement of the impaction and associated pathologies**

Displacement of adjacent teeth and pathological lesions associated with an impacted tooth may mandate removal of the impaction. However, eruption cysts, dentigerous cysts and benign lesions (i.e. adenomatoid odontogenic tumor, giant cell lesions, aneurysmal bone cysts etc.) may be exceptions. In these cases it may be possible to just remove the pathology and salvage the impacted tooth (discussed later in this chapter). [5-13]

### **2.5. Esthetics and morphological suitability of the impaction**

Esthetics and morphological suitability of the impaction are among the issues that may influence the decision to expose or to extract the impacted tooth. The canine tooth for example is very strategic because it is usually visible when the patient smiles; therefore, it merits salvage; whereas, a deformed, unsightly or nonfunctional canine may not be worth saving unless it can be restored.

## 2.6. Functionality of the impacted tooth

A severely deformed or short-rooted impacted tooth deemed unlikely to be functional is more likely to require removal rather than surgical exposure and orthodontic alignment.

## 2.7. Length and costs of orthodontic and surgical treatment

The length of orthodontic and surgical treatment and expenses are additional sideline issues to be considered and discussed with the patient, parents or guardians before formulating a treatment plan. The length of orthodontic treatment to guide the impaction into the dental arch and into occlusion, usually takes 1-3 years (depending on patient age, bone density, the amount of root formation and dilaceration, depth and angulation of the impaction, available arch space etc.). Expenses are directly correlated to the aforementioned parameters (the longer it takes to bring the impaction into position the more it will cost). An estimate should be made prior to commencing treatment.

## 2.8. Worthiness of salvaging the impacted tooth

*The third molar* is commonly impacted because of arch-length tooth-size discrepancy. Wisdom teeth often require extraction due to lack of arch space, periodontal pockets, a blocked path of eruption, malocclusion, caries or pericoronitis. Thus, third molars are rarely surgically exposed or uprighted; however, up-righting the mandibular third molar may be indicated when a distal abutment is needed for anchorage of a prosthesis.

*Second molars and premolars* are less commonly impacted and treatment is dictated by factors such as occlusion, arch space, caries, strategic value of the tooth and costs. The decision to salvage or extract is case-specific. Decisions are made after clinical assessment, consultation and collaboration with the orthodontist.

*The permanent incisors* are rarely impacted; however, when they are, they often merit salvaging in both jaws because they are esthetically important and readily seen when the patient smiles. They also play a major role in the dental midline which is very important esthetically; because deviation of the dental midline is conspicuous and readily noticed by others.

*The permanent canine* of the maxilla is the second most commonly impacted tooth. It is the tooth with the longest root and is important in cuspid-rise type occlusions. The canine is usually seen when the person smiles. It is thus, esthetically important and merits salvaging whenever possible.

## 2.9. Treatment options for the impaction

The treatment options open to a patient with a permanent impacted canine include:

1. *Interceptive removal*: Interceptive removal of the deciduous canine to enhance eruption of the permanent canine is done when the root has not formed completely and space is available for eruption.

2. *No treatment*: No treatment, except periodic radiographical evaluation for pathological changes, is done when there are limitations to surgically expose or extract.
3. *Surgical removal*: Surgical removal of the impacted canine and prosthetic replacement is done when there are limitations for salvaging the tooth.
4. *Surgical exposure*: Surgical exposure of the impacted canine and orthodontic alignment is done when indicated and deemed feasible. [3, 4]

Data such as age and sex, space for alignment, presence of the primary canine, migration of the first premolar in the site of the canine, and other aforementioned issues must be assessed and documented. If the tooth is strategic and should it be desired to save it, then a feasibility study must also be done to see whether the impacted canine can respond to surgical exposure and forced eruption or if it has to be surgically removed.

## 2.10. Feasibility of surgical exposure and orthodontic alignment

Salvaging the bone-impacted canine of the palate usually requires a combination of both surgical and orthodontic management. To ascertain if exposure and orthodontic treatment is feasible, first arch space assessment followed by the radiographic evaluation is necessary.

## 2.11. Arch space assessment

A comprehensive evaluation must be done In order to assess whether or not space is available in the arch or has to be made available for eruption and alignment of the impacted tooth, or if the impaction must be removed. Sometimes the primary tooth has not exfoliated and should be extracted. Arch space and tooth size measurements have to be done. More often than not, space has to be made orthodontically to accommodate the canine in the dental arch.

## 2.12. Radiographic evaluation

In addition to clinical assessments, predicting the feasibility to expose and move an impacted permanent canine from the hard palate into the alveolar arch can be done radiographically. Radiographic records are used to assess depth of the impaction, root morphology and the degree of difficulty.

## 2.13. Radiographic records

Radiographic records (orthopantomogram [OPG], periapical [PA], and maxillary occlusal [MO]) must be taken, assessed and documented. Preoperative radiographs of each patient have to be viewed and examined using a light box. Digital images can be viewed on an LCD monitor. Root anomalies and radiographic measurements are sought prior to treatment.

## 2.14. Root anomaly

The presence or absence of root anomaly must be recorded when apparent on the OPG, PA, and MO radiographs. Root angulation or dilaceration must also be assessed from the

radiographs. Severe dilaceration or bulky roots may render forced eruption and alignment unfeasible.

#### 2.14.1. Radiographic measurements

Several angles and measurements of impacted canine position can be made from the OPG radiograph namely:

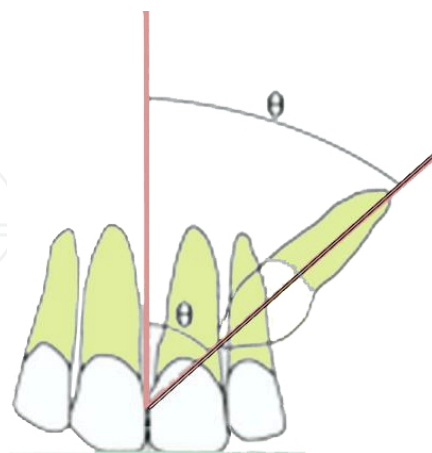
- canine angulation to the midline (CAM),
- ratio of root formation (RRF),
- lateral incisor root overlap (LIRO) and
- degree of vertical impaction (DVI)

The aforementioned measurements may aid in the decision making process.

#### 2.14.2. Canine angulation to the midline (CAM)

A midline is constructed as shown in Fig. 1 and a second line is drawn through the canine root apex and canine tip to the midline. The angle formed between the 2 lines is the impacted canine angulation to the midline, and is graded as follows:

- **Grade1** (0-15°), Easy
- **Grade2** (16-30°), Moderate
- **Grade3** (31°+), Difficult



**Figure 1.** The angulation of the palatally-impacted canine to the midline. The more obtuse the angle the more difficult it will be to expose and align and the poorer the prognosis.

The more obtuse the angle the more difficult it will be to expose and align the impacted canine and the poorer the prognosis.

### 2.14.3. Ratio of Root formation (RRF)

The canine root formation ratio is graded from 1 to 3 depending upon the amount of root formed:

- **Grade 1** (1/3 formed), Easy
- **Grade 2** (2/3 formed), Moderate
- **Grade 3** (completely formed) Difficult

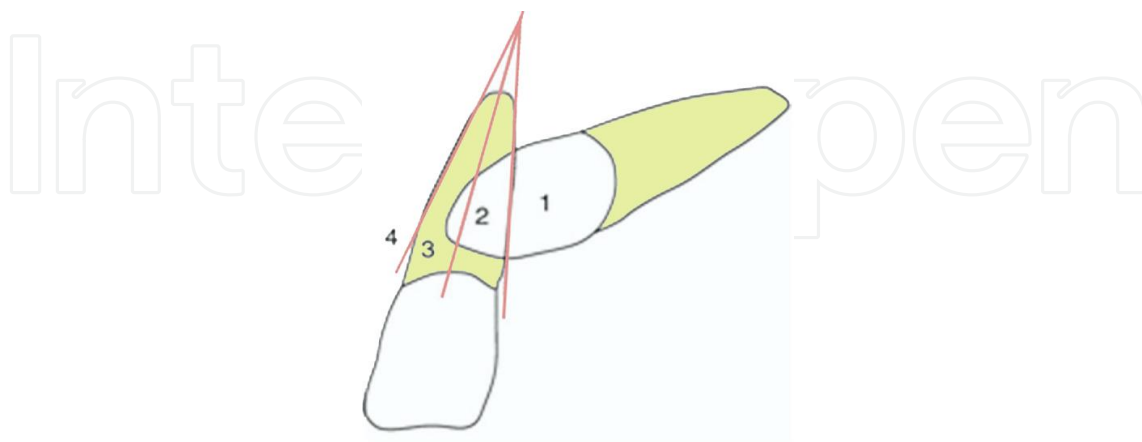
The more the root has formed the more difficult it will be to expose and align the impacted canine and the poorer the prognosis.

### 2.14.4. Lateral incisor root overlap (LIRO)

The position of the canine(s) on the OPG helps predict the feasibility and prognosis for alignment of the canine by reference to the amount by which its crown overlaps the incisor roots in both the horizontal and vertical planes. The degree of overlap of the adjacent lateral incisor root via the crown of the palatally-impacted canine is assessed and graded as follows:

- **Grade 1:** No horizontal overlap; Easy
- **Grade 2:** Overlap less than half the root width; Moderate
- **Grade 3:** Overlap more than half, but less than the whole root width; Difficult
- **Grade 4:** Complete overlap of root width or more; Very difficult.

The closer the canine is to the midline in the horizontal plane the greater the difficulty and the poorer the prognosis (Fig. 2).



**Figure 2.** Grades of overlap of the adjacent lateral incisor root via the crown of the impacted canine in the palate. The greater the overlap the more difficult the procedure will be.

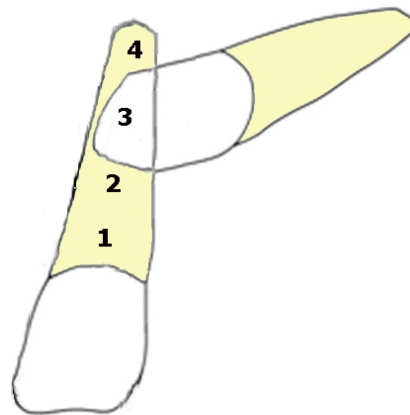


#### 2.14.5. Degree of vertical impaction (DVI)

The vertical depth of the canine(s) on the OPG also helps predict the feasibility and prognosis for alignment of the canine by reference to the amount by which it lies in respect to the apical third of the lateral incisor root in the vertical plane:

- **Grade 1** Easy (canine crown at the coronal segment of the lateral incisor root).
- **Grade 2** Moderate (canine crown below the coronal segment of the lateral incisor root but above half the root).
- **Grade 3** Difficult (canine crown below half the root of the lateral incisor root but above the apex).
- **Grade 4** Very difficult (canine crown at the apical segment of the lateral incisor root).

The higher the impaction lies the greater the difficulty and the poorer the prognosis for surgical and orthodontic treatment (Fig. 3). [5, 6]



**Figure 3.** Besides the amount of overlap of the adjacent lateral incisor root via the crown of the impacted canine in the palate, the higher the impaction lies vertically the more difficult the surgical and orthodontic procedure will be.

The influence of increased canine angulation to the midline, the greater lateral tooth overlap and the deeper the vertical depth means a deep horizontally positioned impaction and thus, a more difficult canine to expose and align orthodontically. There is an increased probability that such canines will require removal instead of exposure.<sup>14-17</sup> However, although a large amount of information may be obtained regarding impacted canine position from radiographs, this was not a major influence on our decision to surgically expose or remove impacted canines. Our study showed impacted canine angulation and depth correlated with difficulty in alignment and eruption. Age may be an influencing factor; however, all our cases were adolescents.

When there is a primary canine remaining in place of the permanent canine impacted in the palate, the patient does not have much to lose if the impaction is exposed surgically and orthodontic alignment is attempted. However, if the space is occupied by the permanent first premolar then extracting the premolar to make space for the palatally bone-impacted perma-



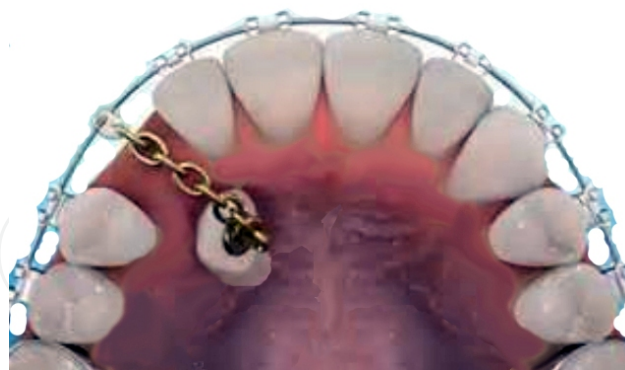erupting canine is risky because the canine may be fused and defy forced eruption. Thus, in such cases it should be attempted to expose and move the impaction before the premolar is extracted. If the impacted tooth responds favorably to forced eruption then the premolar is extracted.

### 3. Surgical exposure techniques

#### 3.1. Exposure technique for a palatally-impacted canine

The surgical technique used to expose a palatally-impacted canine is relatively uncomplicated. After local anesthesia, a window is made in the palate at the site where the crown of the impaction is anticipated to be using an electrosurgery knife; the electrosurgery knife is used to remove the tissue overlying the tooth. Then, the palatal mucoperiosteum is dissected off the bone and discarded. The bony covering of the tooth is removed with a rose bur and handpiece under copious saline irrigation. The follicular tissue is scraped off the palatal surface of the crown and removed. The cavity is enlarged if necessary by further soft tissue and/or bone removal as required to expose the entire palatal or buccal surface of the impaction (depending on the orientation of the impaction). The cemento-enamel junction is left undisturbed. After hemostasis, the tooth is dried and after acid etching and resin bonding a bracket is fixed to the labial or palatal surface of the crown; then the wound is packed using periodontal dressing.

Alternatively, orthodontic brackets may be bonded 3 to 7 days postoperatively by the orthodontist (instead of intraoperatively). Seven to 10 days postoperatively 50 to 60 g elastic traction is applied (Fig.4).

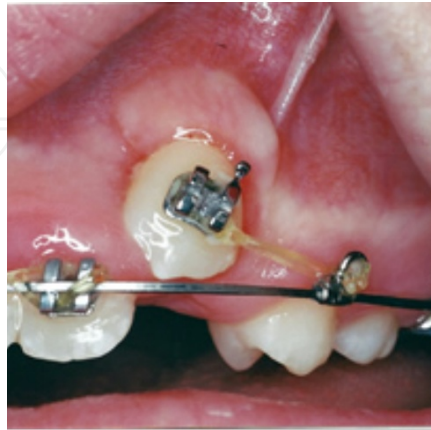


**Figure 4.** A palatally-impacted canine is exposed through a round window and a bracket is attached to the palatal surface of the crown.

#### 3.2. Exposure technique for a buccally-impacted canine

Buccally-oriented impacted canines are generally easier to treat. The surgical technique used to expose a buccally-oriented impacted canine after local anesthesia, includes reflection of a small trapezoid flap at the site where the crown of the impaction is anticipated using a scalpel

and no.15 blade. The underlying bone is removed using a round bur and handpiece. Then, the follicle is removed exposing the crown. The flap is then repositioned apically at the CEJ of the impaction and sutured in the vestibule leaving the crown exposed for bracket bonding. In due time the tooth erupts (or is forced to erupt) bringing attached gingiva along with it (Fig. 5).

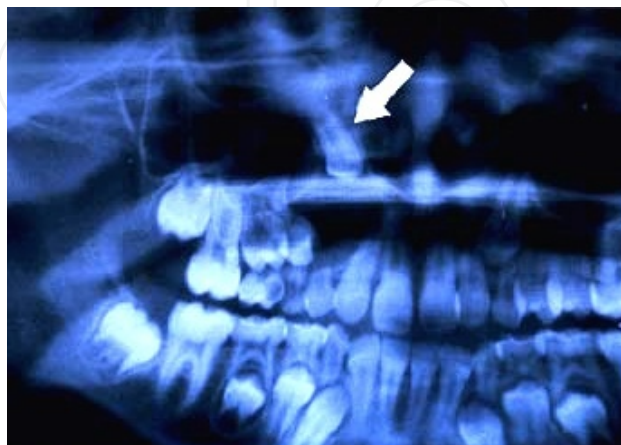

**Figure 5.** A buccally-impacted canine is exposed through a trapezoid flap sutured apically so that it erupts along with the attached gingiva; a bracket has been attached and elastic traction has been applied.

Follicular enlargement or cystic change around an impacted canine should be sought and this factor is taken into consideration when planning treatment for impacted canines. However, this per se does not mean that the impacted canine must be extracted (discussed later in this chapter).<sup>5,6</sup>

### 3.3. Severely-displaced impacted maxillary canine

Sometimes the impacted canine is displaced in the jaws; this is often due to a pathologic lesion most commonly a dentigerous cyst (Fig. 6).

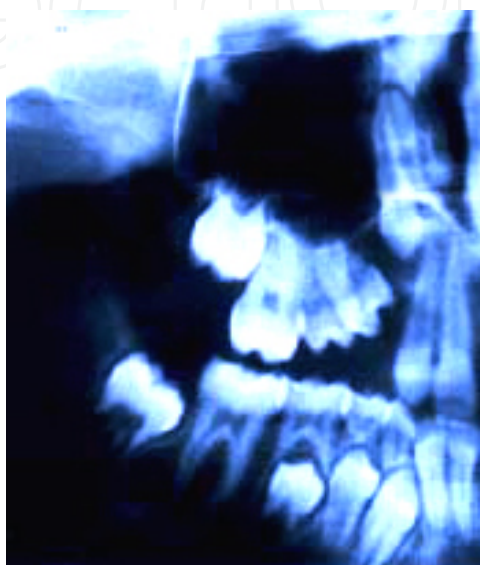


**Figure 6.** Impacted canine displaced high up in the maxilla adjacent to the orbital floor due to a dentigerous cyst.

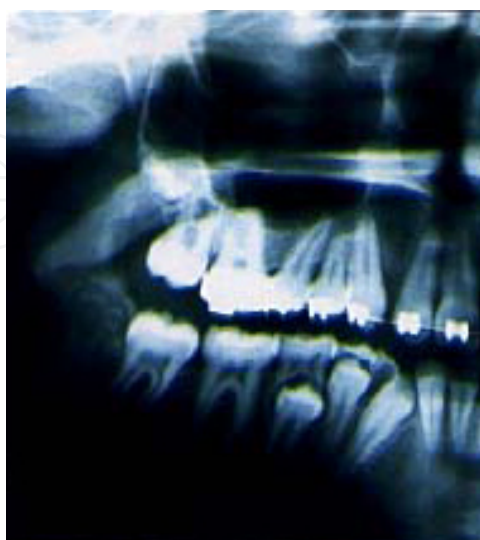
In such cases the exposure has to be made through the mucosa. Impediments (cyst, tumor, teeth, fibrosis etc.) must be removed, sent to the pathologist and the tooth be given time to descend (Fig.7).

When the tooth is accessible in the vestibule it is then exposed and bonded (Fig. 8). [18]

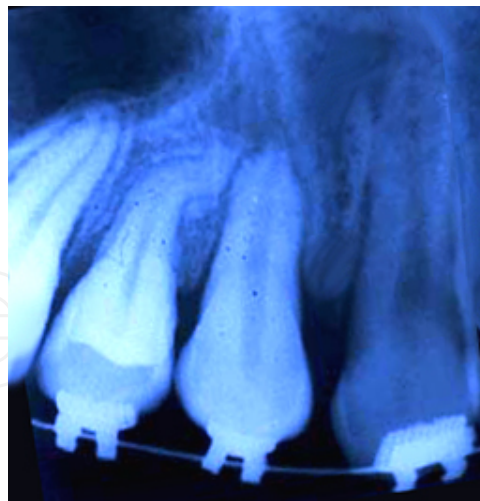
After 2 years the tooth was finally in the dental arch (Fig. 9).



**Figure 7.** The tooth has descended after cyst removal.



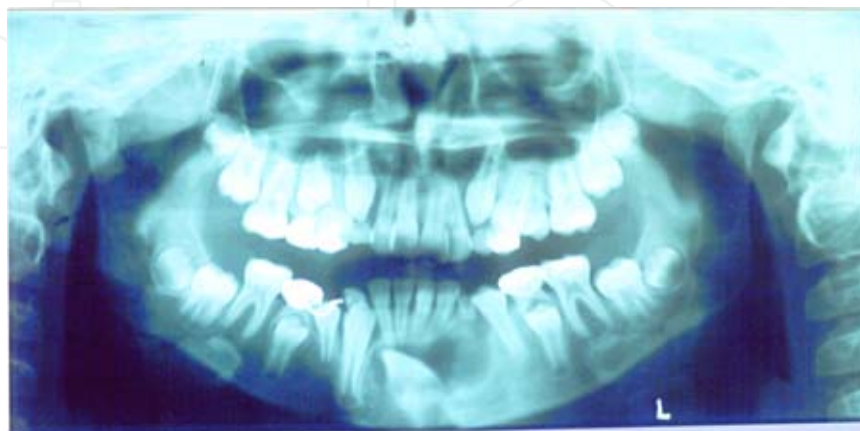**Figure 8.** The tooth has descended 3-4 cm and brought into occlusion.



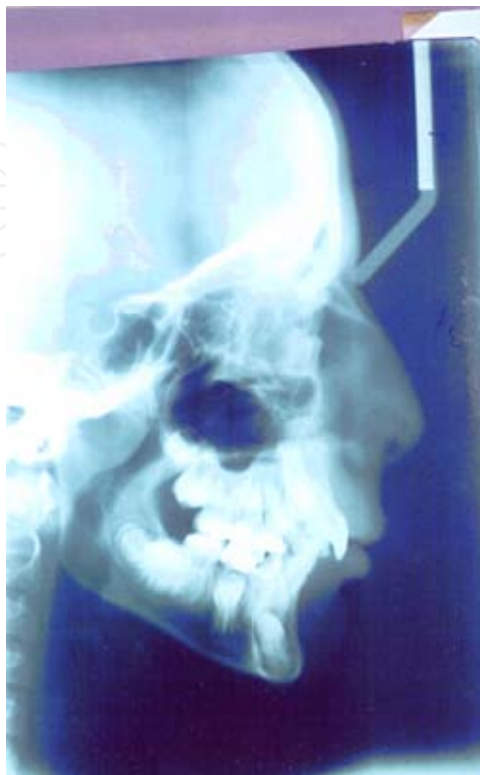**Figure 9.** The canine tooth has been brought into the dental arch. (Orthodontist: Dr. Jabari)

### 3.4. Severely-displaced impacted mandibular canine

A cyst may also displace an impaction in the mandible to a great extent. Enucleation of the cyst without extraction of the impacted tooth may be indicated for children and adolescents if the involved tooth is strategic. There may be swelling in the vestibular area of the mandibular canine region. A common cause is a dentigerous cyst. Aspiration of the lesion must be performed first; in many cases, aspiration reveals a clear yellow fluid in dentigerous cysts. Next, the entity must be confirmed by a pathologist. In our case, excisional biopsy was performed under local anesthesia via a submarginal mucoperiosteal trapezoid flap reflected from the right canine tooth to the left premolar from below the attached gingiva; the cystic lesion was removed after it was separated from the bone and incised off the tooth surface using a #15 scalpel. The flap was sewn in the vestibule, which left the crown exposed for bracket bonding. Orthodontic treatment was started 2 weeks postoperatively. (Figs. 10 and 11).

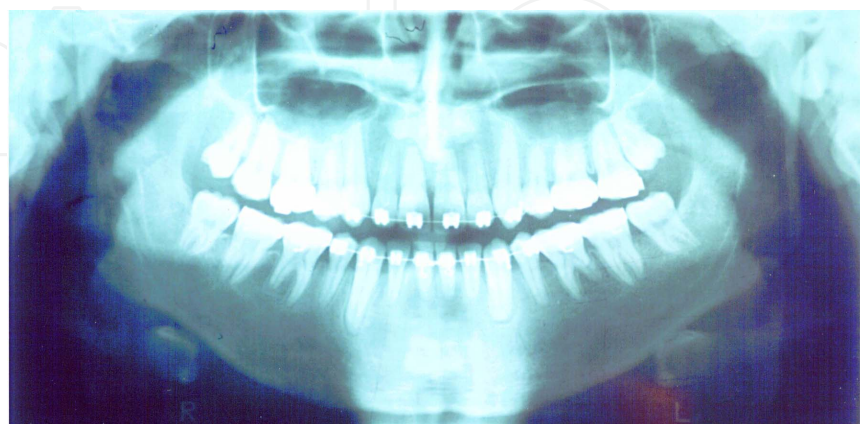

**Figure 10.** Orthopantomogram of an impacted canine displaced to the inferior border of the chin by a large dentigerous cyst of the mandible extending from the right canine to the left first premolar tooth



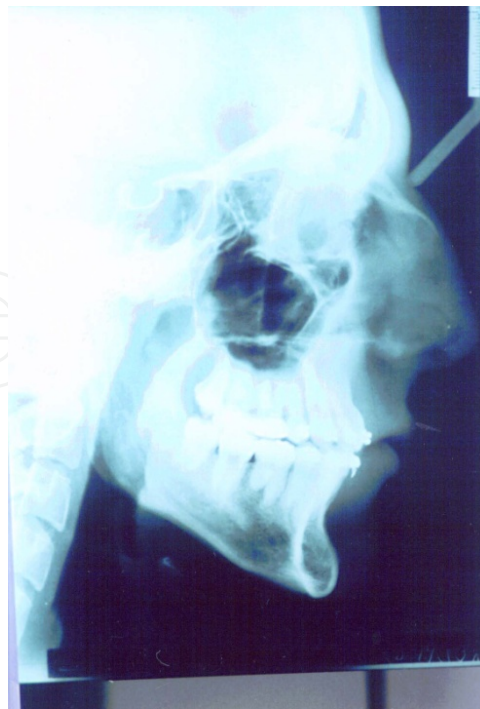**Figure 11.** Lateral cephalogram obtained at the same time.

The canine was brought into occlusion orthodontically within 4 years (Figs. 12 and 13). [19]

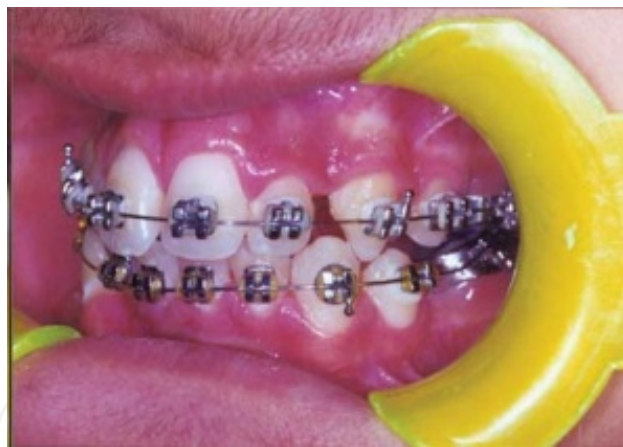

**Figure 12.** Orthopantomogram 4 years after surgery. The tooth has been brought into occlusion after surgical exposure and orthodontic guidance; the vitality of all of the teeth has been preserved.





**Figure 13.** Lateral cephalogram obtained at the same time. This bone has healed in the chin.

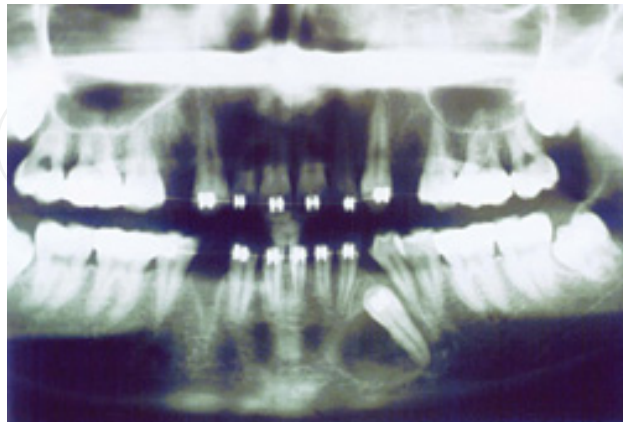


**Figure 14.** Oral view (Orthodontist Dr. Masoud Seifi).

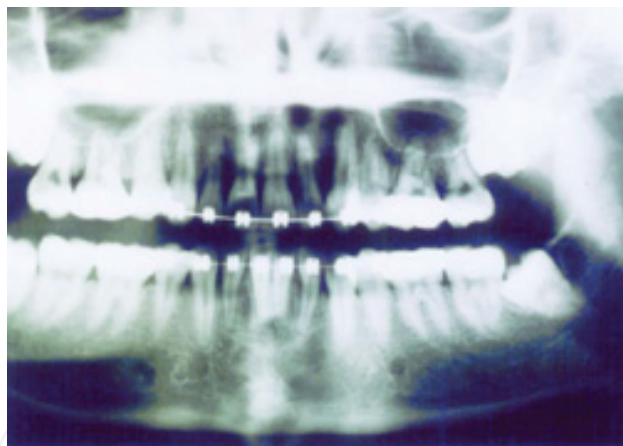
### 3.5. Impacted teeth associated with benign tumors

The surgical technique used to expose an impacted tooth associated with a benign tumor is similar. Aspiration of the lesion is negative for fluid. An excisional biopsy under local anesthesia is done. A trapezoid flap is reflected from the mesial and distal aspects of the involved tooth. The lesion is completely removed after separating the capsule from the bone and excising it off the canine tooth surface. Minimal bone removal in the bed of the lesion is done with a rose bur. Clinically, nothing is left attached to the tooth surface. The wound is irrigated and

the flap is sutured apically leaving the crown exposed for bracket bonding. Orthodontic treatment is started 1-2 weeks postoperatively depending on the case (Figs. 15 and 16). [6]



**Figure 15.** A 13-year-old female with an impacted left mandibular canine tooth and a relatively well-defined radiolucent lesion (AOT) on the mesial aspect spanning the length of the crown and root. Care was taken not to devitalize the tooth.



**Figure 16.** The 3-year postoperative radiograph showing complete bone formation and canine alignment (Orthodontist: Dr. H.A. Shafeie).

Such cases require periodic follow-up after completion of treatment. Our cases had no recurrences to date.

#### 4. Conclusion

The decision to expose or remove a bone-impacted permanent tooth is based on clinical and radiographic information as well as surgical and orthodontic judgment.



## Author details

Mohammad Hosein Kalantar Motamedi

Trauma Research Center, Baqiyatallah Medical Sciences University and Azad University of Medical Sciences, Dental College, OMFS department, Tehran, Iran

## References

- [1] Kasander T. The impacted canine: diagnosis and treatment. *J Clin Orthod* 1994;5:13-21.
- [2] Ericson S, Kurol J. Radiographic assessment of maxillary canine eruption in children with clinical signs of eruption disturbances. *Eur J Orthod* 1986;8:133-40.
- [3] Ericson S, Kurol J. Early treatment of palatally erupting maxillary canines by extraction of primary canines. *Eur J Orthod* 1988;10:283-95.
- [4] Bishara SE. Impacted maxillary canines: a review. *Am J Orthod Dentofacial Orthop* 1992;101:159-71.
- [5] Motamedi MH, Talesh KT. Management of extensive dentigerous cysts. *Br Dent J* 2005;198:203-6.
- [6] Motamedi MH, Shafeie HA, Azizi T. Salvage of an impacted canine associated with an adenomatoid odontogenic tumor: a case report. *Br Dent J* 2005;199:89-90.
- [7] Motamedi MH, Behroozian A, Azizi T, Nazhvani AD, Motahary P, Lotfi A. Assessment of 120 Maxillofacial Aneurysmal Bone Cysts: A Nationwide Quest to Understand This Enigma. *J Oral Maxillofac Surg.* 2014, joms.2013.12.032. [Epub ahead of print]
- [8] Motamedi MH, Navi F, Eshkevari PS, Jafari SM, Shams MG, Taheri M, Abbas FM, Motahhari P. Variable presentations of aneurysmal bone cysts of the jaws: 51 cases treated during a 30-year period. *J Oral Maxillofac Surg.* 2008 Oct;66(10):2098-103.
- [9] Motamedi MH. Destructive aneurysmal bone cyst of the mandibular condyle: report of a case and review of the literature. *J Oral Maxillofac Surg.* 2002 Nov;60(11):1357-61. Review.
- [10] Kalantar Motamedi MH. Aneurysmal bone cysts of the jaws: clinicopathological features, radiographic evaluation and treatment analysis of 17 cases. *J Craniomaxillofac Surg.* 1998 Feb;26(1):56-62.
- [11] Motamedi MH, Stavropoulos MF. Large radiolucent lesion of the mandibular condyle. *J Oral Maxillofac Surg.* 1997 Nov;55(11):1300-4.

- [12] Motamedi MH, Yazdi E. Aneurysmal bone cyst of the jaws: analysis of 11 cases. *J Oral Maxillofac Surg.* 1994 May;52(5):471-5.
- [13] Motamedi MH, Khodayari A. Aneurysmal bone cyst mimicking a malignancy. *J Oral Maxillofac Surg.* 1993 Jun;51(6):691-5.
- [14] Zuccati G, Ghobadlu J, Nieri M, Clauser C. Factors associated with the duration of forced eruption of impacted maxillary canines: a retrospective study. *Am J Orthod Dentofacial Orthop* 2006;130:349-56.
- [15] Baccetti T, Crescini A, Nieri M, Rotundo R, Pini Prato GP. Orthodontic treatment of impacted maxillary canines: an appraisal of prognostic factors. *Prog Orthod* 2007;8:6-15.
- [16] Ferguson JW, Parvizi F. Eruption of palatal canines following surgical exposure: a review of outcomes in a series of consecutively treated cases. *Br J Orthod* 1997;24:203-7.
- [17] Stivaros N, Mandall NA. Radiographic factors affecting the management of impacted upper permanent canines. *J Orthod* 2000;27:169-73.
- [18] Motamedi MH, Tabatabaie FA, Navi F, Shafeie HA, Fard BK, Hayati Z. Assessment of radiographic factors affecting surgical exposure and orthodontic alignment of impacted canines of the palate: a 15-year retrospective study. *Oral Surg Oral Med Oral Pathol Oral Radiol Endod.* 2009;107:772-5.
- [19] Motamedi MH, Seifi M: Is it possible to salvage impacted strategic teeth associated with extensive dentigerous cysts? *JCDA* 2005, 71:633-635.