

Short communication

TMJ arthroscopy: rare neurological complications associated with breach of the skull base

Shinali Patel^a, Waseem Jerjes^{a,b,c}, Tahwinder Upile^{a,c}, Colin Hopper^{a,b,c,*}

^a UCLH Head and Neck Centre, London, United Kingdom

^b Unit of Oral and Maxillofacial Surgery, UCL Eastman Dental Institute, London, United Kingdom

^c Department of Surgery, University College London Medical School, London, United Kingdom

Accepted 18 December 2009

Available online 1 April 2010

Abstract

We report an interesting case of vertigo and palsies of the right oculomotor and trochlear nerves associated with fluid collection in the region of the ipsilateral temporal lobe and cavernous sinus after bilateral arthroscopy of the temporomandibular joint (TMJ).

© 2010 The British Association of Oral and Maxillofacial Surgeons. Published by Elsevier Ltd. All rights reserved.

Keywords: TMJ; Arthroscopy; Neurological; Complications; Breach of the skull base

Introduction

Arthroscopy of the temporomandibular joint (TMJ) is considered to be one of the least invasive surgical interventions in patients suffering from temporomandibular disorders. A study by Perrott et al. reported that it effectively reduces pain and increases motion in patients with internal derangement of the joint.¹

When compared with other surgical interventions, arthroscopy and arthrocentesis of the TMJ are considered safe with few complications.^{2,3} Those reported include pain, vascular problems, swelling, infection, otological and neurological problems, perforation of the middle cranial fossa, and broken instruments.^{2,3}

We report an interesting case of vertigo and palsies of the right oculomotor and trochlear nerves after bilateral arthroscopy of the TMJ.

Case report

A 38-year-old white woman was referred for further management of temporomandibular disorders. Her presenting complaints included bilateral TMJ pain, and clicking and locking, which she found disabling.

Previous interventions at other hospitals included arthroscopy, arthrocentesis with balloon dilatation (5 mm H₂O), separate intraoperative morphine injections to the joint capsule, and right meniscectomy. She reported an unremarkable medical history.

Clinical examination showed limited mouth opening with bilateral tenderness and crepitation. As previous interventions had failed we did bilateral arthroscopy and entered the joint using a trocar and a 1.1 mm endoscope (Karl Storz, Tuttingen, Germany) connected to a stack system. There was no resistance from previous scarring; no signs of perforation or breach of the skull base were observed or seen on video playback, and no erosions or osteophytes of the condyle were identified. Gentle arthrocentesis (with normal saline) was done with blind placement of balloon dilatation to treat adhesions, and subsequent intra-articular morphine injections were given where appropriate into the upper joint space. This is our standard sequence for arthroscopy of the TMJ.

* Corresponding author at: Head & Neck Centre, University College Hospital, 1st Floor East Wing, 250 Euston Road, London NW1 2PG, United Kingdom.

E-mail address: c.hopper@ucl.ac.uk (C. Hopper).

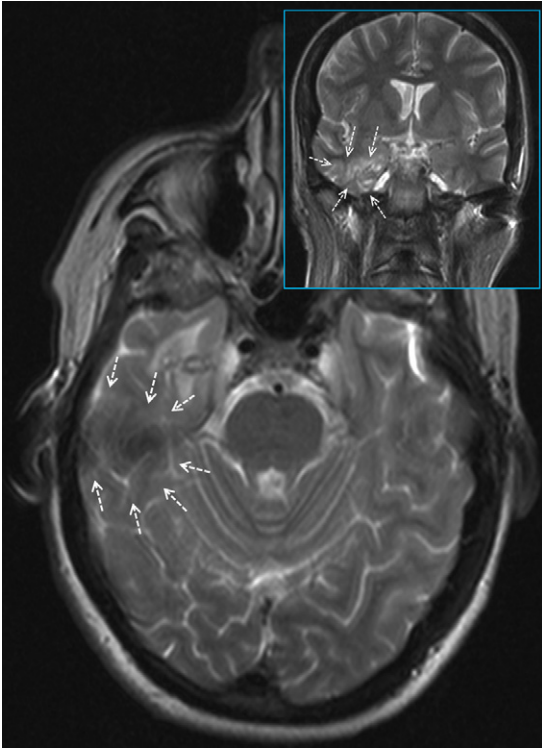


Fig. 1. Axial magnetic resonance image (MRI) one week after arthroscopy showing a signal change in the anterior aspect of the right temporal lobe. Inset: coronal MRI showing increased contrast just superior to Meckel's cave at the cavernous sinus.

In the immediate postoperative phase she had severe vertigo with weakness of the right III and IV cranial nerves, which mainly presented as ptosis and inferiolateral deviation of the eye. Magnetic resonance imaging (MRI) showed some signal change in the anterior aspect of the right temporal lobe that extended to the lateral aspect of the right cavernous region. Coronal images showed some increased contrast just superior to Meckel's cave at the cavernous sinus (Fig. 1). Neurosurgical opinion advised close follow-up and no immediate intervention.

The symptoms had resolved after 12 weeks, and MRI at the 4-month postoperative review showed complete resolution of the high signal areas (Fig. 2).

Discussion

Complications after arthroscopy of the TMJ usually present in the immediate postoperative phase, and are mostly associated with fluid collection and vascular injury.^{2,3} Other rare complications include Horner syndrome,⁴ extravasation of fluid from the articular capsule,⁵ upper airway compression,⁶ variant petrotympanic fissure,⁷ infection of the infratemporal space,⁸ pseudoaneurysm,⁹ and arteriovenous fistula.¹⁰

We hypothesised that arthroscopy of the right TMJ seemed to be associated with a breach of the skull base, which led to an accumulation of fluid in the region of the ipsilateral

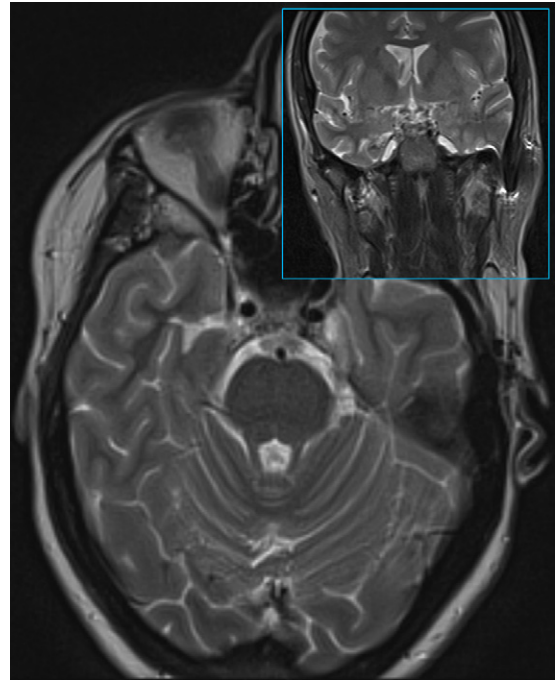


Fig. 2. Axial magnetic resonance image (MRI) four months after arthroscopy showing resolution of high signal areas. Inset: coronal MRI confirming resolution of the signal.

temporal lobe and cavernous sinus. This may have caused an increase in focal intracranial pressure leading to vertigo and palsies of the cranial nerves of that side. Physiological re-absorption of the fluid by the brain parenchyma led to a reduction in pressure and resolution of the symptoms.

In this case where there had been previous surgical interventions it may be presumed that an iatrogenic instrumental communication was created, although none was noted at operation by the experienced surgeon, and the glenoid fossa did not appear thin on radiograph.

References

1. Perrott DH, Alborzi A, Kaban LB, Helms CA. A prospective evaluation of the effectiveness of temporomandibular joint arthroscopy. *J Oral Maxillofac Surg* 1990;**48**:1029–32.
2. Carls FR, Engelke W, Locher MC, Sailer HF. Complications following arthroscopy of the temporomandibular joint: analysis covering a 10-year period (451 arthroscopies). *J Craniomaxillofac Surg* 1996;**24**:12–5.
3. González-García R, Rodríguez-Campo FJ, Escorial-Hernández V, et al. Complications of temporomandibular joint arthroscopy: a retrospective analytic study of 670 arthroscopic procedures. *J Oral Maxillofac Surg* 2006;**64**:1587–91.
4. González Martín-Moro J, Sastre-Pérez J, Pena Fernández I. Horner syndrome after temporomandibular joint arthroscopy: a new complication. *J Oral Maxillofac Surg* 2009;**67**:1320–2.
5. Sasaki K, Watahiki R, Tamura H, Ogura M, Shibuya M. Fluid extravasation of the articular capsule as a complication of temporomandibular joint pumping and perfusion. *Bull Tokyo Dent Coll* 2002;**43**:237–42.
6. Goudot P, Jaquinet AR, Richter M. Upper airway compression after arthroscopy of the temporomandibular joint. *Int J Oral Maxillofac Surg* 1999;**28**:419–20.

7. Schickinger B, Gstoettner W, Cerny C, Kornfehl J. Variant petrotympanic fissure as possible cause of an otologic complication during TMJ arthroscopy. A case report. *Int J Oral Maxillofac Surg* 1998;**27**:17–9.
8. Chossegros C, Cheynet F, Conrath J. Infratemporal space infection after temporomandibular arthroscopy: an unusual complication. *J Oral Maxillofac Surg* 1995;**53**:949–51.
9. Kornbrot A, Shaw AS, Toohey MR. Pseudoaneurysm as a complication of arthroscopy: a case report. *J Oral Maxillofac Surg* 1991;**49**:1226–8.
10. Moses JJ, Topper DC. Arteriovenous fistula: an unusual complication associated with arthroscopic temporomandibular joint surgery. *J Oral Maxillofac Surg* 1990;**48**:1220–2.