

Short communication

Septic thrombosis of the cavernous sinus and dental infection

Serryth Colbert^{a,*}, Malcolm Cameron^b, John Williams^c

^a Oral & Maxillofacial Surgery, Southampton General Hospital, Tremona Road, Southampton, Hampshire, SO16 6YD, United Kingdom

^b Addenbrooke's Hospital, Cambridge, United Kingdom

^c University of Bristol, Senate House, Tyndall Avenue, Bristol, BS8 1TH, United Kingdom

Accepted 12 July 2010

Available online 6 August 2010

Abstract

We report a case of septic thrombosis of the cavernous sinus and dental infection, and highlight the clinical features to enable prompt diagnosis and management.

© 2010 British Association of Oral and Maxillofacial Surgeons. Published by Elsevier Ltd. All rights reserved.

Keywords: Cavernous sinus thrombosis; Dental infection; Septic

Introduction

Septic thrombosis of the cavernous sinus is a potentially lethal condition. The use of appropriate antibiotics has reduced mortality from almost 100% to between 20% and 30%, but fewer than half the patients recover fully.¹ Treatment should be implemented early to minimise these risks.

Case report

A 49-year-old man was referred after a two-week history of left-sided ophthalmoplegia, ptosis, and diplopia associated with an ipsilateral unremitting frontal headache and night sweats. Clinically he had total ophthalmoplegia (cranial nerves III, IV, and VI) on the left side (Fig. 1), paraesthesia of the left ophthalmic branch of the trigeminal nerve, and a sluggish pupillary light reflex. A magnetic resonance venogram (Fig. 2) showed a non-enhancing lesion in the left cavernous sinus consistent with a thrombus or small abscess. Analysis of cerebrospinal fluid showed lymphocytic meningitis. A computed tomogram of the sinuses was normal, and serological testing showed no HIV, *Borrelia*, *Brucella*, *Cryp-*

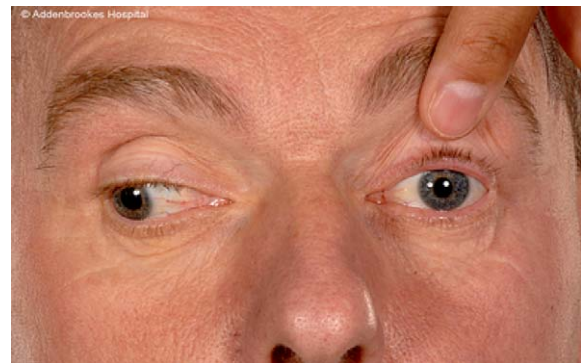

Fig. 1. Total ophthalmoplegia (cranial nerves III, IV and VI). Paralysis of the left cranial nerve III (oculomotor) is shown by ptosis and paralysis of left medial rectus muscle. (Published with the patient's consent).

tococcus, *Toxoplasma*, Cysticercosis, *Aspergillus*, Syphilis, or *Nocardia*.

Maxillofacial examination showed poorly restored dentition and periodontally compromised maxillary teeth. An orthopantomogram (Fig. 3) showed apical periodontitis associated with the left maxillary wisdom tooth, and gross decay and periodontal disease affecting the left mandibular canine and second molar teeth. We considered these teeth to be potentially responsible for the infection, and they were extracted on the same day under local anaesthesia.

* Corresponding author. Tel.: +44 1223 245151x2705.

E-mail addresses: serryth@yahoo.com (S. Colbert), malcolm.cameron@addenbrookes.nhs.uk (M. Cameron), jvwbristol@hotmail.com (J. Williams).

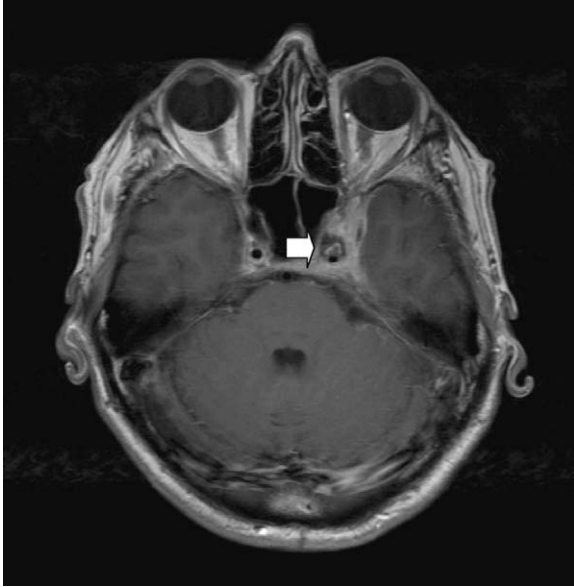


Fig. 2. Axial T1 magnetic resonance image showing non-enhancing regions within the left cavernous sinus, which may represent thrombus or small abscess. Also note the flow void of the left internal carotid artery with narrowing (arrow).

Discussion

Dental sepsis, particularly of the maxilla, has been identified in almost 10% of patients with septic thrombosis of the cavernous sinus.² Haymaker³ reviewed 28 fatal cases of intracranial infection after dental extractions, and attributed 11 deaths to involvement of the cavernous sinuses.

The cavernous sinus is a collection of thin-walled veins that lie lateral to the sella turcica and medial to the temporal bone. The internal carotid artery and the abducens nerve travel through its substance, while cranial nerves III, IV, V₁ and V₂ are within its walls.

The anatomy means that it can act like a sieve and trap bacteria, emboli, and thrombi that arise from infected periodontal tissues.

Staphylococcus aureus, which may arise from skin infections involving the mid-face has been identified in 60–70% of cases of thrombosis of the cavernous sinus.⁴ Pneumococci, streptococci, Gram-negative bacilli, polymicrobial, and fungal infections make up the remaining cases.⁵ Infected maxillary and mandibular teeth may cause infected emboli to travel to a cavernous sinus. The ensuing inflammation within its small confines may directly compress the cranial nerves (III–VI) within its substance and wall. The infection may also extend to the dural sinuses, causing meningitis, subdural empyema, and pituitary necrosis, leading to overwhelming and catastrophic illness. Most patients develop pyrexia, headache, ptosis, and ophthalmoplegia. Other signs include proptosis, chemosis and papilloedema.

The management of cavernous sinus thrombosis includes aggressive treatment with antibiotics and surgical drainage of the primary source of infection. Surgical drainage of the cavernous sinus may be required if the infection is severe, but it is rarely done because of operational difficulty and associated morbidity. The use of corticosteroids to reduce inflammation is controversial and is not well supported, but anticoagulation with heparin for four to six weeks has been shown to reduce morbidity.⁶

References

1. Yarrington Jr CT. Cavernous sinus thrombosis revisited. *Proc R Soc Med* 1977;**70**:456–9.
2. Harbour RC, Trobe JD, Ballinger WE. Septic cavernous sinus thrombosis associated with gingivitis and parapharyngeal abscess. *Arch Ophthalmol* 1984;**102**:94–7.
3. Haymaker W. Fatal infections of the central nervous system and meninges after tooth extraction with analysis of 28 cases. *Am J Orthodont Oral Surg* 1945;**31**:A117–88.
4. Southwick FS, Richardson Jr EP, Swartz MN. Septic thrombosis of the dural venous sinuses. *Medicine (Baltimore)* 1986;**65**:82–106.
5. DiNubile MJ. Septic thrombosis of the cavernous sinuses. *Arch Neurol* 1988;**45**:567–72.
6. Levine SR, Twyman RE, Gilman S. The role of anticoagulation in cavernous sinus thrombosis. *Neurology* 1988;**38**:517–22.

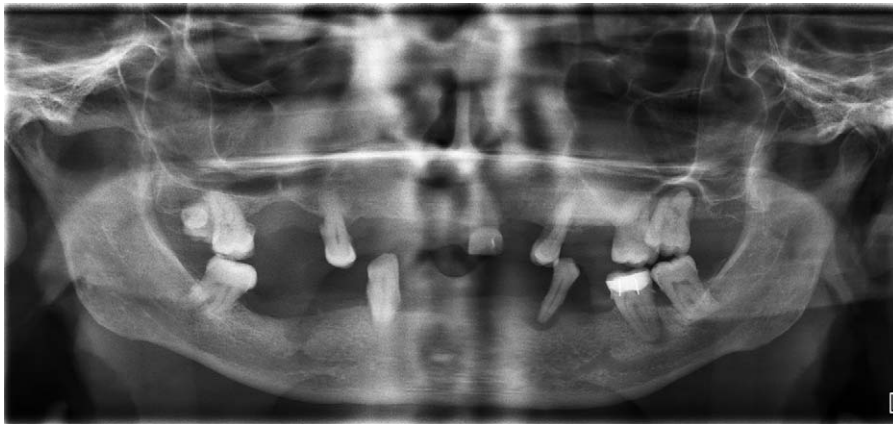

Fig. 3. Orthopantomogram showing apical periodontitis associated with dentition in the left maxillary and mandibular quadrants.