

# Oral squamous papilloma: report of a clinical rarity

Anand Pratap Singh,<sup>1</sup> Supreet Jain,<sup>1</sup> T R Chaitra,<sup>2</sup> Adwait Uday Kulkarni<sup>3</sup>

<sup>1</sup>Department of Oral Medicine & Radiology, Rungta College of Dental Sciences, Bhilai, Chhattisgarh, India

<sup>2</sup>Department of Pedodontics, Kothiwal Dental College and Research Centre, Moradabad, Uttar Pradesh, India

<sup>3</sup>Department of Oral and Maxillofacial Surgery, Sinhgad Dental College and Hospital, Pune, Maharashtra, India

## Correspondence to

Dr Anand Pratap Singh,  
anandsingh001@gmail.com

## DESCRIPTION

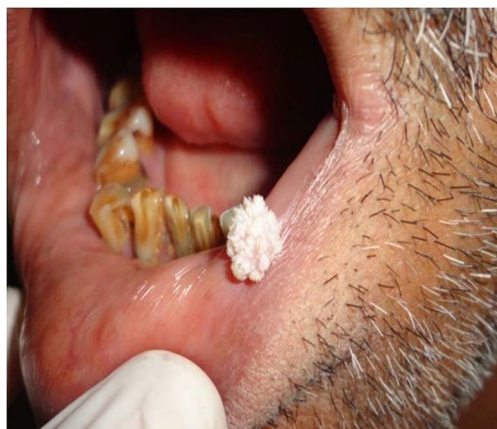Oral squamous papilloma is a benign proliferation of the stratified squamous epithelium, which results in a papillary or verrucous exophytic mass induced by human papilloma virus (HPV).<sup>1,2</sup>

A 51-year-old, healthy steel plant male worker reported with complaint of growth on lower lip near the left corner of mouth since 2 years. His medical, dental and personal history was non-contributory. The left submandibular lymph nodes were palpable and tender. The lesion appears as a small, non-tender papule 2 years back and gradually increases up to its present appearance as exophytic, pedunculated, cauliflower-like appearance with white coloured finger-like projections of size 1×1 cm and asymptomatic (figure 1).

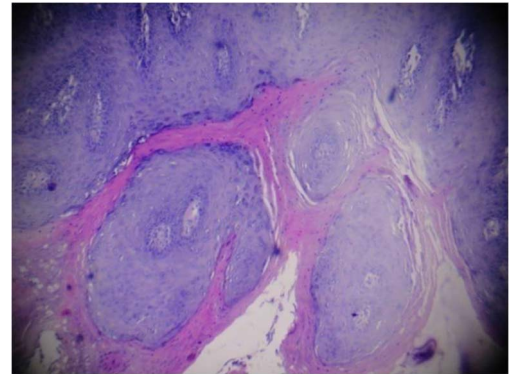
Blood investigation ELISA and PCR tests were under the normal limits. Surgical excision was done and the biopsy specimen was sent for histopathological examination which revealed proliferation of the spinous layer cells, following a digitiform pattern with a delicate core of fibrous connective tissue constituting the supporting stroma suggestive of squamous papilloma (figure 2). A 1-year follow-up was performed, and there was no evidence of recurrence of the lesion.

The association of HPV was considered as its pathogenesis especially HPV-6, 11, 16, which have already been identified in these lesions, but recent literature suggests that presence of HPV is an incidental finding and is unrelated to the development of a squamous papilloma.<sup>3</sup>

The presence of virus can be confirmed by PCR and by in situ hybridisation using radioisotope-labelled specific probes. However, hybridisation is



**Figure 1** Photograph showing the lesion.



**Figure 2** H&E-stained section.

less sensitive than PCR, which is considered the most suitable method for the detection of HPV.<sup>2</sup>

## Learning points

- ▶ The purpose of this report is to make the health community aware of this rare group of verrucous exophytic mass, which may mimic exophytic carcinoma, verrucous carcinoma or condyloma acuminatum. Even, the lesion is benign in nature but also has a small risk of malignant transformation.
- ▶ The presence of HPV is an incidental finding and is unrelated to the development of a squamous papilloma. Treatment modalities include laser ablation, cryotherapy, electrocautery, intralesional injections of interferon, salicylic acid application and conservative surgical excision.

**Competing interests** None.

**Patient consent** Obtained.

**Provenance and peer review** Not commissioned; externally peer reviewed.

## REFERENCES

- 1 Khalighi HR, Hamian M, Abbas FM, *et al.* Simultaneous existence of giant cell fibroma and squamous papilloma in the oral cavity. *Ind J Med Specialties* 2011;2:153–6.
- 2 Carneiro TE, Marinho SA, Verli FD, *et al.* Oral squamous papilloma: clinical, histologic and immunohistochemical analyses. *J Oral Sci* 2009;51:367–72.
- 3 Jaju PP, Suvarna PV, Desai RS. Squamous papilloma case report and review of literature. *Int J Oral Sci* 2010;2:222–5.

**To cite:** Singh AP, Jain S, Chaitra TR, *et al.* *BMJ Case Reports* Published online: 2 January 2013 doi:10.1136/bcr-2012-007708

Copyright 2013 BMJ Publishing Group. All rights reserved. For permission to reuse any of this content visit <http://group.bmj.com/group/rights-licensing/permissions>.  
BMJ Case Report Fellows may re-use this article for personal use and teaching without any further permission.

Become a Fellow of BMJ Case Reports today and you can:

- ▶ Submit as many cases as you like
- ▶ Enjoy fast sympathetic peer review and rapid publication of accepted articles
- ▶ Access all the published articles
- ▶ Re-use any of the published material for personal use and teaching without further permission

For information on Institutional Fellowships contact [consortiasales@bmjgroup.com](mailto:consortiasales@bmjgroup.com)

Visit [casereports.bmj.com](http://casereports.bmj.com) for more articles like this and to become a Fellow