



**Chkoura Ahmed**

**El Wady Wafae and Taleb Bouchra**

# Coronectomy of Third Molar: A Reduced Risk Technique for Inferior Alveolar Nerve Damage

**Abstract:** Causing damage to the inferior alveolar nerve (IAN) when extracting lower third molars is due to the intimate relationship between the nerve and the roots of the teeth. When the proximity radiologic markers between the IAN and the root of the third molars are present, the technique of coronectomy can be proposed as an alternative to extraction to minimize the risk of nerve injury, with minimal complications.

**Clinical Relevance:** Nerve injury after the extraction of the mandibular third molar is a serious complication. The technique of coronectomy can be proposed to minimize the risk.

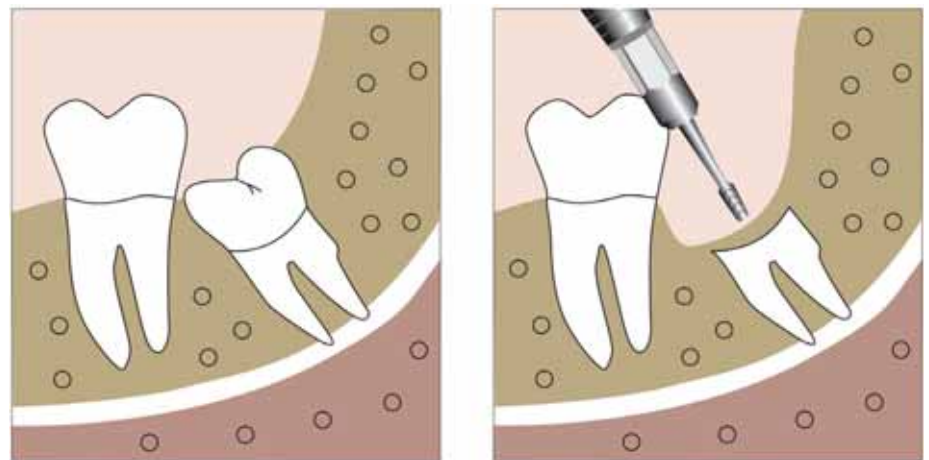
**Dent Update 2011; 38: 267–276**

Operations on mandibular third molars are common and are complicated by temporary injury to the inferior alveolar nerve in up to 8% and permanent injury in under 1% of cases.<sup>1,2</sup> Risk factors include advanced age<sup>1</sup> and difficult operating conditions,<sup>3</sup> but the most important one is the proximity of the third molar to the mandibular canal.<sup>4</sup> Coronectomy (Figure 1) avoids the inferior alveolar nerve by ensuring retention of the roots when they are close to the canal.<sup>5</sup> This has been illustrated in Cases 1 (Figures 2–5), 2 (Figures 6, 7) and 3 (Figures 8–11).

## Radiological markers of proximity of tooth roots to inferior alveolar nerve

The relationship between the roots of mandibular teeth and the

**Chkoura Ahmed**, Resident in Oral Surgery, Faculty of Dentistry, **El Wady Wafae**, Professor and Chief of the Division of Oral Surgery, Faculty of Dentistry and **Taleb Bouchra**, Professor of Oral Surgery, Faculty of Dentistry, Rabat, Morocco.

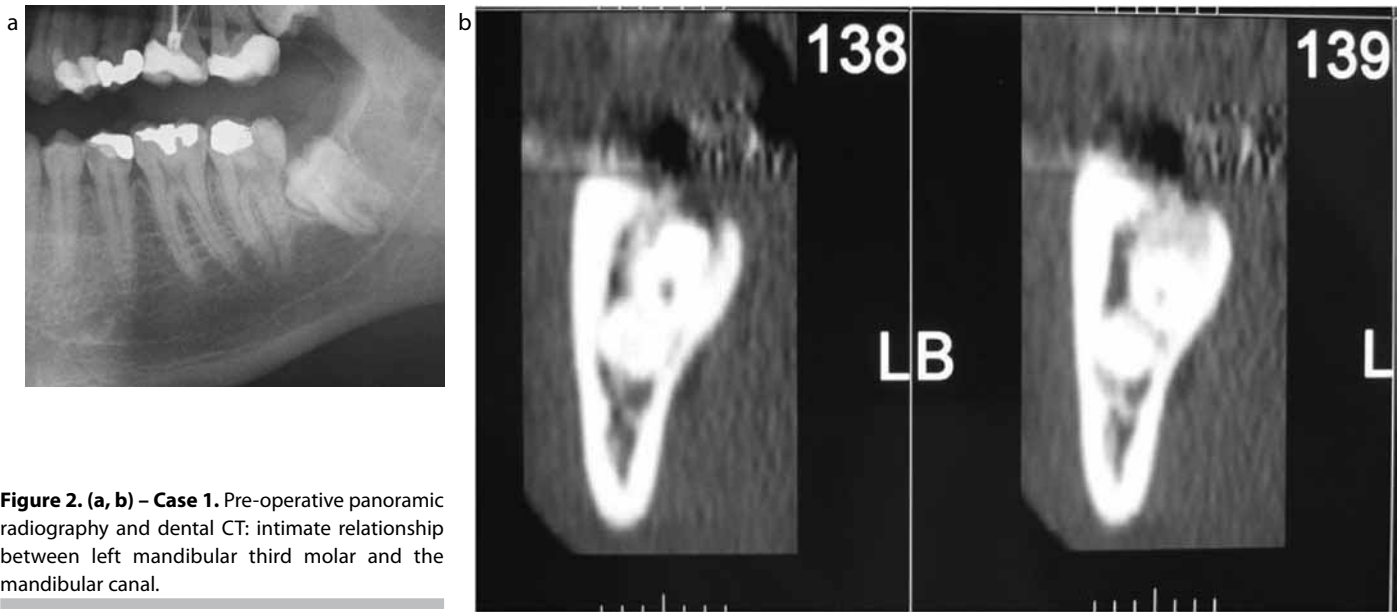


**Figure 1.** Coronectomy technique: resection of the crown 2–3 mm below the enamel of the tooth.

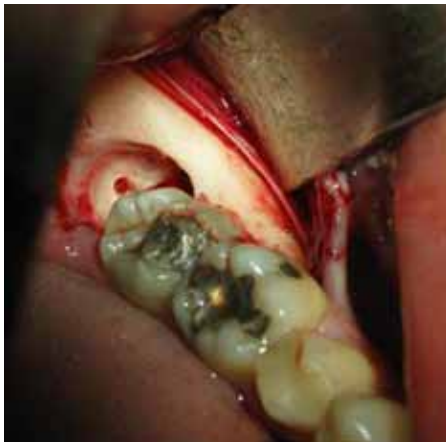inferior alveolar nerve can often be assessed radiographically, particularly with a panoramic radiograph. Computed tomography scanning can be used to visualize the relationship in the third dimension,<sup>6,7</sup> and with the combination of these techniques it can be ascertained which teeth may represent the greatest risk to the inferior alveolar nerve upon removal.<sup>8</sup>

When the radiologic markers –

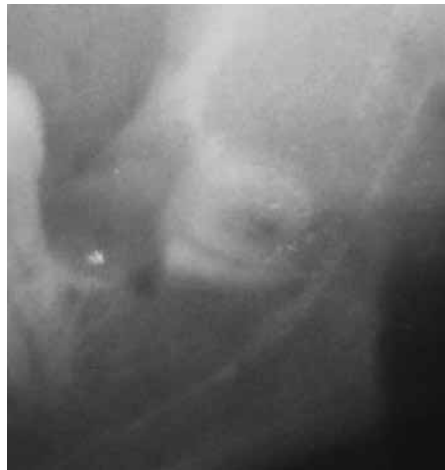
on panoramic radiography – of proximity of the IAN to the root of the third molars are present, the incidence of damage can be as high as 35%.<sup>3</sup> Howe and Poyton, by comparing the radiographic appearance of the tooth root and the IAN as to whether or not the nerve was visible in the socket at operation, produced predictors for possible damage to the nerve. When these radiologic predictors were present, the



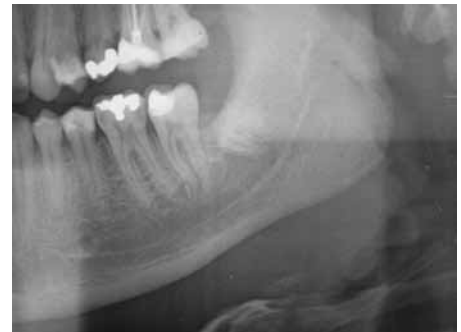**Figure 2. (a, b) – Case 1.** Pre-operative panoramic radiography and dental CT: intimate relationship between left mandibular third molar and the mandibular canal.



**Figure 3 – Case 1.** Completed coronectomy on lower right third molar. Note retained roots are 3mm below the crest of bone and exposed pulp is untreated.



**Figure 4 – Case 1.** Radiograph immediately after coronectomy of the lower left third molar showing retained root fragments.



**Figure 5 – Case 1.** Radiograph 6 months after coronectomy showing migration of the root fragments.

incidence of inferior alveolar nerve injury was 35.64%.<sup>1</sup>

Rood and Shehab, by comparing the radiological signs to the actual incidence of damage to the IAN, found that three radiologic signs (darkening of the root, interruption of the lamina dura and diversion of the canal) were statistically significant as predictors of trauma to the IAN. They found that, when one of those signs was present, the nerve was affected in 30% of cases.<sup>9</sup>

### Coronectomy and the prevention of nerve injury (Table 1)

The technique of coronectomy, or deliberate vital root retention, has been proposed as a means of removing the crown of a tooth but leaving the roots, which may be intimately related with the inferior alveolar nerve, untouched so that the possibility of nerve damage is reduced.<sup>9</sup> O’Riordan, in a study of 100 patients, showed that the risk of subsequent infection was minimal and morbidity was less after coronectomy

than after the traditional operation. Over a period of 2 years, some apices migrated and were removed uneventfully under local anaesthesia.<sup>10</sup> On the premise that coronectomy reduces the risk of nerve injury, it has been recommended for those patients for whom there is great risk of nerve injury.<sup>11</sup>

Pogrel *et al*<sup>12</sup> evaluated 41 patients who underwent coronectomy on 50 lower third molars, with follow-up of at least 6 months. This technique was used because there was radiographic evidence of a close relationship between the roots of the tooth and the inferior alveolar nerve. The authors reported that there were no cases of inferior alveolar nerve damage in this study.

Renton *et al* evaluated 128

Paper	Study design	N (extraction)	N (coronectomy)	Mean follow-up	Infection	Root migration	Nerve injury extraction/coronectomy
Knutsson <i>et al</i> (1989) <sup>8</sup>	Retrospective study, post-op status at one year	–	33	1 year			3
O’Riordan (2004) <sup>20</sup>	Case series	–	52	10 years	5.7%		3 cases of temporary sensory disturbance
Renton <i>et al</i> (2005) <sup>5</sup>	Randomized controlled trial : incidence of IANI, coronectomy versus removal	102	94	25 months	10% (extraction group), 12% (coronectomy group)	13–15 %	19% (extraction group) 0% (coronectomy group)
Pogrel <i>et al</i> (2004) <sup>12</sup>	Prospective cohort study	–	50	22 months		30%	None
Hatano <i>et al</i> (2009) <sup>13</sup>	Case-control study	118	102	13 months			5% (extraction group) 1% (coronectomy group)
Leung and Cheung (2009) <sup>14</sup>	Randomized Controlled Trial RCT: safety of coronectomy versus extraction	178	171	24 months	6.7% (extraction group) 5.8% (coronectomy group)	62.2% (1 year after coronectomy)	5% (extraction group) 0.65% (coronectomy group)

**Table 1.** Studies on coronectomy.

patients who required operations on mandibular third molars and who had radiological evidence of proximity of the third molar to the canal of the inferior alveolar nerve. Patients were divided in two groups: extraction group (102 teeth) and coronectomy group (94 teeth). The mean follow-up was 25 months. The authors reported that 19 nerves were damaged (19%) after extraction and none after coronectomy.<sup>5</sup>

Hatano *et al* compared coronectomy with traditional extraction on 220 patients, 118 in the extraction group and 102 in the coronectomy group. The mean follow-up time was 13 months

in the extraction group and 13.5 months in the coronectomy group. Six inferior alveolar nerve injuries (5%) were found in the extraction group. In the coronectomy group, 1 patient (1%) had symptoms of nerve injury.<sup>13</sup>

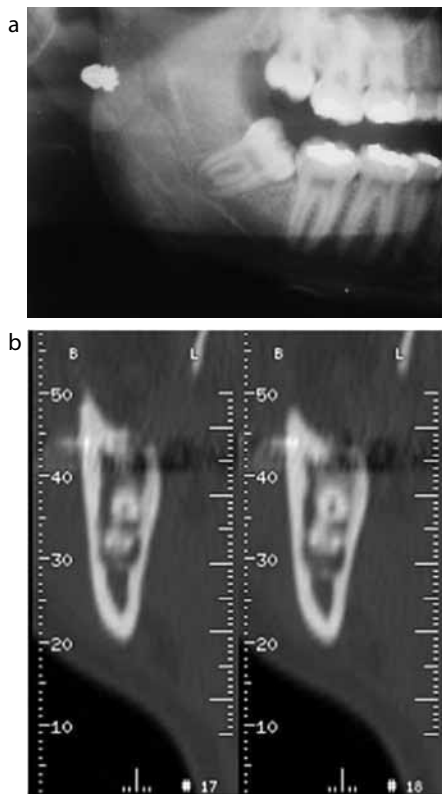
In the study of Leung and Cheung, nine patients in the extraction group (n = 178) presented inferior alveolar nerve deficit, compared with one in the coronectomy group (n = 171). The follow-up of the study was 24 months.<sup>14</sup>

### Coronectomy technique

Coronectomy involves

transection of the tooth 2–3 mm below the enamel of the crown. The pulp is left in place after the crown has been levered off.<sup>5,12</sup> The technique of leaving the retained root fragment at least 2 mm inferior to the crest of bone seems appropriate and does appear to encourage bone formation over the retained root fragment. This distance of 2 to 3 mm has been validated in animal studies.<sup>12</sup>

There is no need for a root canal treatment or any other therapy to the exposed vital pulp of the tooth. Following a periosteal release, a watertight primary closure of the socket is performed with one or more vertical mattress sutures.<sup>12</sup>

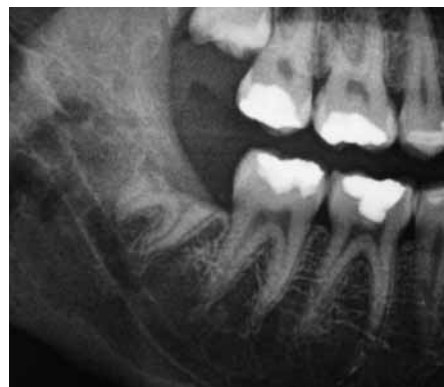

**Figure 6 (a,b) – Case 2.** Preoperative panoramic radiography and dental CT: intimate relationship between right mandibular third molar and the mandibular canal.

Pogrel considered that all patients must be placed on prophylactic antibiotics pre-operatively, because it is felt that antibiotics should be in the pulp chamber of the tooth at the time it is transected. However, some studies have indicated that antibiotics were unnecessary.<sup>12</sup>

### Outcome of the roots

One logical question is the outcome of roots left in place after the coronectomy. Poe *et al*<sup>15</sup> showed in dogs that, in vital retention of roots, all pulps survived and had calcific spurs attempting to bridge the pulp canal. Johnson *et al*<sup>16</sup> showed the same results in humans. Subsequent papers,<sup>17,18,19</sup> some of which examined roots and adjacent bone 'en bloc', found that the pulp remained vital. Animal studies have shown that vital roots remain vital with minimal degenerative changes. Osteocementum usually extends to cover



**Figure 7 – Case 2.** radiograph six months later: migration of the root fragments.

the roots.

When the crown is removed the pulp is no longer enclosed in a rigid compartment with a tiny apical outlet, so any hyperaemia or inflammatory oedema after the surgical 'insult' can expand without restriction. However, the cut pulp should be irrigated well and any manipulation avoided.<sup>20</sup>

Radiographs after 6 months can show bone formation having occurred superior to the retained root fragment. Migration of the root has been noted in every article published on the subject and appears to occur in between 14% and 81% of cases, depending on the length of follow-up.<sup>21</sup>

The study of Leung and Cheung revealed that more than half of roots migrated at a high rate for 3 months post-operatively and then gradually stopped at 12 and 24 months.<sup>14</sup>

In the study of Pogrel *et al*, root migration was noted in approximately 30% of patients over a 6-month period (Table 1).<sup>12</sup> Case reports have suggested that it can take up to 10 years for the root fragments to erupt.<sup>22</sup>

Knutsson *et al* carried out a prospective trial on 33 patients. The surgeon resected the crown at an 'adequate' level without further grinding and the flap was closed with interrupted sutures. After one year, all but six root fragments had migrated, most between 1 and 4 mm.<sup>8</sup> Dolanmaz *et al* recorded similar migration.<sup>23</sup>

All authors, however, point out that this migration means that the root fragment comes away from the IAN

and, therefore, facilitates uncomplicated removal.<sup>19</sup>

In the study of Hatano *et al* four remaining roots had signs of post-operative infection, and the patients underwent extraction of the root. No nerve damage resulted in these patients after repeat extraction.<sup>13</sup>

Apical radiolucency without symptoms was reported. But, although the radiolucency was still evident, a lamina dura could be seen around the apex.<sup>19</sup> This appearance may be due to the migration; the area from which the root moved may have been filled with immature, more radiolucent bone, or may have been there pre-operatively owing to large cancellous spaces around the apex.<sup>20</sup>

### Rate of infection (Table 1)

O'Riordan evaluated the rate of infection of retained lower third molar roots after coronectomy in a retrospective study of 52 patients who were operated on over a 10-year period. Only 3 of 52 patients had to have roots removed because of pain or infection.<sup>20</sup>

Freedman published a retrospective series of 33 cases. Only one root had to be removed because of infection.<sup>22</sup>

In the study of Hatano *et al*, four remaining roots had signs of post-operative infection, and the patients underwent extraction of the root. No nerve damage resulted in these patients after repeat extraction.<sup>13</sup>

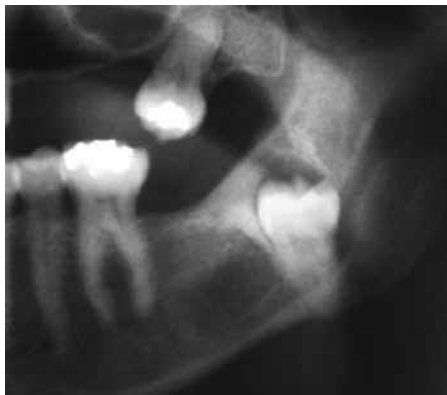In the study of Renton *et al*, the incidence of dry socket and infection was similar in the extraction group and in the coronectomy group.<sup>5</sup>

In the study of Leung and Cheung, pain and dry socket incidence was significantly lower in the coronectomy group. But there were no statistical difference in infection rate between the two groups.<sup>14</sup>

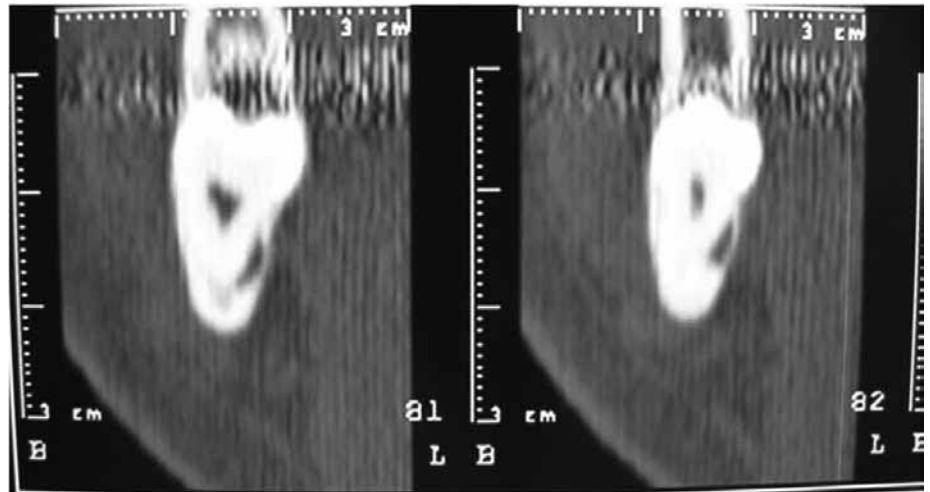
### Contra-indications

There are relatively few contra-indications to carrying out coronectomy under the appropriate circumstances, but these do include the following:

- Teeth with active infection around them, particularly infection involving the root



**Figure 8 – Case 3.** Preoperative radiograph of a vertically impacted lower left third molar showing a deflection of the mandibular canal.



**Figure 9 – Case 3.** Intimate relationship between the mandibular canal and the third molar, buccal and lingual bone are very thin, extraction can lead to nerve damage and a fracture of the mandible.

portion;

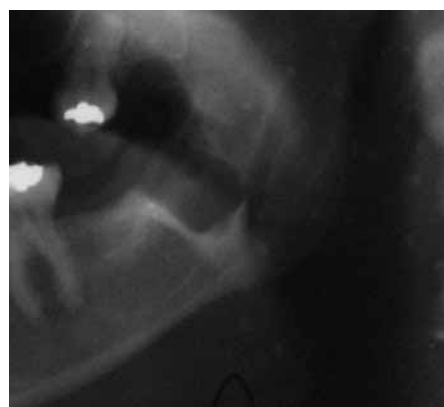- Teeth that are mobile because it might be felt that the roots may act as a mobile foreign body and become a nidus for infection or migration.

- Teeth that are horizontally impacted along the course of the inferior alveolar nerve because sectioning of the tooth could itself endanger the nerve. The technique is therefore better utilized for vertical, mesioangular, or distoangular impactions where the sectioning itself does not endanger the nerve.<sup>12,21</sup>

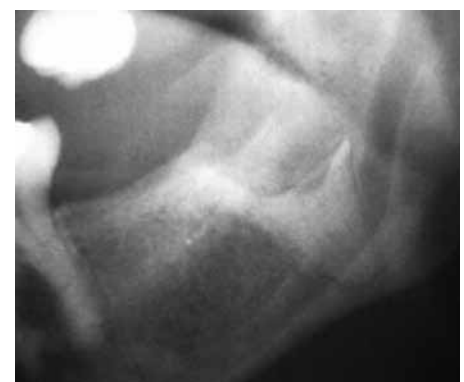There are currently no standards regarding the timing and frequency of follow-up of patients having coronectomy. Most authors take radiographs immediately post-operatively and 6 months later. Later radiographs are taken if the patient becomes symptomatic.

### Follow-up

For Renton, the follow-up after coronectomy of 25 months was considered sufficient to evaluate the incidence of nerve injury, dry socket and early eruption, but not of late eruption, which can occur up to 10 years after the initial operation. A longer review period may therefore show that a proportion of these retained roots do eventually erupt and may cause a late infection or require removal. One possible advantage, even if second operation is required, is that, unless the root is close to the IAN, it is likely to erupt away from the nerve, so reducing the potential of nerve injury during the second operation.<sup>5</sup>



**Figure 10 – Case 3.** radiograph immediately after the coronectomy.



**Figure 11 – Case 3.** radiograph 10 months later: migration of a few millimeters of roots with a new bone formation above.

### Conclusion

Nerve injury after the extraction of the mandibular third molar is a serious complication. The technique of coronectomy can be proposed to minimize the risk.

### References

1. Howe GL, Poyton HG. Prevention of damage to the inferior dental nerve during the extraction of mandibular third molars. *Br Dent J* 1960; **109**: 355–363.
2. Kipp DP, Goldstein BH, Weiss WW. Dysesthesia after mandibular third molar surgery: a retrospective study and analysis of 1,377 surgical procedures. *J Am Dent Assoc* 1980; **100**: 185–192.

3. Rud J. Third molar surgery: relationship of root to mandibular canal and injuries to inferior dental nerve. *Tandlaegebladet* 1983; **87**: 619–631.
4. Smith AC, Barry S, Chiong A *et al*. Inferior alveolar nerve damage following removal of mandibular third molar teeth. A prospective study using panoramic radiography. *Aust Dent J* 1997; **42**: 149–152.
5. Renton T, Hankinsb M, Sproatec C, McGurkc M. A randomised controlled clinical trial to compare the incidence of injury to the inferior alveolar nerve as a result of coronectomy and removal of mandibular third molars. *Br J Oral Maxillofac Surg* 2005; **43**: 7–12.
6. Pawelzik J, Cohnen M, Willers R, Becker J. A comparison of conventional panoramic radiographs with volumetric

- computed tomography images in the preoperative assessment of impacted mandibular third molars. *J Oral Maxillofac Surg* 2002; **60**: 979–984.
7. Freisfeld M, Drescher D, Kobe D, Schüller H. Assessment of the space for the lower wisdom teeth. Panoramic radiography in comparison with computed tomography. *J Orofac Orthop* 1998; **59**: 17–28.
  8. Knutsson K, Lysell L, Rohlin M. Postoperative status after partial removal of the mandibular third molar. *Swed Dent J* 1989; **13**: 15–22.
  9. Rood JP, Shehab BA. The radiological prediction of inferior alveolar nerve injury during third molar surgery. *Br J Oral Maxillofac Surg* 1990; **28**: 20–25.
  10. O’Riordan B. Uneasy lies the head that wears a crown. *Br J Oral Maxillofac Surg* 1997; **35**: 209–212.
  11. Zola MB. Avoiding anaesthesia by root retention. *J Oral Maxillofac Surg* 1992; **50**: 419–421.
  12. Pogrel MA, Lee JS, Muff DF. Coronectomy: a technique to protect the inferior alveolar nerve. *J Oral Maxillofac Surg* 2004; **62**: 1447–1452.
  13. Hatano Y, Kurita K, Kuroiwa Y, Yuasa H, Ariji E. Clinical evaluations of coronectomy (intentional partial odontectomy) for mandibular third molars using dental computed tomography: a case-control study. *J Oral Maxillofac Surg* 2009; **67**: 1806–1814.
  14. Leung YY, Cheung LK. Safety of coronectomy versus excision of wisdom teeth: a randomized controlled trial. *Oral Surg Oral Med Oral Pathol Oral Radiol Endod* 2009; **108**: 821–827.
  15. Poe GS, Johnson DL, Hillebrand DG. *Vital Root Retention in Dogs*. 1971 NDS-TR-019 July 1, National Dental Center, Bethesda, Md.
  16. Johnson DL, Kelly JF, Flinton RJ, Cornell MJ. Histological evaluation of vital root retention. *J Oral Surg* 1974; **32**: 829–833.
  17. Whitaker DD, Shankle RJ. A study of the histological reaction of submerged root segments. *Oral Surg* 1974; **37**: 919–935.
  18. Plata RL, Kelln EE, Linda L. Intentional retention of vital submerged roots in dogs. *Oral Surg* 1976; **42**: 100–108.
  19. Cook RT, Hutchens LH, Burkes EJ. Periodontal osseous defects associated with vitally submerged roots. *J Periodontol* 1977; **48**: 249–260.
  20. O’Riordan BC. Coronectomy (intentional partial odontectomy of lower third molars). *Oral Surg Oral Med Oral Pathol Oral Radiol Endod* 2004; **98**: 274–280.
  21. Pogrel MA. Coronectomy to prevent damage to the inferior alveolar nerve. *Alpha Omegan* 2009; **102**: 61–67.
  22. Freedman GL. Intentional partial odontectomy. *J Oral Maxillofac Surg* 1997; **55**: 524–526.
  23. Dolanmaz D, Yildirim G, Isik K, Kucuk K, Ozturk A. A preferable technique for protecting the inferior alveolar nerve: coronectomy. *J Oral Maxillofac Surg* 2009; **67**: 1234–1238.

## Abstracts

### IMPLANT RETAINED OVERDENTURES – IS LESS MORE?

Fracture incidence in mandibular overdentures retained by one or two implants. Gonda T, Maeda Y, Walton JN and MacEntee MI. *J Prosthet Dent* 2010; **103**: 178–181.

Many implant practitioners consider that, while two implants are the minimum required for a stable overdenture, more may be preferable for strength and support. In this novel piece of research, the authors randomly selected 85 patients who had their dentures supported either by two implants placed conventionally, bilaterally in the canine regions, or one implant placed centrally in the mandibular midline. The patients were monitored for up to five years.

It was found that there was no statistically significant difference in the incidence of fracture of the prosthesis between the two groups. Where fracture did occur it was related to the concentration of stresses around the support in both groups. It is suggested that reinforcing this area may be beneficial in either case.

It was stated in the paper that the goal of the research was to compare patient satisfaction, component costs, and treatment and maintenance time associated with mandibular overdentures retained by one or two implants. Although this paper merely reports the findings related to fracture incidence, it may well be that a single implant could prove to be an affordable treatment option for a patient who is unable to tolerate the mucosal support of a complete lower denture.

### COULD YOU QUOTE THIS ACT AND DOES YOU PRACTICE COMPLY?

The *Mental Capacity Act 2005*: its significance for Special Care Dentistry and patient care. Kaul A, Mudie D and Berman S. *J Disabil Oral Hlth* 2010; **11**: 21–24.

Whilst this paper is aimed primarily at those practitioners working in the field of special care dentistry who can expect a significant proportion of their case-load to comprise vulnerable adults who lack decision-making capacity, we all see such patients from time to time and it is essential that we comply with the relevant legislation. This paper presents three scenarios, based on the

authors’ experiences, to illustrate some of the situations which may be encountered. The scenarios may make an interesting exercise for a staff-training session under professional CPD. The actual relevant legislation was set out in two preceding papers in this edition of the journal, and all three together may prove a useful practice resource.

For example, the legislation provides for those patients at risk to be provided with a capacity assessment. However, suggesting that this be implemented may leave these patients feeling threatened, angry or aggrieved, and it is how these situations are dealt with that is addressed in this paper. All too often practitioners are familiar with the word of the Law but have never been called upon to apply it in a clinical situation. The experience of the authors presented in this paper would provide valuable lessons for those who may find themselves in this position. The legislation must be complied with and wider dissemination to patients, carers and clinicians can only improve the care of vulnerable adult patients.

**Peter Carrotte**  
Glasgow