

Classification, diagnosis and clinical manifestations of apical periodontitis

PAUL V. ABBOTT

‘Apical periodontitis’ is a general term used to describe the periapical inflammatory process that occurs in response to the presence of micro-organisms and other irritants within the root canal system of a tooth. Although many patients will develop apical periodontitis without having symptoms for a long period of time, it is very likely that there will be an acute exacerbation at some stage and then various signs and/or symptoms will become obvious. However, there are other conditions that can mimic apical periodontitis – such as an ‘extension’ of pulpitis, periodontal disease, occlusal trauma, an accident that has damaged the periodontal ligament, and various tumors or cysts. Hence, it is essential that dental practitioners understand the progressive nature of the periapical disease process as well as how and why the various stages occur so they can be diagnosed and managed appropriately. The diagnosis will usually be based on the clinical and radiographic manifestations and the results of the various tests that can be performed as part of a routine dental examination.

Introduction

The term ‘apical periodontitis’ is generally used to describe, and group together, the various periapical conditions that originate from pulp disease but there are a number of different pathological conditions that form this group of disorders (1). The processes involved are dynamic in nature and include many complex tissue interactions. During diagnosis and treatment, clinicians must understand the essence of these diseases, and their causes since variations in treatment approaches will be required for some of the conditions. It is also important to recognize that there are many other lesions that mimic ‘apical periodontitis’ because of their position and radiographic appearance. Table 1 lists disorders that can affect the jaws. All the listed conditions should be considered as part of the differential diagnosis of periapical pathosis. If such conditions are not diagnosed correctly, and expeditiously, then inappropriate treatment will be provided and the disease may progress with potentially serious consequences.

The relationship between pulp and periapical diseases

Most cases of apical periodontitis are associated with some form of pulp disease. A variety of factors are implicated, which can be grouped as short-term insults, trauma or long-term irritations (2). Typical short-term insults are those initiated by dentists during dental treatment – such as when cutting and drying a cavity. These insults generally cause an acute inflammatory response, which spontaneously resolves or heals if there is no further irritation. On the other hand, if the insult lasts for a longer period of time or is repeated, then such a long-term insult may lead to chronic inflammation and pulp necrosis (2), as outlined below.

Trauma can damage a dental pulp through the severing of apical blood vessels – for example by luxation and avulsion injuries – or by the rupture of intra-pulpal blood vessels, which will lead to intra-pulpal hemorrhage. The pulp may recover and repair (3) or it may necrose (4). If the apical blood vessels have

Table 1. Lesions of the jaws that may present as ‘periapical pathosis’ and should be considered as part of the differential diagnosis of such pathoses.

<i>EPITHELIAL CYSTS</i>	
Developmental odontogenic	Non-odontogenic
Odontogenic keratocyst	Nasopalatine duct cyst
Dentigerous cyst	Nasolabial cyst
Lateral periodontal cyst	
Glandular odontogenic cyst	
<i>NEOPLASMS AND OTHER TUMORS</i>	
Odontogenic	Non-Odontogenic
<i>BENIGN</i>	<i>BENIGN</i>
Ameloblastoma	Cemento-ossifying fibroma
Squamous odontogenic tumor	Neurofibroma
Calcifying epithelial odontogenic tumor	Neurilemoma
Clear cell odontogenic tumor	Osteoid osteoma
Ameloblastic fibroma	Osteoblastoma
Ameloblastic fibrodentinoma	Chondroma
Odontoameloblastoma	Idiopathic histiocytosis
Adenomatoid odontogenic tumour	
Calcifying odontogenic cyst	<i>MALIGNANT</i>
Odontogenic fibroma	Ewing’s sarcoma
Odontogenic myxoma	Chondrosarcoma
Benign cementoblastoma	Osteosarcoma
	Neurogenic sarcoma
<i>CARCINOMAS</i>	Carcinoma of the maxillary sinus
Malignant ameloblastoma	Malignant neural tumors
Primary intraosseous carcinoma	Burkitt’s lymphoma
Malignant variants of other odontogenic tumors	Metastatic carcinoma
Malignant changes in odontogenic cysts	Primary lymphoma of bone
	Plasma cell neoplasms
<i>SARCOMAS</i>	- Solitary plasmacytoma
Ameloblastic fibrosarcoma	- Multiple myeloma
Ameloblastic fibrodentinosa sarcoma	Malignant salivary gland tumors
Odontogenic carcinosarcoma	
<i>NON-NEOPLASTIC BONE LESIONS</i>	<i>INFLAMMATORY LESIONS</i>
Fibrous dysplasia	Radicular cysts (of pulpal origin)
Cemento-osseous fibroma and cemento-osseous dysplasias (including periapical cemental dysplasia and florid osseous dysplasia)	- Apical: true, pocket
Cherubism	- Lateral
Central giant cell lesions	- Residual
Central hemangioma of bone	Paradental cysts-including:
Aneurysmal bone cyst	- Inflammatory collateral cyst
Simple (traumatic/solitary/hemorrhagic) bone cyst	- Mandibular infected buccal cyst
	Periapical granuloma
	Condensing osteitis (idiopathic bone sclerosis)
	Periapical abscess
	Osteomyelitis
	Tuberculosis
<i>METABOLIC DISEASES</i>	
Paget’s disease (initial phase)	
Hyperparathyroidism	

been severed, revascularization may occur depending on the time until repositioning and the developmental stage of the apical foramen (5).

Essentially any break in the integrity of the external tooth surface by dental caries, chemical erosion, or cracks may result in long-term irritation of the pulp. In

these situations the dentine is exposed so bacterial elements may reach the pulp (6–8) and cause a tissue response (2). Pulp has a great capacity to withstand the bacterial challenge and initiate repair as long as there is no direct invasion of the tissue by the bacteria (9). The outcome of any dental treatment will be highly influenced by the capability of the pulp to withstand the irritation of either bacterial or iatrogenic origin (10, 11).

Without proper treatment, the pulp's inflammatory processes may spread and eventually pulp necrosis will occur. In conjunction with this spread of inflammation through the apical foramina, apical periodontitis may be induced. This process may occur with or without any symptoms (12). Following necrosis, there is no blood supply within the tooth to transport the all important defence cells that would normally be activated by the body in response to an infection. Hence, the bacteria are able to penetrate through the necrotic pulp towards the apical end of the root canal and they will eventually render the tooth pulpless as the bacteria remove the necrotic tissue. This was demonstrated in a study using monkeys when Jansson et al. (13) lacerated the pulps apically, left the pulp tissue within the canals and then infected the canals with plaque and by leaving them exposed to the oral cavity for 10–14 days. One group of teeth was then closed with a zinc oxide-eugenol temporary filling while the other group was left open. Radiographs were taken and the teeth were examined histologically after various time intervals. In the 'closed' group, the root canals were void of pulp tissue (i.e., 'pulpless') after just 1 month while the 'open' group took 2 months to become pulpless. The different time interval was most likely related to different growth conditions in the 'closed' canals favoring anaerobes, which are more virulent and more destructive (13).

Figure 1 shows the general stages of disease progression in any tissue as a result of a stimulus or irritant that is not removed or treated – the first tissue reaction is inflammation, which will be followed by necrosis, then infection and eventually loss of tissue because of its ingestion by bacteria. An example of this progression of disease is untreated frostbite of the toes where the irritant is the extreme cold, which reduces the blood flow to the extremities. Eventually untreated frostbite will manifest as gangrene and sloughing off of the toes such as that experienced by early explorers crossing the Antarctic continent to reach the South Pole.

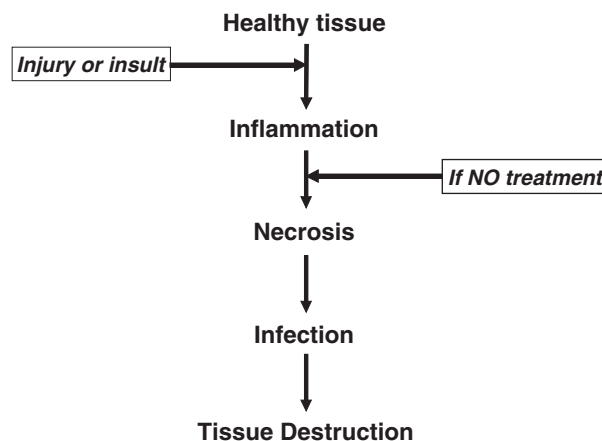


Fig. 1. The general stages of disease progression in any tissue as a result of a stimulus or irritant that is not removed or treated.

When considering the progression of pulp diseases through these similar stages, the stimulus is usually bacteria, as outlined above. The presence of bacteria within the root canal system will also eventually cause a periapical inflammatory response, known as apical periodontitis. This is the response of the body's defense system to the irritation created by the bacteria themselves as well as the irritation caused by their by-products such as exotoxins and lipopolysaccharides (1, 14–16).

The role played by bacteria in the progression of pulp and periapical diseases has been clearly demonstrated by, among others, Kakehashi et al. (17) who showed that pulp degeneration and necrosis following unrestored exposures to the oral environment in germ-free and conventional (germ-containing) rats only developed when bacteria were present and they were able to contaminate the tooth and the pulp space. Subsequently, Korzen et al. (18) showed that the periapical tissue reactions were directly related to bacterial invasion of the root canal and the periapical tissues generally will not become inflamed until the root canal becomes infected. When micro-organisms were found along the entire length of the root canal, the periapical inflammatory reaction was severe. However when the inoculum was limited, so was the periapical tissue reaction. Sundqvist (19) confirmed that periapical lesions were found in 18 of 19 cases where microbes were present in the canal and the size of the periapical radiolucency was directly related to the number of strains that could be isolated from the affected tooth.

Möller et al. (20) also confirmed in a study of primates that no periapical inflammatory reaction occurred in the absence of bacteria within root canals and Fabricius et al. (21) reported no inflammatory reactions associated with devitalized non-infected teeth except in two cases where the canals had been instrumented beyond the apical foramen while the pulp was being removed. In these two cases, the periapical inflammation was considered to be a direct result of mechanical damage by the files during the devitalization procedure (21).

Although bacteria are the most common cause of pulp diseases, dental pulps may also necrose for other reasons. A typical example is following trauma when the apical blood vessels are severed, as outlined above. In such cases, the presence of a necrotic pulp does not in itself imply that a chronic periapical inflammatory reaction will occur (1). Necrotic debris alone, although stimulating phagocytosis and tissue repair, will not produce enough irritation to sustain an inflammatory response in the periapical region (18–21).

Periapical inflammation is a direct result of interactions between the bacteria in an untreated infected root canal system and the host's defense or immune system (1). It begins as an acute inflammatory response but it is a dynamic situation that can change spontaneously throughout the disease process (Fig. 2). As there is no longer any blood supply to a necrotic pulp or into the root canal system in a pulpless tooth, the host's defense cells can not reach the source of the irritation (i.e., the bacteria in the canal) and therefore the body is unable

to eliminate the infection. Hence, a chronic inflammatory response develops in the periapical region and the intra-canal bacteria survive with nutrients being obtained from tissue fluid and inflammatory exudate that seep in to the root canal system through the apical foramen (22). Saliva and food substances may also penetrate through the original pathway of entry of the bacteria (i.e. caries, cracks or broken-down restoration margins) to help supply nutritional elements for the organisms. Infections of the root canal system usually consist of multiple species of organisms and complex interactions occur where the by-products of some bacteria contribute to the supply of nutrients for other species in a co-colonizing manner (22). Once an infection is established within the root canal system, the bacterial numbers will gradually increase through normal cell reproduction and proliferation mechanisms. The nutritional conditions in each canal may vary over time, which may explain the different rates of development of periapical responses and can also explain why there are varying numbers of bacteria that can be recovered from root canals during sampling procedures.

In summary, periapical inflammation is generally a direct effect of bacterial infection of the root canal system. Therefore, when assessing teeth, it is mandatory to examine and diagnose the status of both the pulp and the periapical tissues. In addition, clinicians should also determine the cause(s) of the disease(s) since the first principle of treating any disease is to remove its cause in order to adequately treat the disease and prevent its

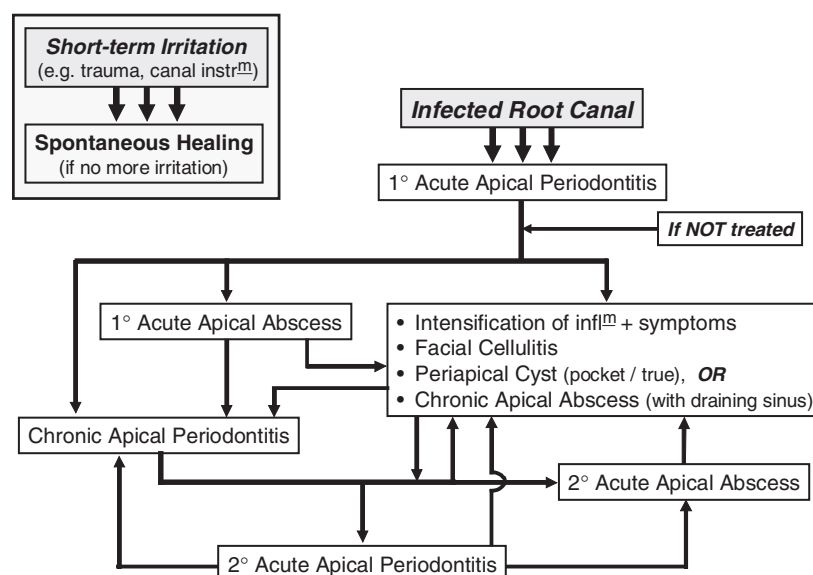


Fig. 2. Progression of periapical diseases through different stages of the disease process.

recurrence – in the case of pulp and periapical diseases, this implies that any pathways of entry for the bacteria should be identified so they can be removed as part of the clinical management of the tooth (23). When diagnosing apical periodontitis, it is important for clinicians to realize that the most common cause is an infected root canal system but there may also be other causes – hence an accurate diagnosis is essential.

Periapical inflammation without pulp infection

Apical periodontitis may develop without the root canal system being infected. Traumatic occlusion is one such example where the inflammation is caused by continuous, and constant, irritation to the periodontal ligament during function as a result of a premature occlusal contact or an occlusal interference during lateral and/or protrusive movements of the mandible (24, 25). The trauma is a long-term irritation, which causes a non-healing bone resorptive process to occur.

Other forms of trauma may cause apical periodontitis – such as luxation and avulsion injuries when the tooth is displaced by a violent force (3, 26). In these situations, the periodontal ligament is directly damaged and is likely to be torn or completely severed. Acute inflammation is the first response to the injury and then repair will usually follow provided the tooth is repositioned and stabilized correctly or if the tooth is extracted. If the treatment is not adequate, then chronic inflammation may result (26).

Periapical radiographs may falsely suggest an area of apical periodontitis without infection of the root canal system when there is extensive periodontal disease and the pocket has extended beyond the level of the root apex (27). In this situation, substantial breakdown of the supporting tissues and loss of bone (either labially or lingually) creates a radiolucency, which is superimposed over the periapical region giving the appearance of apical periodontitis (see Fig. 3). This situation is different to the rare situation, which can occur when the periodontal pocket truly involves the apical foramen and the blood supply of the pulp is severed – this situation leads to pulp necrosis and infection of the root canal system (28).

Pulpitis may also cause symptoms of apical periodontitis (29, 30) typically, tenderness to biting pressure and percussion (Fig. 4). It is more common with irreversible pulpitis but it may also occur with reversible pulpitis. It should be noted that both forms of pulpitis are

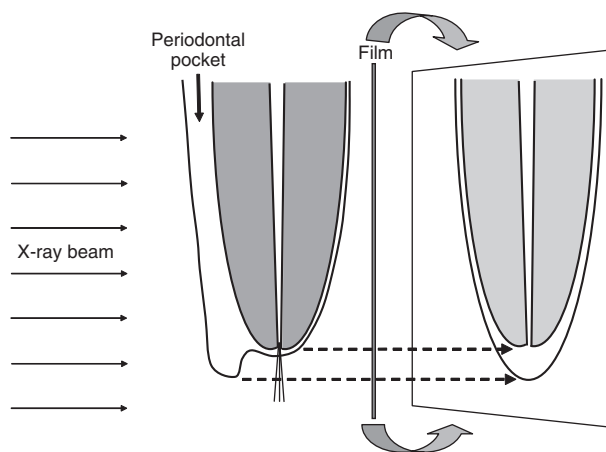


Fig. 3. Diagram showing how a periodontal pocket with extensive loss of labial bone can mimic a periapical radiolucency. Note that the apical blood vessels and nerve supply are intact. If the tooth is not carefully examined and tested with pulp sensibility tests, this radiographic 'lesion' could be mistaken as being a sign of chronic apical periodontitis because of pulp necrosis and infection of the root canal system.

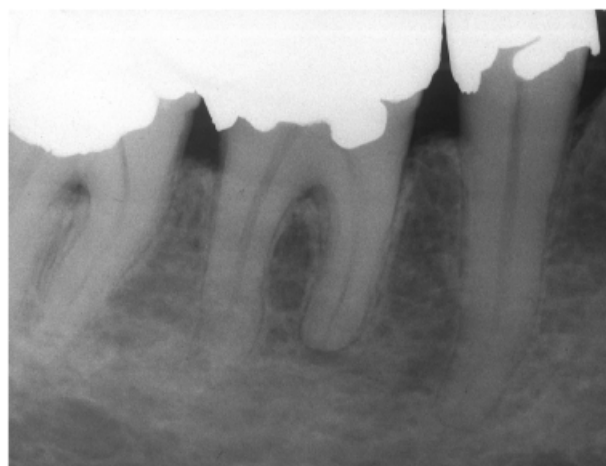


Fig. 4. The lower right first molar tooth had acute irreversible pulpitis and acute apical periodontitis as a result of breakdown of the large amalgam restoration. The patient presented with spontaneous pain, extreme sensitivity to heat and cold, awakening at night and considerable tenderness to percussion and pressure on the tooth. Note the normal periodontal ligament space and lamina dura around the apex of the distal root while there is widening of the ligament space and loss of lamina dura around the apex of the mesial root.

inflammatory conditions of the pulp so most clinicians do not consider the canal to be infected during these stages of the disease process. However, pulpitis is usually caused by the presence of micro-organisms somewhere within the tooth structure, but not necessarily within the

pulp tissue itself although some bacterial invasion of the tissue is to be expected in cases of irreversible pulpitis (31). The presence of bacteria may cause apical periodontitis as demonstrated by Korzen et al. (18). However, a more likely scenario is that apical periodontitis is merely an 'extension' of a pulpal inflammatory process, which is inhibited by the confines of the root canal walls and has only one direction to follow as it spreads – that is through the apical foramen (32).

Periapical diseases

Apart from the situations outlined above, apical periodontitis should be considered as an inflammatory reaction to the presence of bacteria within the root canal system. Bacteria do not need to be present within the periapical tissue *per se* to cause apical periodontitis (1). Chronic periapical inflammation represents a 'balance' between the bacteria in the tooth and the host response. Once this 'balance' is disturbed, an acute inflammatory reaction will develop (1) with severe symptoms. This may occur spontaneously as a result of different factors produced locally at the site of the ongoing inflammatory reaction, or as a result of an immune reaction.

Classifications of periapical diseases

The World Health Organization (33) has classified apical periodontitis in five categories:

- Acute apical periodontitis of pulpal origin
- Chronic apical periodontitis of pulpal origin
- Periapical abscess with sinus
- Periapical abscess without sinus
- Radicular cysts.

Since this classification does not account for the structural aspects of periapical lesions (1), Nair proposed an alternative classification in 1997, which was based on the histopathology and dynamics of these lesions with strict criteria to define each entity (1). Nair's criteria also included the distribution and type of inflammatory cells within the lesion, the presence or absence of epithelial cells, whether the lesion had transformed into a cyst and, if so, the relationship of the cyst-cavity to the apical foramen of the root canal of the affected tooth. Nair's classification (1) of periapical radiolucencies can be summarized as follows:

- Acute apical periodontitis – primary or secondary
- Chronic apical periodontitis

- Apical abscess – acute or chronic
- Periapical cyst – true or pocket.

It is well accepted by the profession that it is not possible to clinically diagnose the true histological state of the pulp and the periapical tissues since the symptoms can vary considerably, depending on the stage of the disease process when the patient presents for treatment. Studies have attempted to correlate the clinical signs and symptoms with the histological findings but these attempts have merely led to confusion and disagreement about the terminology used (34). In addition, more recent research has shown that periapical radiolucencies may also be because of other conditions such as extra-radicular infections (35–38), foreign body reactions (39, 40), or scar tissue (41). Hence, it is timely to revise the classifications used for pulp and periapical diseases to include these and other related periradicular conditions. Table 2 outlines the author's alternative, yet simple and practical, classification system that uses terminology based on findings that can be obtained during the clinical and radiographic examinations of patients (42). This classification also incorporates Nair's proposals and it can be used for the clinical diagnosis of the status of the periradicular (periapical and lateral periodontal) tissues but excluding diseases of the marginal periodontium (commonly referred to as 'periodontal diseases'). It is

Table 2. A clinical classification of the status of the periradicular tissues.

(a) Clinically normal periapical/periradicular tissues	
(b) Apical periodontitis - <i>Acute</i> :	Primary
	Secondary (or acute exacerbation)
	- <i>Chronic</i> : Granuloma
	Condensing osteitis
(c) Periapical cyst - <i>True cyst</i>	
- <i>Pocket cyst</i>	
(d) Periapical abscess - <i>Acute</i> :	Primary
	Secondary
	- <i>Chronic</i>
(e) Facial cellulitis	
(f) Extra-radicular infection	
(g) Foreign body reaction	
(h) Periapical scar	
(i) External root resorption - <i>Surface</i>	- <i>Inflammatory</i>
	- <i>Replacement</i>
	- <i>Invasive</i>
	- <i>Pressure</i>
	- <i>Orthodontic</i>
	- <i>Physiological</i>

more comprehensive than the classifications outlined by Nair and the World Health Organization since it includes 'normal' tissue (which is an entity that must be recognized whenever there are no signs of disease), and periapical conditions associated with teeth that have had previous endodontic treatment. Root resorptive defects have also been included since they are conditions affecting the periradicular tissues. Some resorptive processes are endodontic in origin and others may be mistaken as such – hence it is important for clinicians to recognize and correctly diagnose resorptive lesions when assessing the periapical status of teeth.

The terms 'acute' and 'chronic' have been used in this classification as indicators of clinical conditions based on the patient's perception of their pain; that is, they have *not* been used from a histological perspective since it is impossible to know the true histological state of the tissues and this is likely to vary from one case to another, or even from time to time with the same tooth. Hence, in this classification 'acute' is used to describe a case with moderate-to-severe symptoms, while 'chronic' indicates either no symptoms or only mild symptoms. Some other suggested classifications use terms such as 'symptomatic apical periodontitis' and 'asymptomatic apical periodontitis' but these can be confusing and misleading since many conditions can be both symptomatic and asymptomatic at different stages of the disease process. In addition, these terms do not account for the different pathological entities that occur during the progression of periapical disease through its various stages. Each stage of periapical disease should be considered as part of a continuum of stages that occur during the development and progression of the disease processes. Thus, the use of the terms 'symptomatic apical periodontitis' and 'asymptomatic apical periodontitis' does not help clinicians to differentiate between the various stages of the diseases.

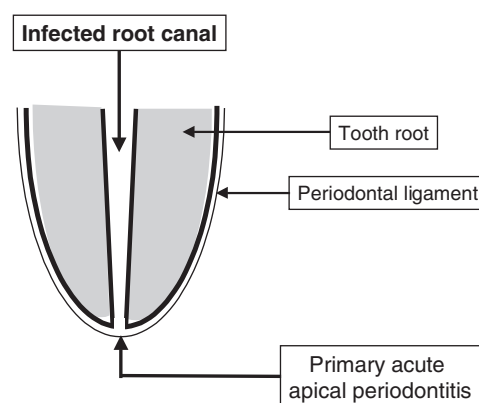
Some of the conditions listed in Table 2 may be acute or chronic in nature, as listed, and the chronic conditions may have acute exacerbations at any time. The periapical disease process is dynamic in nature and hence each condition may progress to several other conditions (see below and Fig. 2). The classification outlined in Table 2 should help clinicians understand the progressive nature of the disease process while also directing them towards the correct and most conservative therapy for each condition.

Pulp and periapical diseases are progressive in nature (1) and hence the signs and symptoms along with the

clinical and radiographic findings will vary according to the stage of the disease at the time of examination. If no intervening treatment is provided, periapical diseases will typically follow a sequence of events (Fig. 2) that has been summarized below and outlined in detail in a comprehensive review by Nair (1).

An infected root canal system is a reservoir for bacteria that cause apical periodontitis and it will continue until appropriate treatment is provided. This apical inflammatory reaction serves two purposes – one is to try to remove the bacteria while the other is to prevent microbial invasion into the periapical tissues (1). The former purpose is unattainable because of the lack of blood supply in the canal whereas the latter is generally successful but only until local or systemic changes occur to alter the 'balance' situation described above. This is when a chronic situation is likely to become acute and the patient may seek treatment because of the presence of symptoms.

The initial periapical response to bacterial presence within the canal or to bacterial invasion of the periapical region will be an acute inflammatory response, known as primary acute apical periodontitis (1). Such a reaction may also be caused by trauma, or by endodontic instrumentation procedures and irritant materials. Primary acute apical periodontitis occurs within a previously healthy periapical region (Fig. 5) and it is



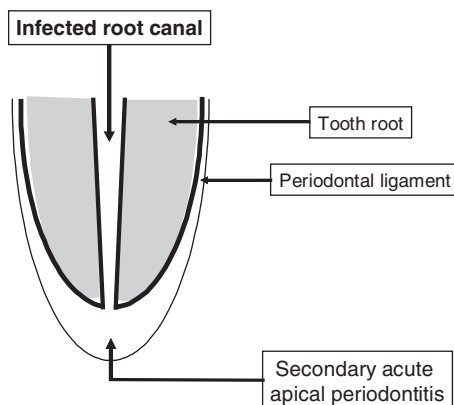
Primary Acute Apical Periodontitis

Fig. 5. Diagrammatic representation of the radiographic appearance of primary acute apical periodontitis – although there is a periapical inflammatory response, it is not yet evident radiographically as there has been no bone or root resorption to create a widening of the periodontal ligament space or a radiolucency. (Note: other conditions that may appear similar include primary acute apical abscess and facial cellulitis associated with a primary abscess.)

usually of short duration. If no treatment is provided, it may then follow any one or more of several possible courses (Fig. 2) – such as healing, further intensification, abscess formation (i.e. primary apical abscess), development of a sinus tract (i.e. chronic apical abscess), spreading of the infection through bone and/or soft tissues (i.e. cellulitis), cyst formation, or it may become chronic (i.e. chronic apical periodontitis) (1). Healing will only occur if no further irritation occurs to sustain the reaction and if there are no micro-organisms within the canal – such as following some traumatic incidents or after endodontic treatment has been completed.

Secondary acute apical periodontitis (Fig. 6) is an acute exacerbation of an already existing chronic apical periodontitis lesion (1). This may occur in the form of an abscess (secondary apical abscess) when bacteria migrate out of the root canal to infect the periapical tissues, although other local or systemic changes may also cause an acute exacerbation of the inflammation.

If treatment is still not provided, then there will be a continued presence of irritants in the apical part of the root canal system so the initial acute inflammation gradually shifts to a chronic inflammatory reaction, known histologically as a periapical granuloma. Clinically, this is usually seen as an asymptomatic radiolucency and it reflects a state of quiescence, or ‘balance’ with the microbes being confined to the canal. A



Secondary Acute Apical Periodontitis

Fig. 6. Diagrammatic representation of the radiographic appearance of secondary acute apical periodontitis. (Note: other conditions that may appear similar include secondary acute apical abscess, facial cellulitis associated with a secondary abscess, extra-radicular infection, chronic apical periodontitis, periapical granuloma, chronic apical abscess, periapical scars and periapical cysts – pocket and true.)

periapical granuloma may remain dormant for long periods of time, but the equilibrium can be disturbed at any time by any factor that favors the growth and/or migration of the microbial flora. Bacteria may then migrate from the canal into the periapical tissues and the chronic inflammation will become acute, manifesting as secondary acute apical periodontitis or as a secondary apical abscess (1) with clinical signs and symptoms of varying intensity. At this stage of the disease process, micro-organisms may be found in the extra-radicular tissues and bone resorption occurs with rapid enlargement of the radiolucency. Some patients may not experience symptoms that are severe enough to seek treatment so the acute reaction may again take any one of several possible courses, such as: further intensification, abscess formation (secondary apical abscess), development of a sinus tract (chronic apical abscess), spreading through bone and/or soft tissues (cellulitis), cyst formation, or it may become chronic apical periodontitis again (1).

Periapical Cysts

In the past, cysts were often implicated as a major cause of periapical disease but previous concepts about cysts were erroneously based on histological studies with inadequate sectioning and examination techniques where the mere presence of epithelium resulted in the diagnosis of a cyst. In 1996, Nair et al. (43) demonstrated that serial sectioning and strict histopathological criteria are required since epithelium is present in over 50% of all apical periodontitis lesions (i.e., granulomata, abscesses and cysts) and therefore the mere presence of epithelium is an insufficient criterion for the diagnosis of a cyst to be reached. The entire biopsy (i.e., the soft tissue and the tooth apex) must be examined in order to determine whether the epithelium forms a *complete capsule* around the periphery of the lesion and whether there is any communication with the root canal system (43).

Nair has defined two types of periapical cysts: periapical pocket cysts and periapical true cysts (43, 44). A *periapical pocket cyst* is a sac-like epithelium-lined cavity that is open to, and continuous with, the root canal (Fig. 7) whereas the lumen of a *periapical true cyst* is completely enclosed by the epithelial lining and there is no communication with the root canal (Fig. 8).

Periapical cysts are believed to be a direct sequel of a periapical granuloma although not every granuloma

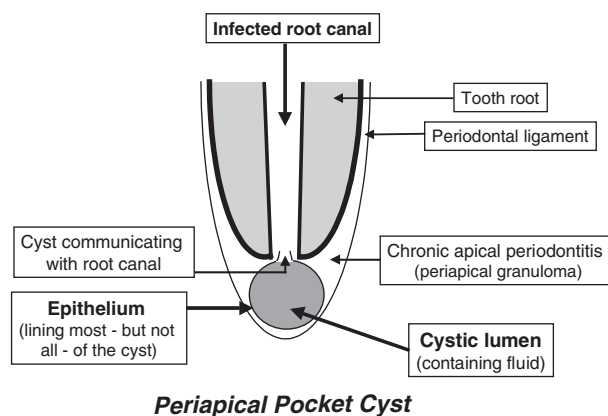


Fig. 7. Diagrammatic representation of a periapical pocket cyst.

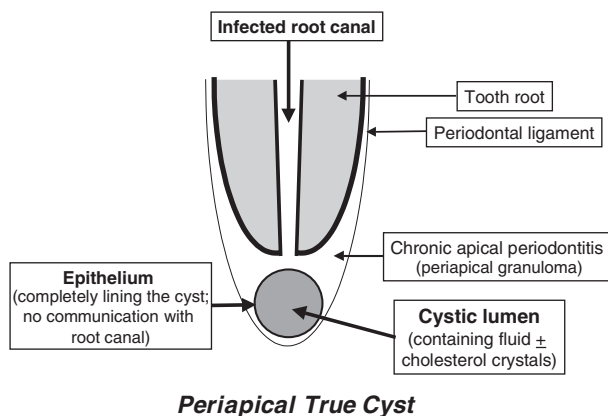


Fig. 8. Diagrammatic representation of a periapical true cyst.

will develop into a cyst (1). The prevalence of periapical cysts among apical periodontitis lesions has been assessed in several studies with figures ranging from 6% to 55% (43, 44). When strict histological criteria were used by Nair et al. (43) only 15% of the lesions studied were identified as cysts – 9% were periapical true cysts and 6% were periapical pocket cysts.

Although it is not possible to clinically distinguish between periapical pocket cysts and periapical true cysts since their clinical and radiographic features are identical, it is important for clinicians to be aware of their structural differences and the implications of these differences since their responses to endodontic treatment may be quite different. Periapical pocket cysts communicate with the root canal (Fig. 7) and therefore it is believed that they are likely to heal following conventional endodontic treatment since the source of irritants within the root canal will be removed during this treatment (1). In contrast, once the lesion has

become a periapical true cyst, it does not depend on the presence or absence of irritants within the canal (since there is no communication with them) and therefore true cysts are believed to be ‘self-sustaining’ lesions, which will require surgical removal (1, 43, 44). In addition, 29–43% of periapical true cysts contain cholesterol crystals (43–46) that are believed to be released from disintegrating cells, blood vessels and circulating plasma lipids, and it is thought that these crystals may also prevent the spontaneous repair of true cysts (46). The pathway of development and the histological appearance of stratified squamous epithelial lining and the rest of the pocket cyst wall are similar to those of a true cyst (1, 43, 44). Hence, it is feasible to suggest, although not yet proven, that a pocket cyst may detach from the root apex and the epithelial lining may completely close to form a true cyst.

Signs and symptoms of periapical conditions

As outlined above, periapical diseases are usually a result of pulp disease and hence the signs and symptoms of periapical disease will be present in conjunction with the signs and symptoms of the concurrent pulp disease. Hence, the diagnosis must include an assessment of the condition of both the pulp (or root canal) and the periapical region, together with an assessment of the cause of these diseases (23). The following discussion is limited only to the signs and symptoms of periapical conditions and readers should assume that the relevant pulp (or root canal) condition and its cause have also been diagnosed. Many of the signs and symptoms overlap between the various periapical conditions because of the dynamic interactions that occur and hence the following descriptions are only guides to the typical findings (42).

Clinically normal periapical tissues

The tooth is not tender to percussion or pressure, and there is no tenderness to palpation of the mucosa overlying the periapical region. There is no swelling and there are no symptoms noted by the patient. Radiographically, the lamina dura is intact and the periodontal ligament space has a normal and consistent width around the entire root(s) of the tooth. The width of the periodontal ligament space should also be similar to that of the adjacent teeth.

Apical periodontitis

Teeth with *primary acute apical periodontitis* will have very marked tenderness to percussion and pain when pressure is applied to the tooth. Radiographically, the periodontal ligament space and lamina dura may appear normal (Fig. 5) or there may be just a slight thickening of the periodontal ligament space and some loss of the lamina dura around the apex of the tooth root (Fig. 4). The tooth may have increased mobility and the onset of the pain is usually sudden and unexpected. The patient will be aware of considerable pain, soreness to biting and touching the tooth, and possibly a feeling of pressure building up in the periapical region.

A patient with *secondary acute apical periodontitis* will be aware of similar pain symptoms to those present in primary acute apical periodontitis but there will be more clinical and radiographic signs present (Fig. 6) to assist the diagnosis since it is an acute exacerbation of an

established chronic apical periodontitis lesion. There may be a history of previous episodes of pain or discomfort but many patients will not remember such details (12). Radiographically, there will be a radiolucency surrounding the apex of the involved tooth and there will be loss of the lamina dura (Figs 6 and 9). The size of the radiolucency will depend largely on how long the chronic apical periodontitis has been present – it can range from being just a widened periodontal ligament space in early cases to a large radiolucent area if present for a long time. However, these lesions progress at varying rates so the size of the area is not necessarily indicative of the time it has been present.

Chronic apical periodontitis will vary in its clinical presentation since this general term represents different histological conditions of the periapical disease process. Usually patients are unaware of any symptoms associated with these lesions, which are often only noted as incidental findings during a routine radiographic examination. The pulp will be necrotic and infected, or otherwise the root canal will be pulpless and infected, or previously root-filled and infected. There will be no response to pulp sensibility tests and a radiograph will show a periapical radiolucent area (Fig. 10). The tooth is not tender to percussion, pressure or palpation but it may feel ‘different’ to these tests and it may be slightly mobile.

The most common chronic periapical condition encountered is a *periapical granuloma* and the clinical

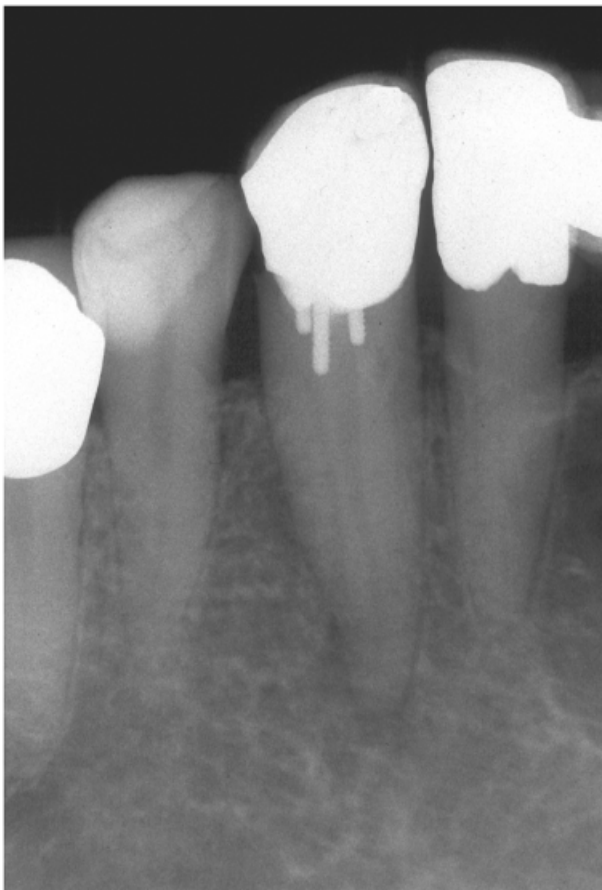

Fig. 9. The lower right canine has secondary acute apical periodontitis. There is a periapical radiolucency and the tooth was quite tender to percussion. The tooth did not respond to cold or electric pulp sensibility tests.

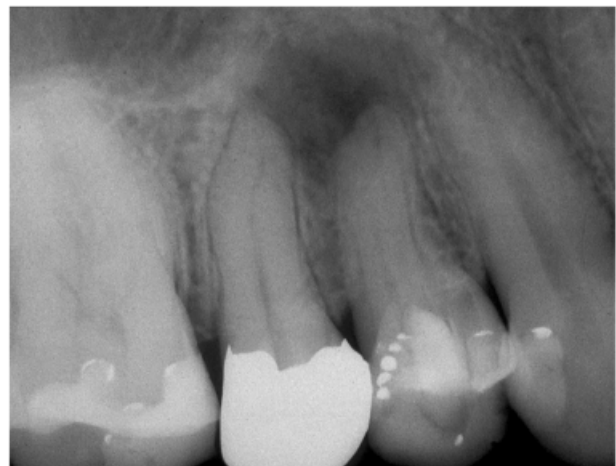

Fig. 10. The upper right first premolar has chronic apical periodontitis. The tooth did not respond to cold or electric pulp sensibility tests and the coronal restoration was clinically unsatisfactory. There is a periapical radiolucency but the tooth was not tender to percussion or palpation, and there were no other signs or symptoms.

diagnosis of a granuloma is usually based on the radiographic appearance of a periapical radiolucency (similar to that shown in Figs 6 and 10) or a thickening of the periodontal ligament space. A granuloma can only be accurately diagnosed via a surgical biopsy and a histological examination so most clinicians will use the simple term of 'chronic apical periodontitis' to describe this entity. There are usually no symptoms or just a mild awareness of the tooth feeling different when pressure is applied to it. Radiographically, there will be a radiolucency surrounding the apex of the involved tooth and there will be loss of the lamina dura. If there is any pulp tissue remaining in the canal, then it will be necrotic and infected. Otherwise the root canal will be pulpless and infected, or previously root filled and infected. There will be no response to pulp sensibility tests.

Chronic apical periodontitis can occasionally present as *condensing osteitis* (also known as *idiopathic bone sclerosis*) (Fig. 11). This can be easily distinguished from other chronic periapical conditions by its radiographic appearance since the periapical bone will appear more radiopaque than normal bone. Some cases may also have a slightly widened periodontal ligament space between the tooth root and the radiopacity. The pulp tissue may be chronically inflamed (chronic irreversible pulpitis), in which case it should respond to pulp sensibility tests. Alternatively, the pulp may have been chronically inflamed for a long time but necrosed at some stage (possibly without symptoms) prior to the

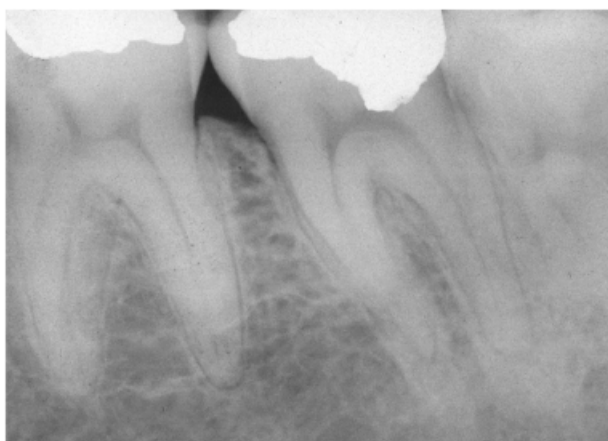

Fig. 11. Periapical radiograph of a lower left second molar tooth that presented with a long-standing history of mild sensitivity to heat and cold stimuli. The tooth was diagnosed as having chronic irreversible pulpitis and chronic apical periodontitis in the form of condensing osteitis, which was associated with both roots.

time when the patient reports to a dentist for treatment, in which case there will be no response to pulp sensibility tests.

Both *periapical true cysts* and *periapical pocket cysts* are considered to be forms of chronic apical periodontitis. As with other chronic periapical conditions, there are usually no symptoms and the clinical diagnosis is based on radiographic findings. However, the final diagnosis of a cyst can only be made by histological examination of a biopsy that includes the root apex, and with comprehensive serial sectioning (1, 43). Hence it is impossible to differentially diagnose a cyst just with the findings obtained during clinical and radiographic examinations.

Periapical granulomata and radicular cysts generally have exactly the same clinical and radiographic appearance. Although there are histological differences between these conditions, they cannot be differentiated clinically. The appearance of the borders of the radiolucency can not be used as diagnostic criteria to distinguish between these conditions, as previously attempted by many clinicians who have incorrectly claimed that a well-defined border indicates a radicular cyst. It is now accepted that a well-defined border only indicates a long-standing lesion that is slowly increasing in size whereas a diffuse border is more likely to indicate a rapidly expanding lesion. The size of the radiolucency is also irrelevant to the histological state of the tissue as both small and large lesions can be granulomata, abscesses or cysts. Since granulomata and radicular cysts are difficult to differentially diagnose and since the initial treatment for each is identical (i.e., orthograde endodontic treatment), they can be clinically classified with the general term 'chronic apical periodontitis'. These disease processes are dynamic and the pathological entities are interchangeable, thus this more generalized diagnostic term is often more valuable for clinical use. Unfortunately, further confusion may arise if other conditions, such as apical abscesses, extra-radicular infections and periapical scars are considered since these conditions also have similar radiographic and clinical appearances.

Periapical abscess

An abscess is defined as 'a localized collection of pus' and this term should only be used when there is evidence of pus formation and collection. Apical abscesses may be either acute or chronic, and an acute apical abscess may be either a primary or secondary

lesion. An acute abscess that develops as a sequel to primary acute apical periodontitis is known as a *primary acute apical abscess* whereas an acute abscess that develops as a sequel to secondary acute apical periodontitis or chronic apical periodontitis is called a *secondary acute apical abscess* (1). Both forms of acute abscess can be very painful conditions characterized by intense throbbing and extreme pain to light pressure, biting, touching and percussion. These symptoms may be accompanied by tenderness to palpation and increased mobility of the tooth. Systemic signs of malaise, fever and lymph node involvement may or may not occur. An intra-oral and/or extra-oral swelling may be present and this swelling will be fluctuant as well as tender to pressure and palpation. The tooth responsible for the abscess will have a necrotic and infected pulp, or a pulpless and infected root canal system, or it may have had previous endodontic treatment with continued or subsequent infection of the root canal system. A primary acute apical abscess may not have any periapical changes evident on a radiograph or there may be just a slight thickening of the periodontal ligament space because of the periapical inflammation and fluid build-up causing extrusion of the tooth from its normal position in the socket. In contrast, a secondary acute apical abscess will have a periapical radiolucent area (Fig. 12) since it is a sequel to secondary acute apical periodontitis (which is also known as an acute exacerbation of chronic apical periodontitis).

A *chronic periapical abscess* is not usually associated with pain and is typically characterized by the clinical presence of a draining sinus on the oral mucosa (Fig. 13) or occasionally on the facial skin. However, a draining sinus will only be evident when drainage is occurring, and this drainage will generally only occur when pressure is built up within the periapical region. Hence some periapical radiolucencies, which do not clinically appear to be an abscess may be histologically diagnosed as such because of the localized collection of pus seen in a biopsy section. Radiographically, a chronic apical abscess will have a periapical radiolucency and evidence of causative factors (e.g. caries). If a gutta percha point is placed into the draining sinus prior to exposing a periapical radiograph, then the culprit tooth can usually be identified quickly (Fig. 13B). However, the usefulness of this diagnostic aid depends on the draining sinus tract being patent at the time of examination. A chronic apical abscess can revert back to being a granuloma again if there is no further

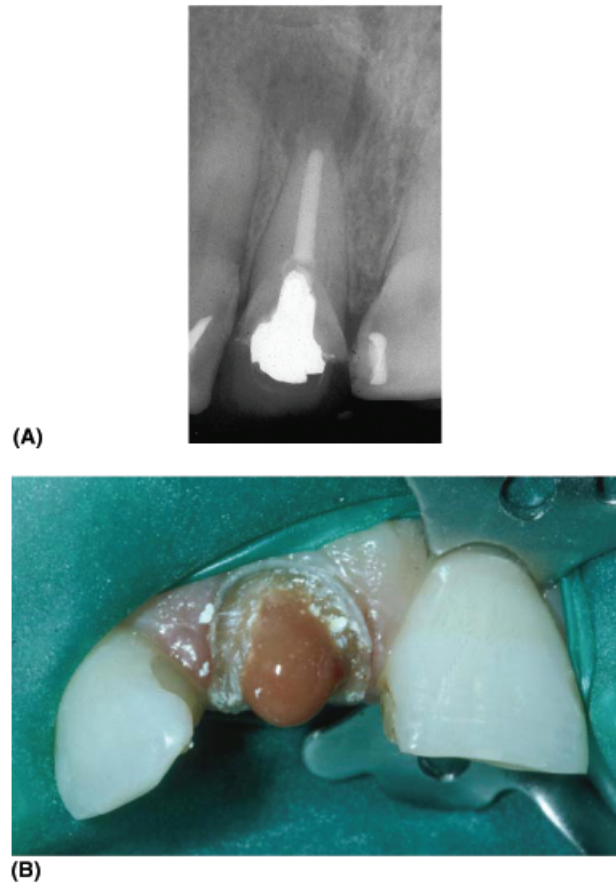
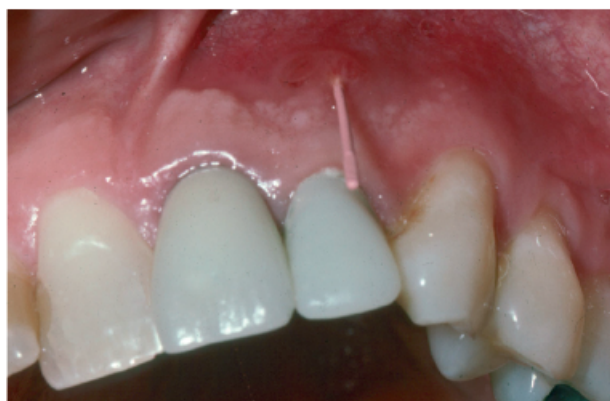

Fig. 12. The upper right central incisor had an infected root canal system and a secondary acute apical abscess as a result of breakdown of the crown restoration. The patient presented with extreme tenderness to percussion and pressure on the tooth as well as systemic signs of fever and malaise. (A) The pre-operative periapical radiograph showed a periapical radiolucent area, a previous root filling, a short post and a crown. (B) Drainage was readily established via the canal once the restoration and root filling were removed.

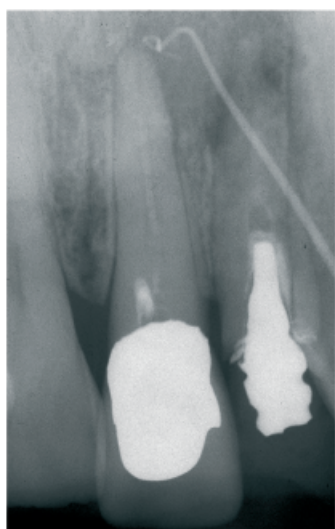
production of pus, or it can become an acute apical abscess if drainage is inhibited and pressure builds up within the lesion. A chronic apical abscess can also transform to become a cyst, which can revert back to being an abscess if bacteria enter the lesion and then pus forms and collects in the lumen.

Facial cellulitis

Facial cellulitis (Fig. 14) occurs when the infection spreads between the fascial planes because of the tissue dissolving capacity of extra-virulent organisms. Facial cellulitis usually begins as an apical abscess, although symptoms may not have been present previously.



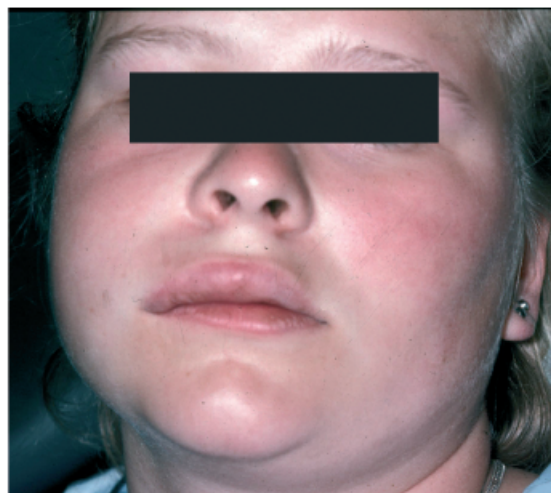(A)



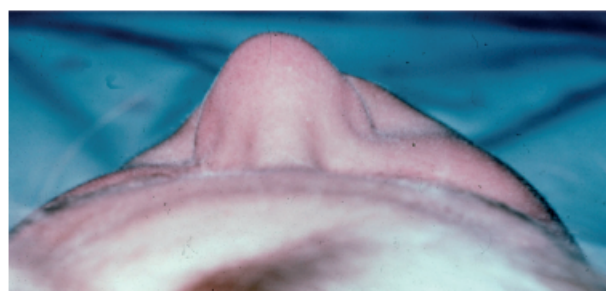(B)

Fig. 13. A draining sinus is evident on the labial aspect of the upper left lateral incisor. (A) A gutta percha (GP) point has been placed into the draining sinus in order to trace its origin. (B) The radiograph taken with the GP point in the sinus shows that it tracks from the periapical region of the upper left central incisor, which has a chronic apical abscess, an infected root canal system, and a technically inadequate root canal filling. The lateral incisor also has an infected root canal system and chronic apical periodontitis but this tooth is not associated with the draining sinus.

Cellulitis may be a sequel to a chronic apical abscess, a primary acute apical abscess or a secondary acute apical abscess. The spread of pus follows the pathway(s) of least resistance, which usually implies the fascial planes between the muscles of the face, head and neck. Spreading infections have the potential to have serious, and even life threatening, consequences if not treated (47) and therefore immediate and aggressive therapy is indicated. Several systemic complications arising from spreading dental infections have been reported in the literature – such as, osteomyelitis (48, 49), Ludwig's angina (50),



(A)



(B)

Fig. 14. A 20-year female presented with facial cellulitis and a primary acute apical abscess caused by a pulpless, infected root canal system in her upper right lateral incisor. She had fever, malaise, and lymph node involvement. The tooth was quite mobile, tender to percussion and painful to light pressure. The facial expression and patient demeanour also indicated that she was unwell. (A) Note the facial swelling and the difference between the left and right sides of her face. (B) The facial swelling is more obvious when viewed from above and behind the patient.

actinomycosis (51), orbital cellulitis (52), cavernous sinus thrombosis (53), brain abscess (54, 55), mediastinitis (56) and neurological complications (57). In cases where the bacteria and their toxins enter the blood circulation, fatal consequences may arise from septic shock (58), bacteraemia (59, 60) and septicaemia (61).

Some of the features of cellulitis caused by an infected root canal system will be similar to those of an acute periapical abscess (i.e., severe pain, tenderness to percussion and light touch, tooth mobility, malaise, fever, lymph node involvement, etc.) since the cellulitis is usually a sequel of an untreated or rapidly developing abscess. However, the swelling of a cellulitis is far more severe and widespread than with an acute apical abscess,

and it is usually less fluctuant with a 'harder feel' to palpation. The tooth causing the cellulitis will have a necrotic and infected pulp, or a pulpless and infected root canal system, or it may have had previous endodontic treatment with continued or subsequent infection of the root canal system. Radiographically, cellulitis may or may not have a periapical radiolucency – this will depend on whether it is a sequel to a primary apical abscess (no radiolucency or just a widened periodontal ligament space) or to a secondary apical abscess (a radiolucency will be present).

Extra-radicular infection

An extra-radicular infection occurs when micro-organisms establish colonies on the external root surface within the periapical region. It is usually a sequel to an infected root canal system with the extra-radicular bacterial species being similar to those found in root canals (1, 35–38). Extra-radicular microbes can also be found in other situations such as in apical abscesses, long-standing draining sinuses, infected radicular cysts (especially pocket cysts), periapical actinomycosis, and with infected dentine pieces that have been displaced into the periapical tissues during endodontic treatment (1). There may be no symptoms, or, the symptoms may be the same as those for a periapical abscess – that is, either an acute or chronic abscess, depending on the stage of the periapical disease process and whether drainage can occur via a draining sinus. An extra-radicular infection will present with the same radiographic appearance as a granuloma, an abscess, a periapical pocket cyst, a true cyst and a periapical scar. The tooth associated with the extra-radicular infection will have a necrotic and infected pulp, or a pulpless and infected root canal system, or it may have had previous endodontic treatment with continued or subsequent infection of the root canal system (Fig. 15). Extra-radicular infections can only be diagnosed by histological examination with appropriate techniques for the identification of microbes in a biopsy taken during surgical removal of the lesion. If signs or symptoms persist following proper conventional endodontic treatment, then an extra-radicular infection may be the cause and surgery should be considered.

Foreign body reaction

A foreign body reaction is an inflammatory response to a foreign material within the periapical tissues (1, 39,

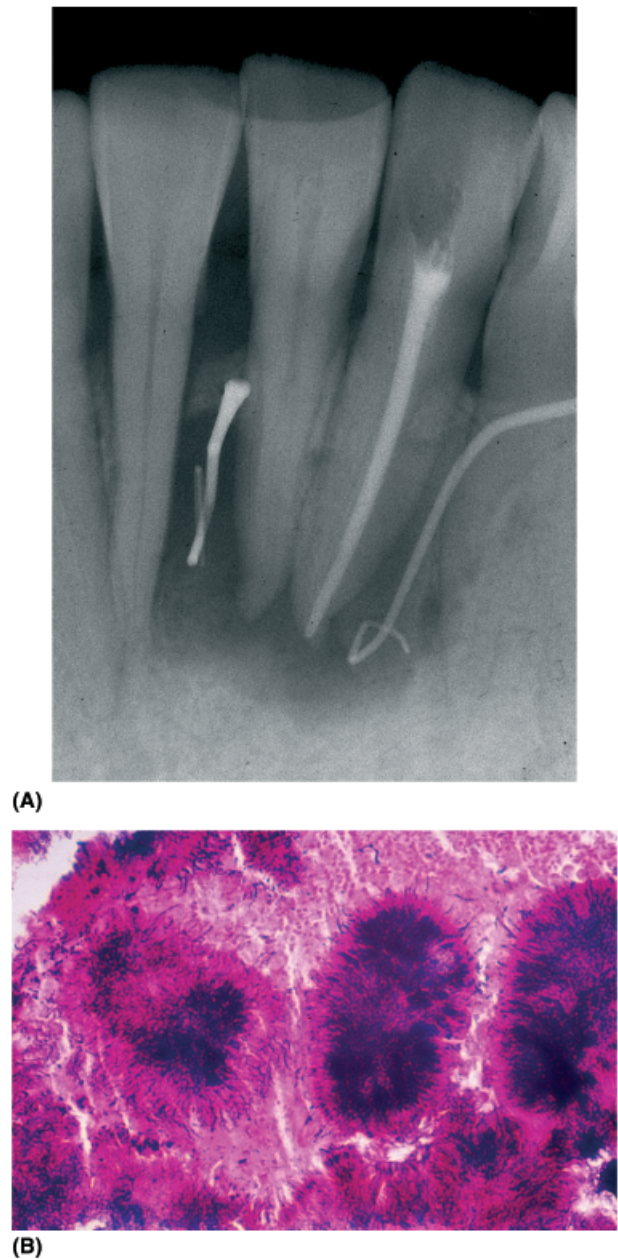


Fig. 15. An extra-radicular infection that was histologically diagnosed as '*periapical actinomycosis*'. (A) Clinically, there were two draining sinuses associated with the lower left central and lateral incisors, both of which had pulpless and infected root canal systems. One canal of the lateral incisor had been endodontically treated previously. The initial clinical examination suggested chronic apical abscesses but the infection continued despite thorough endodontic treatment of the two canals in each tooth. Hence, a periapical curettage was performed. (B) The tissue, which was biopsied and examined histologically, had the typical appearance of colonies of *actinomyces* organisms.

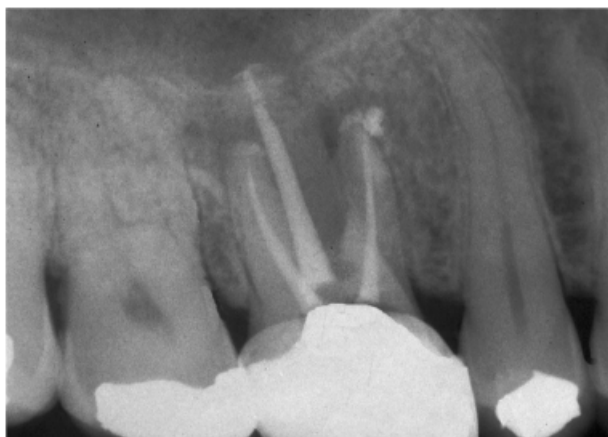

Fig. 16. The extrusion of root filling material through the apical foramen of the mesio-buccal root of this upper right first molar tooth resulted in a foreign body reaction following the root canal filling. Slight tenderness to biting persisted and the radiolucency did not change in appearance over a 12-month period. Hence, a periapical curettage was performed and histological examination of the biopsy material confirmed the diagnosis of a foreign body reaction.

40). The foreign material is most likely to be excess root filling material, such as gutta percha or a root canal cement that has been extruded through the apical foramen during endodontic treatment (62, 63). Hence radiographically, a foreign body reaction may, but far from always, appear as a periapical radiolucent area surrounding radiopaque material (Fig. 16). The patient may or may not display clinical symptoms such as tenderness to palpation and percussion. In the initial stages, it is usually impossible to distinguish between a foreign body reaction and inflammation because of an infectious process since a foreign body reaction can be diagnosed only with the aid of a biopsy and histological examination. If there is a radiolucency present in conjunction with extruded root filling material, then healing cannot normally be attained by orthograde endodontic re-treatment if this lesion has been caused by a foreign body reaction. Ideally in such a case, the periapical region should be monitored radiographically for several years to determine whether it heals before surgery is even considered.

Not all cases with over-extended root fillings will have a foreign body reaction as it will depend on the nature and the amount of the material being extruded. Foreign body reactions may also occur in response to irrigants and medicaments used during the endodontic treatment. Talcum powder (62, 63) and paper points

(40) inadvertently pushed into and left in the periapical tissue may also cause a foreign body response. In these cases, the diagnosis will be more difficult since the foreign bodies are not visible radiographically.

Periapical scar

A periapical scar is neither a disease nor a pathological condition, but it represents a healing response without bone deposition either following treatment of an inflammatory reaction with bone resorption (such as a granuloma, abscess or cyst), or following surgical endodontic treatment (41). Radiographically, there will be an apical radiolucency that may not be distinguishable from a radiolucency associated with a granuloma, a cyst, an abscess, an extra-radicular infection and foreign body reaction. The majority of periapical scars appear to be associated with surgical defects and appear as radiolucencies located at a distance from the root apex. The most often affected teeth are upper lateral incisors following 'through and through defects' involving both the labial and palatal cortical plates of bone when the surgical defect heals with some connective tissue in-growth (64).

Given that a periapical scar does not represent a disease condition, no symptoms would be expected and there is no need to remove the scar. However, the diagnosis of a periapical scar is difficult and can only be achieved on the basis of histological examination of a biopsy unless the typical configurations in surgery cases described above can be confirmed. In order to avoid unnecessary surgery, operators must base the need for the procedure on a comprehensive analysis of the presenting situation and the history associated with the tooth and the previous treatment. A further consideration is that periapical scars associated with conventional endodontic therapy must be regarded as being a rare entity as few reports exist in the literature (65, 66). Two studies have followed a number of cases with increased periodontal ligament spaces persisting for 10–17 years (67) and for 20–27 years (68) with no changes becoming evident in their radiographic appearances and no clinical signs or symptoms. It is likely that these teeth developed periapical scars. These studies indicate the importance of standardized periapical radiographs in the diagnostic process and when reviewing cases since the relative size of the radiolucency at each review appointment is critical. If the area is increasing in size then this indicates a disease process is occurring and treatment is required. Reduction in the size of the area may indicate that healing is in

progress and further observation is warranted to ensure that further healing occurs over time.

External root resorption

There are seven forms of external root resorption listed in Table 2 and each has its own typical clinical and radiographic appearance. This category of periradicular lesions is listed for the sake of completeness and readers are advised to review endodontic textbooks and journals for more detailed information about these conditions.

Examination and diagnostic procedures for periapical diseases

It is imperative to gather ALL of the relevant information about the patient, the oral condition and the involved teeth before making a diagnosis. Provisional diagnoses of the status of both the pulp and periapical tissues should be determined from the

patient's description of the symptoms, the history of the complaint and details of any recent treatment that has been performed (see Table 3). The findings from the clinical and radiographic examinations together with the results of the diagnostic tests are then collated and analysed to form a definitive diagnosis of the conditions of the tissues and to determine which tooth is involved. It is not always necessary to perform every diagnostic test and clinicians should only choose tests that are relevant to the presenting complaint – for example, a pulp sensibility test using heat is unlikely to help a diagnosis unless the patient complains of sensitivity to heat. Ideally, there should be at least two different signs and/or symptoms present to indicate and confirm the disease. If there is any doubt and the pain is not severe, then the operator should defer treatment until the diagnosis becomes clear, or otherwise the patient should be referred to a specialist for diagnosis and treatment.

Table 3. Summary of the examination and diagnostic processes for the assessment of the status of the pulp and periapical tissues.

<i>Procedure</i>	<i>Result</i>
1. History and discussion with patient Medical history Dental history Description of presenting complaint Details of any previous treatment of presenting complaint	➔ Provisional diagnosis of presenting condition
2. Clinical Examination Extra-oral signs Intra-oral signs Individual tooth assessment Restoration assessment	➔ Assess possible causative factors ➔ Provisional diagnosis of tooth status
3. Clinical Tests Pulp sensibility tests Percussion, mobility, palpation	➔ Provisional diagnosis of the status of the pulp and/or the root canal system ➔ Provisional diagnosis of the periapical status
4. Radiographic Examination	➔ Confirm/assess causative factors ➔ Provisional diagnosis of periapical status
5. Correlation of the history, clinical, radiographic and test findings	➔ DEFINITIVE DIAGNOSIS - Pulp, root canal and periapical status - Cause(s) of the diseases
6. TREATMENT PLAN Investigation/restoration removal Reassessment of the tooth and its prognosis	➔ Confirm the definitive diagnosis and cause(s) ➔ Finalize and continue the treatment plan

When assessing teeth for endodontic diseases, the following aspects should be considered for every case (23):

1. the status of the pulp,
2. the status of the root canal,
3. the status of the periapical tissues, and
4. the causes(s) of the condition(s).

A distinction is drawn between the status of the pulp and the status of the root canal as some teeth will not actually contain any pulp tissue to be assessed, as in pulpless teeth and teeth that have had previous endodontic treatment.

It is also essential to record all the clinical symptoms and the proper diagnosis in the patient's file for future reference. Clinical records should include a description of the patient's presenting complaint, the history provided, the clinical findings, the tests performed and their results, a written report of the radiographic observations, the diagnosis, the cause(s), the treatment plan, an initial assessment of the prognosis, and the details of discussions with, and advice provided to, the patient (69). Records should also include the details of all treatment provided, any further findings noted during treatment, any changes to the original treatment plan, a reassessment of the prognosis following treatment, and details of any further advice provided to the patient. Discussions and records concerning endodontic diseases and their treatment should also include details about the future restoration of the involved tooth (42).

Concluding remarks

Many different conditions may present as radiolucencies or radiopacities in the periapical region of teeth. The most common periapical lesions are a direct result of infection of the root canal system but this can only be determined with a thorough history, an examination, clinical tests and radiographs. In order to accurately diagnose periapical diseases, it is important to understand the dynamics of the disease processes that occur within the pulp and periapical tissues, and also the interactions between the different disease entities. Signs and symptoms will vary at different stages of the disease process as will the treatment required. Periapical conditions must be diagnosed in conjunction with a diagnosis of the status of the pulp and the root

canal of the affected tooth. The cause of the presenting conditions must also be assessed and then the appropriate treatment will become obvious. If such an approach is followed, then the treatment is more likely to have a favorable outcome.

Acknowledgements

The author sincerely thanks Prof. Michael Aldred for his invaluable assistance and advice in the compilation of Table 1. The author also acknowledges the kind permission granted by the Editor of the *Annals of the Royal Australasian College of Dental Surgeons* which has allowed reproduction of the tables, figures and much of the text for this article which has been adapted from a previous article written by the author for the College's *Annals* (42).

References

1. Nair PNR. Apical periodontitis: a dynamic encounter between root canal infection and host response. *Periodontology* 2000 1997: **13**: 121–148.
2. Heithersay GS, Hume WR, Valdrighi L. Disease dynamics of the dentine, pulp, and periapical tissues. In: Prabhu SR, Wilson D, Daftary DK, Johnson NW, eds. *Oral Diseases in the Tropics*. Oxford: Oxford University Press, 1992: 582–597.
3. Andreasen FM. Transient apical breakdown and its relation to color and sensibility changes after luxation injuries to teeth. *Endod Dent Traumatol* 1986; **2**: 9–19.
4. Andreasen FM, Pedersen BV. Prognosis of luxated permanent teeth – the development of pulp necrosis. *Endod Dent Traumatol* 1985; **1**: 207–220.
5. Andreasen FM, Yu Z, Thomsen BL. Relationship between pulp dimensions and development of pulp necrosis after luxation injuries in the permanent dentition. *Endod Dent Traumatol* 1986; **2**: 90–98.
6. Kahler B, Moule A, Stenzel D. Bacterial contamination of cracks in symptomatic vital teeth. *Aust Endod J* 2000; **26**: 115–118.
7. Love RM. Bacterial penetration of the root canal of intact incisor teeth after a simulated traumatic injury. *Endod Dent Traumatol* 1996; **12**: 289–293.
8. Walker BN, Makinson OF, Peters MCRB. Enamel cracks – the role of enamel lamellae in caries initiation. *Aust Dent J* 1998; **43**: 110–116.
9. Bergenholtz G. Evidence for bacterial causation of adverse pulpal responses in resin-based dental restorations. *Crit Rev Oral Biol Med* 2000; **11**: 467–480.
10. Bergenholtz G, Nyman S. Endodontic complications following periodontal and prosthetic treatment of patients with advanced periodontal disease. *J Periodontol* 1984; **55**: 63–68.
11. Bergenholtz G. Iatrogenic injury to the pulp in dental procedures: aspects of pathogenesis, management and preventive measures. *Int Dent J* 1991; **41**: 99–110.

12. Michaelson PL, Holland GR. Is pulpitis painful? *Int Endod J* 2002; **35**: 829–832.
13. Jansson L, Ehnevid H, Lindskog S, Blomlöf L. Development of periapical lesions. *Swed Dent J* 1993; **17**: 85–93.
14. Fales WH, Warner JF, Teresa GW. Effects of *Fusobacterium necrophorum* leukotoxin on rabbit peritoneal macrophages *in vitro*. *Am J Vet Res* 1977; **38**: 491–495.
15. Taichman NS, Dean RT, Sanderson CJ. Biochemical and morphological characterization of the killing of human monocytes derived from *Actinobacillus actinomycetemcomitans*. *Infect Immun* 1980; **28**: 259–268.
16. Stashenko P, Yu SM, Wang C-Y. Kinetics of immune cell and bone resorptive responses to endodontic infections. *J Endod* 1992; **18**: 422–426.
17. Kakehashi S, Stanley HR, Fitzgerald RJ. The effects of surgical exposures of dental pulps in germ-free and conventional laboratory rats. *Oral Surg* 1965; **20**: 340–349.
18. Korzen BH, Krakow AA, Green DB. Pulpal and periapical tissue responses in conventional and mono-infected gnotobiotic rats. *Oral Surg* 1974; **37**: 783–802.
19. Sundqvist G.. Bacteriological studies of necrotic pulps. Umeå University Odontological Dissertations No. 7, Department of Endodontics, Umeå University, Sweden, 1976.
20. Möller ÅJR, Fabricius L, Dahlén G, Öhman AE, Heyden G. Influence on periapical tissues of indigenous oral bacteria and necrotic pulp tissue in monkeys. *Scand J Dent Res* 1981; **89**: 475–484.
21. Fabricius L, Dahlén G, Öhman AE, Möller ÅJR. Predominant indigenous oral bacteria isolated from infected root canals after varied times of closure. *Scand J Dent Res* 1982; **90**: 134–144.
22. Sundqvist G. Associations between microbial species in dental root canal infections. *Oral Microbiol Immunol* 1992; **7**: 257–262.
23. Abbott PV. Assessing restored teeth with pulp and periapical diseases for the presence of cracks, caries and marginal breakdown. *Aust Dent J* 2004; **49**: 33–39.
24. Kvinnsland S, Kristiansen AB, Kvinnsland I, Heyeraas KJ. Effect of experimental traumatic occlusion on periodontal and pulpal blood flow. *Acta Odontol Scand* 1992; **50**: 211–219.
25. Shi Y, Wang J, Cao C. Clinical studies on pulpitis and periapical periodontitis caused by traumatic occlusion. *Zhonghua Kou Qiang Yi Xue Za Zhi* 1997; **32**: 23–25.
26. Andreasen JO. The effect of excessive occlusal trauma upon periodontal healing after replantation of mature permanent incisors in monkeys. *Swed Dent J* 1981; **5**: 115–122.
27. Bergenholtz G, Hasselgren G. Endodontics and periodontics. In: Lindhe J, Karring T, Lang NP, eds. *Clinical Periodontology and Implant Dentistry*, 4th edn. Oxford: Blackwell Munksgaard, 2003: 318–351.
28. Langeland K, Rodrigues H, Dowden W. Periodontal disease, bacteria and pulpal histopathology. *Oral Surg Oral Med Oral Pathol* 1974; **37**: 257–270.
29. Hume WR, Massey WLK. Disease dynamics of the dental pulp. In: Mount GJ, Hume WR, eds. *Preservation and Restoration of Tooth Structure*. London: Mosby, 1998: 37–44.
30. Seltzer S. Periapical tissue irritants: trauma, root canal preparation, root canal irrigants and medicaments. In: Seltzer S. *Endodontology. Biologic Considerations in Endodontic Procedures*, 2nd edn. Philadelphia: Lea & Febiger, 1988: 237–280.
31. Hashimura T, Sato M, Hoshino E. Detection of *Slackia exigua*, *Mogibacterium timidum* and *Eubacterium sapphenum* from pulpal and periradicular samples using the Polymerase Chain Reaction (PCR) method. *Int Endod J* 2001; **34**: 463–470.
32. Çalişkan MK. Pulpotomy of carious vital teeth with periapical involvement. *Int Endod J* 1995; **28**: 172–176.
33. World Health Organisation. *Application of the International Classification of Diseases to dentistry and stomatology*, 3rd edn. Geneva: WHO, 1995: 66–67.
34. Tronstad L. Endodontic examination and diagnosis. In: Tronstad L. *Clinical Endodontics. A Textbook*, 2nd edn. Stuttgart: Thieme, 2003: 76–83.
35. Nair PNR, Schroeder HE. Periapical actinomycosis. *J Endod* 1984; **10**: 567–570.
36. Nair PNR. Light and electron microscopic studies on root canal flora and periapical lesions. *J Endod* 1987; **13**: 29–39.
37. Tronstad L, Barnett F, Riso K, Slots J. Extraradicular endodontic infections. *Endod Dent Traumatol* 1987; **3**: 86–90.
38. Tronstad L, Barnett F, Cervone F. Periapical bacterial plaque in teeth refractory to endodontic treatment. *Endod Dent Traumatol* 1990; **6**: 73–77.
39. Yusuf H. The significance of the presence of foreign material periapically as a cause of failure of root canal treatment. *Oral Surg Oral Med Oral Pathol* 1982; **54**: 566–574.
40. Koppang HS, Koppang R, Solheim T, Aarneals H, Stølen SØ. Cellulose fibers from endodontic paper points as an etiologic factor in postendodontic periapical granulomas and cysts. *J Endod* 1989; **15**: 369–372.
41. Nair PNR, Sjögren U, Figdor D, Sundqvist G. Persistent periapical radiolucencies of root-filled human teeth, failed endodontic treatments, and periapical scars. *Oral Surg Oral Med Oral Pathol Oral Radiol Endod* 1999; **87**: 617–627.
42. Abbott PV. The periapical space – a dynamic interface. *Ann R Australas Coll Dent Surg* 2000; **15**: 223–234.
43. Nair PNR, Pajarola G, Schroeder HE. Types and incidence of human periapical lesions obtained with extracted teeth. *Oral Surg Oral Med Oral Pathol Oral Radiol Endod* 1996; **81**: 93–102.
44. Nair PNR. Non-microbial etiology: periapical cysts sustain post-treatment apical periodontitis. *Endod Topics* 2003; **6**: 96–113.
45. Nair PNR, Sjögren U, Schumacher E, Sundqvist G. Radicular cyst affecting a root-filled human tooth: a long

- term post-treatment follow-up. *Int Endod J* 1993; **26**: 225–233.
46. Nair PNR, Sjögren U, Sundqvist G. Cholesterol crystals as an etiological factor in non-resolving chronic inflammation: an experimental study in guinea pigs. *Eur J Oral Sci* 1998; **106**: 644–650.
47. Abbott PV, Hume WR, Pearman JM. Antibiotics and endodontics. *Aust Dent J* 1990; **35**: 50–60.
48. Roane JB, Marshall FJ. Osteomyelitis: A complication of pulpless teeth: report of a case. *Oral Surg Oral Med Oral Pathol* 1972; **34**: 257–262.
49. Austin G, Deasy M, Walsh RF. Osteomyelitis associated with routine endodontic and periodontal therapy: a case report. *J Oral Med* 1978; **33**: 120–124.
50. Hought RT, Fitzgerald BE, Latta JE, Zallen RD. Ludwig's angina: a report of two cases and a review of the literature from 1945 to January 1979. *J Oral Surg* 1980; **38**: 849–855.
51. Bernoliel R, Asquith GT. Actinomycosis of the jaws. *Int J Oral Surg* 1985; **14**: 195–199.
52. Bullock JD, Fleishman JA. The spread of odontogenic infections to the orbit: diagnosis and management. *J Oral Maxillofac Surg* 1985; **43**: 749–755.
53. Fielding AT, Cross S, Matise JL, Mohnac AM. Cavernous sinus thrombosis: report of a case. *J Am Dent Assoc* 1983; **106**: 342–346.
54. Henig E, Derschowitz T, Shalit M, Toledo E. Brain abscess following dental infection. *Oral Surg Oral Med Oral Pathol* 1978; **45**: 955–958.
55. Churton MC, Greer ND. Intracranial abscess secondary to dental infection. *NZ Dent J* 1980; **76**: 58–60.
56. Cogan MIC. Necrotizing mediastinitis secondary to descending cervical cellulitis. *Oral Surg Oral Med Oral Pathol* 1973; **36**: 307–320.
57. Antrum DD. Paresthesia of the inferior alveolar nerve caused by periapical pathology. *J Endod* 1978; **4**: 220–221.
58. Quinn P, Guernsey LH. The presentation and complications of odontogenic septic shock. *Oral Surg Oral Med Oral Pathol* 1985; **59**: 336–339.
59. Bender IB, Seltzer S, Yermish M. The incidence of bacteraemia in endodontic manipulation: preliminary report. *Oral Surg Oral Med Oral Pathol* 1960; **13**: 353–360.
60. Baumgartner JC, Heggers JP, Harrison JW. The incidence of bacteraemias related to endodontic procedures. 1. Nonsurgical endodontics. *J Endod* 1975; **2**: 135–140.
61. Lee GTR. Septicaemia as a complication of endodontic treatment. *J Dent* 1984; **12**: 241–242.
62. Nair PRN, Sjögren U, Kahnberg KE, Krey G, Sundqvist G. Intraradicular bacteria and fungi in root-filled, asymptomatic human teeth with therapy-resistant periapical lesions: a long-term light and electron microscopic follow-up study. *J Endod* 1990; **16**: 580–588.
63. Nair PNR. Non-microbial etiology: foreign body reaction maintaining post-treatment apical periodontitis. *Endod Topics* 2003; **6**: 114–134.
64. Rud J, Andreasen JO, Möller Jensen JE. A multivariate analysis of the influence of various factors upon healing after endodontic surgery. *Int J Oral Surg* 1972; **1**: 258–271.
65. Nair PNR, Sjögren U, Figdor D, Sundqvist G. Persistent periapical radiolucencies of root-filled human teeth, failed endodontic treatments, and periapical scars. *Oral Surg Oral Med Oral Pathol Oral Radiol Endod* 1999; **87**: 617–627.
66. Bhaskar SN. Periapical lesion: types, incidence, and clinical features. *Oral Surg Oral Med Oral Pathol* 1966; **21**: 657–671.
67. Molven O, Halse A. Success rates for gutta-percha and Kloroperka N–O root fillings made by undergraduate students: radiographic findings after 10–17 years. *Int Endod J* 1988; **21**: 243–250.
68. Halse A, Molven O. Increased width of the apical periodontal membrane space in endodontically treated teeth may represent favourable healing. *Int Endod J* 2004; **37**: 552–560.
69. Brown LF, Kiely PA, Spencer AJ. Hygienist employment and the presence of periodontal notations in general dental practice patient records. *Aust Dent J* 1994; **39**: 45–49.