

Sponsored by
oraqix[®]
(lidocaine and prilocaine
periodontal gel) 2.5% / 2.5%
www.oraqix.com

THE JOURNAL OF THE AMERICAN DENTAL ASSOCIATION



Avoiding complications in local anesthesia induction: Anatomical considerations

PATRICIA L. BLANTON and ARTHUR H.
JESKE

J Am Dent Assoc 2003;134:888-893

*The following resources related to this article are available online at
jada.ada.org (this information is current as of October 14, 2010):*

Updated information and services including high-resolution figures, can be found in the online version of this article at:

<http://jada.ada.org/cgi/content/full/134/7/888>

This article appears in the following **subject collections**:

Pharmacology <http://jada.ada.org/cgi/collection/pharmacology>

Information about obtaining **reprints** of this article or about permission to reproduce this article in whole or in part can be found at:

<http://www.ada.org/prof/resources/pubs/jada/permissions.asp>

Avoiding complications in local anesthesia induction

Anatomical considerations

PATRICIA L. BLANTON, D.D.S., M.S., Ph.D.;
ARTHUR H. JESKE, D.M.D., Ph.D.

Second in an occasional series of articles about local anesthesia

Dentists administer thousands of local anesthetic injections every day with few reports of serious complications.^{1,2(pp174,208,259)} However, we cannot allow our successes to lull us into complacency. Whenever local anesthesia is called for, we must remind ourselves of the anatomical and pharmacological considerations that could result in complications, ranging from temporary discomfort for the patient to death.^{3,4}

Dentists need to consider the potential for anatomical complications when administering any dental local anesthetic.

Typically, complications that have an anatomical basis are local in nature. Misjudging the anatomy involved during local anesthetic administration can result in inadequate or incomplete anesthesia, as well as in other complications, such as nerve trauma; vascular injury; intravascular, intraglandular or intramuscular injection; and, as recently reported, middle-ear and ophthalmic problems.⁵ Consequences of misdirected needle placement include facial paralysis,⁶ inferior alveolar and lingual nerve paresthesia (transient or permanent)^{7,8} and muscle trismus^{2,9(pp307-13),10} among others. Fortunately, dentists can avoid most of these complications by remaining cognizant of the potential risks associated with oral injections and by establishing a routine protocol to be followed before administering any local anes-

Background. Dentists administer thousands of local anesthetic injections every day with few reports of serious complications.

However, misjudging the anatomy involved during local anesthetic administration can result not only in inadequate or incomplete anesthesia, but in other complications such as paresthesia, bleeding or hematoma formation, or in serious systemic complications.

Overview. The authors discuss anatomical considerations that dentists should keep in mind when administering local anesthetic injections. In particular, they discuss ways in which dentists can minimize the risk of nerve or vascular injury, as well as systemic complications.

Conclusions and Clinical Implications. Even the most experienced practitioner can benefit from a periodic review of the anatomy associated with local anesthesia. This article offers dentists the opportunity to consider needle placement with regard to location of nerves, blood vessels and glands, and to review injection protocols that can minimize the risk of complications.

thetic. Such preparation should include the following:

- a complete preoperative review of the patient's medical history;
- preoperative recording of blood pressure and pulse;
- attempts to help the patient relax before administering local anesthetic injections by addressing any anxiety or apprehension he or she may have;
- placement of the patient in a supine position for injections; in addition, the dentist should assume a position that will allow him or her to administer the injection comfortably;
- use of disposable needles to prevent



"Practical Science" is prepared each month by the ADA Council on Scientific Affairs and Division of Science, in cooperation with The Journal of the American Dental Association. The mission of "Practical Science" is to spotlight what is known, scientifically, about the issues and challenges facing today's practicing dentists.

infection transmission and aspirating syringes in an attempt to avoid intravascular injections;

- attention to delivering painless injections;
- use of a minimum volume of anesthetic solution, injected slowly and only after the dentist performs aspiration on two planes;
- observation of the patient during and after administration of the local anesthetic.

Most complications associated with anatomy are transient in nature, but some are persistent or have permanent ramifications. If complications do occur, it is incumbent on the dentist to make the proper diagnosis and act swiftly to manage the problem, inform and assure the patient, and minimize the consequences.

In this article, we review some of the anatomical considerations for enhancing the effectiveness of local anesthesia while maintaining a high level of safety, and discuss some circumstances that may require special attention.

GENERAL POTENTIAL COMPLICATIONS

Generally speaking, complications of an anatomical nature are of four types: injuries to nerves, injuries to blood vessels, trauma to muscles or systemic reactions. In the head and neck region, there is additional potential for intraglandular injections with associated sequelae.

Nerve injury. Some dentists erroneously believe that the needle gauge used most often in dentistry precludes the risk of nerve damage. While it is true that 25- to 30-gauge needles are of insufficient diameter to sever a nerve trunk, contacting a nerve with such a needle apparently is all that may be needed to cause trauma that could result in paresthesia.⁸ In fact, there have been many reports^{6-8,11-16} of trauma to a nerve or nerve sheath produced by the needle during dental injections.

Stacy and Hajjar¹⁷ reported that nerve injury may occur during needle withdrawal. In a small study, these authors noted that standard dental anesthetic needles can barb if they come into contact with bone during the injection. They found that a relationship existed between the pattern of such barbing and the likelihood of nerve injury occurring during withdrawal of the needle from the oral mucosa after injection. One study¹² reported that in addition to paresthesia (loss of sensation),

hyperesthesia (increased sensitivity to painful stimuli) and even dysesthesia (pain following non-noxious stimuli) may develop in some patients.

Paresthesia resulting from nerve trauma during dental anesthetic injection can last for weeks or months and can lead to self-inflicted injury to oral tissues. These paresthesias commonly involve the tongue and lower lip. In these cases, mechanical (biting) and thermal trauma can occur without the patient's awareness and can result in significant pathology. When the lingual nerve is involved, the chorda tympani branch of the facial nerve also may be traumatized, resulting in dysgeusia (impaired sense of taste) and xerostomia (reduced salivation). In some instances, dysesthesia may accompany paresthesia.

Fortunately, most paresthesias resolve without treatment within approximately eight weeks.¹⁸ Only if the damage to the nerve is severe will the paresthesia be permanent, and this is a rare occurrence. If the clinician is faced with this complication, treating the patient is as important as managing the complication. First, the dentist should reassure the patient by telling him or her that transient loss of sensation can

and does occur, and that it may persist for several months with gradual improvement. The patient's neurological deficit should be monitored periodically to determine if the sensory deficit could be permanent. It is prudent and appropriate for the dentist to consult with an oral surgeon. It is interesting to note that paresthesia is one of the most frequent causes of dental malpractice litigation.¹²

Nerve-related complications other than direct trauma can arise after anesthetic injection. The passive process of diffusion of the anesthetic through the orbit can ultimately result in ocular and extraocular symptoms, including paralysis of the extraocular muscles, with associated diplopia (double vision) and even amaurosis (temporary blindness). Also, Horner's syndrome-like manifestations can occur, including enophthalmos (recession of the eyeball), miosis (pupil constriction) and palpebral ptosis (drooping of the eyelid).^{2,10,11,19-22} Occasionally, temporary loss or blurring of vision unilaterally will occur. These ocular complications would most likely follow a posterior superior alveolar, or PSA, or second-division nerve block.

Such complications can arise when the needle

.....
**Paresthesia resulting
 from nerve trauma
 during dental
 anesthetic injection
 can last for weeks
 or months.**

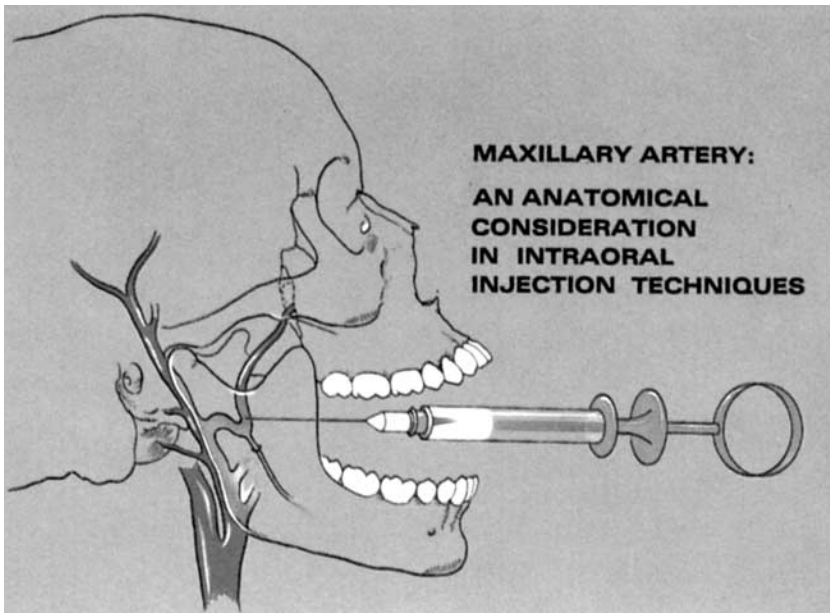


Figure 1. An inferior alveolar block injection showing the needle too high, which can bring it into proximity with the maxillary artery and increase the risk of a vascular injury. (Reprinted with permission of the publisher from Roda and Blanton.¹⁰)

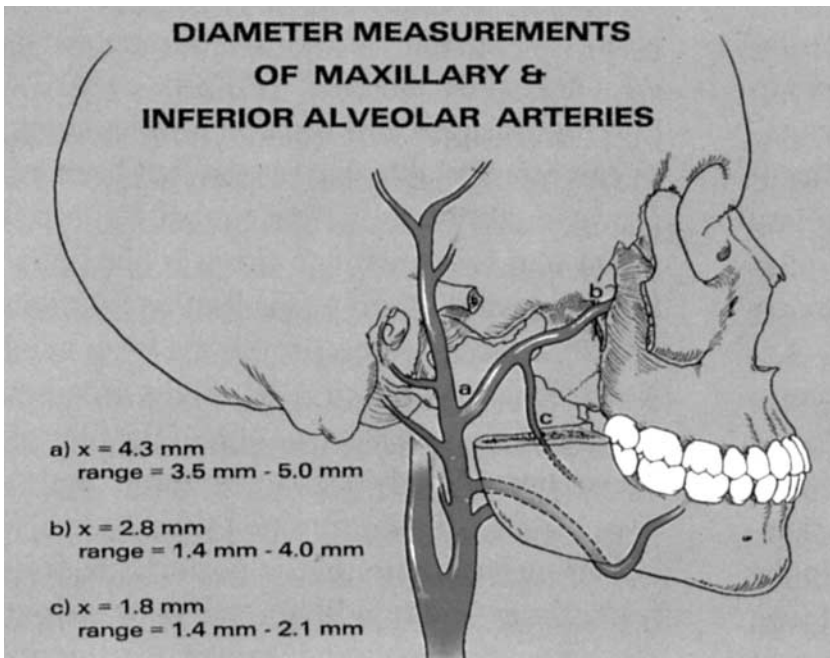


Figure 2. The course and diameter measurements of the maxillary and inferior alveolar arteries in the infratemporal fossa. Note the large diameter of these vessels. mm: Millimeters. (Reprinted with permission of the publisher from Roda and Blanton.¹⁰)

either approaches the inferior orbital fissure at the height of the posterior maxilla or when an injection of too much anesthetic solution is delivered under excessive pressure, resulting in diffusion of the anesthetic through the inferior orbital fissure and into the orbit. The passive process of

diffusion of the anesthetic solution through the orbit ultimately involves the optic nerve and results in temporary blindness. If this complication develops, the dentist should reassure the patient that this is a transient phenomenon, and vision will be restored as the effects of the anesthetic wear off.

Bleeding. When injecting into a highly vascular area, such as the infratemporal fossa, the dentist always faces the risk of an intravascular injection, vascular damage and hemorrhage with hematoma formation.^{2,9(pp496-9),10,23-25} This is most commonly encountered with a PSA or second-division nerve block, but can occur with an inferior alveolar nerve block if the needle is directed too high (Figure 1). Infraorbital anesthesia and an anterior superior alveolar, or ASA, nerve block also have been reported to be associated with hematoma formation.^{2(pp174,208,259)}

If a vein is engaged, the bleeding is minimal and usually is evidenced a few days after injection, if at all. However, if an artery is damaged, it will produce rapid bleeding with significant hematoma formation, which is obvious most typically during the course of the injection because of the rapid onset of fairly extensive intraoral or extraoral swelling.

It is now fairly well-accepted that if brisk bleeding occurs in the tuberosity area, one of the terminal branches of the maxillary artery has most likely been engaged. During a second-division nerve block through the pterygomaxillary fissure, the terminal position of the maxillary artery itself is at risk of injury. The mean diameter of the artery at this site is 2.8 mm,²⁶ large enough to create the potential for serious bleeding if the artery is injured. Figure 2 illustrates the course and diameter of the

maxillary and inferior alveolar arteries. Significant bleeding in the anterior facial area, associated with infraorbital anesthesia or an ASA nerve block, most likely involves the facial artery or one of its branches.

If recognized quickly, the amount of hemor-

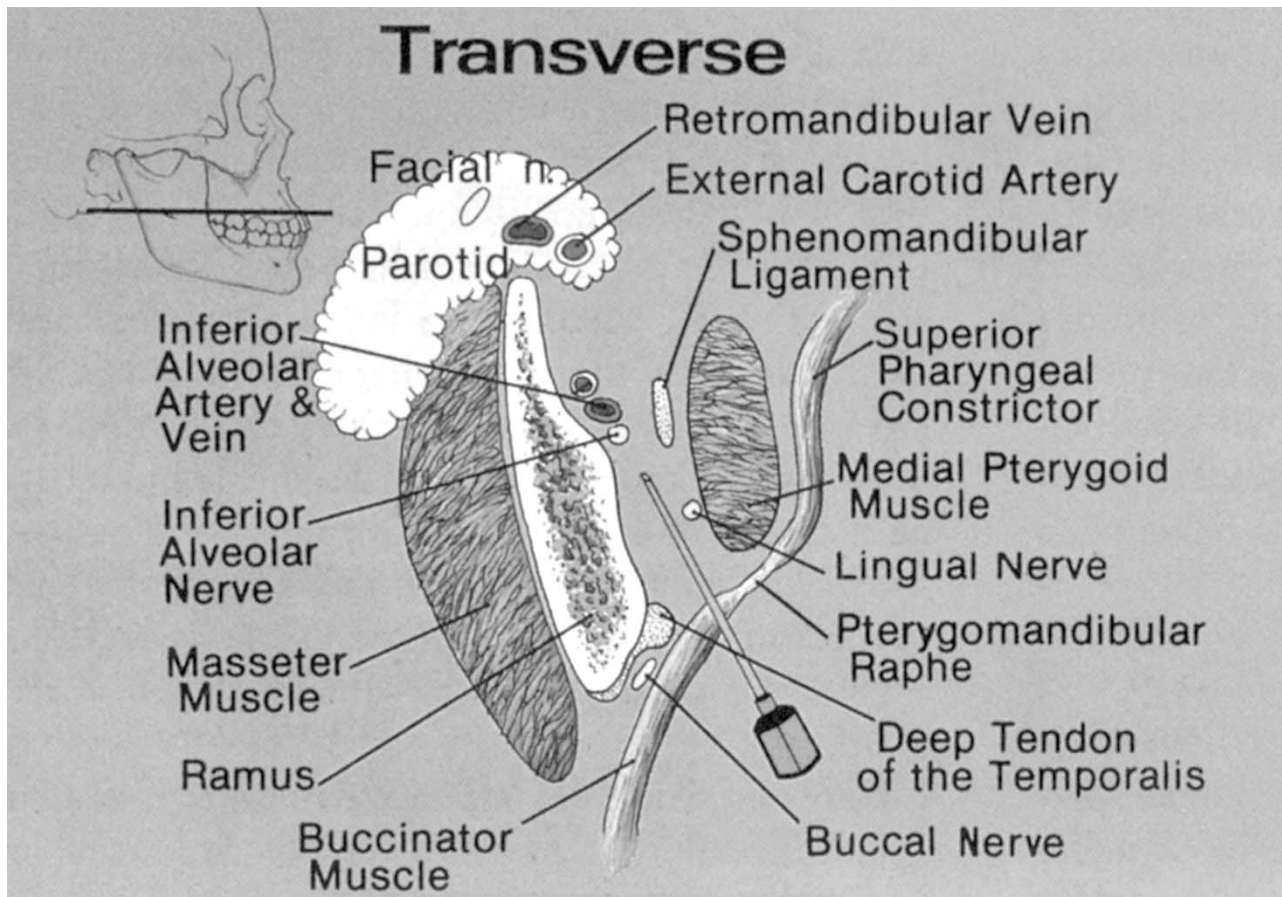


Figure 3. Cross-section of the pterygomandibular space showing various anatomical structures that could be affected by a misplaced injection. In particular, note the presence of the parotid gland, with the embedded facial nerve. (Reprinted with permission of the publisher from Roda and Blanton.¹⁰)

rhage may be reduced by applying pressure over the injection site; most often, the bleeding is self-limiting because of the pressure buildup within the tissues. The patient should be observed at 24- to 48-hour intervals for any signs of recurrent bleeding, as arterial bleeding can recur, or for signs of secondary infection of the hematoma. If arterial bleeding resumes, the dentist will have to evaluate the patient to determine the need for subsequent treatment, including the possibility of surgical ligation of the vessel. At the first indication of infection, antibiotic therapy should be initiated.

A second concern when injecting into a highly vascular area is the potential for anesthetizing sympathetic nerve fibers that travel through the head region in the company of arteries. Anesthetic deposited in the vicinity of an artery can affect this vasovasorum to result in end-organ phenomena, including a blanching of the overlying skin as a result of vasoconstriction.

Intraglandular injection. An occasional complication of inferior alveolar nerve block anesthesia is a transient paralysis of the ipsilateral facial muscles caused by anesthesia of the facial nerve (cranial nerve VII). Most often, the facial nerve is embedded in the substance of the parotid gland, which has a deep lobe extending around the posterior ramus of the mandible and projecting forward on the medial surface of the ramus (Figure 3).

If the injection is made too far posteriorly, the anesthetic solution may be injected into the substance of the parotid gland and could involve the facial nerve. If this happens, the patient will complain immediately of an inability to blink the eye, followed by an awareness of a sense of paralysis on the same side of the face. The dentist should quickly recognize the problem and assure the patient that the ensuing paralysis is transient and will disappear with the absorption of the anesthetic.¹⁰

Muscle trismus. When inserting the needle into the pterygomandibular space for the inferior alveolar, lingual and buccal nerve blocks, the clinician should use caution to avoid injury to the temporalis and medial pterygoid muscles. An intramuscular injection can result in trismus (that is, spasm of jaw muscles, which restricts mouth opening). The bony anterior ramus of the mandible offers a landmark for the temporalis muscle and usually is readily palpable. The pterygomandibular fold (obvious when the patient opens wide, because it is elevated by the underlying pterygomandibular raphe) serves as a landmark for the medial pterygoid muscle. Superiorly, the muscle is lateral to the fold, but at the normal level of injection, the muscle is medial to it.

If the anesthetic needle is directed through the mucous membrane lateral to the pterygomandibular fold and medial to the greatest concavity of the anterior bony ramus, injury to these muscles and the resultant painful trismus usually can be avoided.¹⁰ In the event of a Gow-Gates injection, the needle is directed higher into the infratemporal fossa and, on rare occasions, may involve the lateral pterygoid muscle.^{2(pp174,208,259)}

Systemic complications. Both intravenous and intra-arterial injections of local anesthetic solution are believed to be capable of producing systemic toxicity.²⁴ The undesirable clinical manifestations of such systemic reactions range from patient excitability, with elevated heart rate, to seizures progressing to loss of consciousness. With high levels of overdose, events can progress to generalized central nervous system depression and failure of the cardiorespiratory system. (We will discuss avoidance of systemic complications more fully in the next installment of this series on local anesthesia, which will focus on pharmaceutical considerations in achieving local anesthesia.)

From an anatomical perspective, the risk of systemic complications can be minimized by achieving a negative aspiration in two planes before injecting.² A needle tip resting within the lumen of a blood vessel may be occluded by the vessel wall. Rotating the needle about 45 degrees to reorient the needle bevel relative to the vessel wall may prevent needle occlusion. The dentist then should reaspirate in an attempt to avoid an intravascular injection. Intravenous and intra-arterial injections may occur with any intraoral nerve block, but are most likely to occur with the inferior alveolar, mental or PSA blocks.²⁷

In an effort to prevent untoward events, in



Dr. Blanton is professor emeritus, Department of Biomedical Sciences, Baylor College of Dentistry, The Texas A&M University System Health Science Center, Dallas. She also is a member of the ADA Council on Scientific Affairs. Address reprint requests to Dr. Blanton, 4514 Cole Ave., Suite 902, Dallas, Texas 75205, e-mail "pblanton@airmail.net".



Dr. Jeske is a professor, Department of Basic Sciences, University of Texas Dental Branch at Houston, and a member of the ADA Council on Scientific Affairs.

addition to confirming a negative aspiration in two planes, the practitioner should inject the anesthetic solution slowly.²⁸ The rate of drug deposition should be no less than 60

seconds for a 1.8-milliliter cartridge.²

CONCLUSION

During the more than 100 years since Halstead introduced the inferior alveolar nerve block, a number of myths and misconceptions have permeated the practice of inducing local anesthesia. Perhaps one of the most profound myths involves the perceived benign nature of dental local anesthetic injections. Such a myth could lead to less-than-full appreciation of the anatomical complexity and variability of the head and neck.

We have attempted to dispel this myth and encourage the dentist to consider the potential for anatomical complications discussed above when administering any dental local anesthetic. Failure to do so can result not only in less-than-optimal local anesthesia but, more significantly, in minor—perhaps even major—consequences in the form of local and systemic complications. ■

Although Practical Science is developed in cooperation with the ADA Council on Scientific Affairs and the Division of Science, the opinions expressed in this article are those of the authors and do not necessarily reflect the views and positions of the Council, the Division or the Association.

1. Cawson RA, Curson I, Whittingham DR. The hazards of dental local anaesthetics. *Br Dent J* 1983;154:253-8.
2. Malamed SF. Handbook of local anesthesia. 4th ed. St. Louis: Mosby; 1997:143-259.
3. Seldin HM, Recant BS. The safety of anesthesia in the dental office. *J Oral Surg* 1955;13:199.
4. Hersh EV, Helpin ML, Evans OB. Local anesthetic mortality: report of a case. *ASDC J Dent Child* 1991;58:489-91.
5. Brodsky CD, Dower JS Jr. Middle ear problems after a Gow-Gates injection. *JADA* 2001;132:1420-4.
6. Barker BC, Davies PL. The applied anatomy of the pterygomandibular space. *Br J Oral Surg* 1972;10:43-55.
7. Pogrel M, Thamby SR. Permanent nerve involvement resulting from inferior alveolar nerve blocks. *JADA* 2000;131:901-7.
8. Engar RC. Local injection gone awry. *AGD Impact* 2002;30(2):21.
9. Clemente CD. Gray's anatomy. 13th ed. Philadelphia: Lea & Febiger; 1985:307-499.
10. Roda RS, Blanton PL. The anatomy of local anesthesia. *Quintessence Int* 1994;25(1):27-38.
11. Laskin DM. Diagnosis and treatment of complications associated

with local anesthesia. *Int Dent J* 1984;34:232-7.

12. Haas DA, Lennon D. A 21-year retrospective study of reports of paresthesia following local anesthetic administration. *J Can Dent Assoc* 1995;61:319-20, 323-6, 329-30.

13. Nickel AA Jr. A retrospective study of paresthesia of the dental alveolar nerves. *Anesth Prog* 1990;37(1):42-5.

14. Paxton MC, Hadley JN, Hadley MN, Edwards RC, Harrison SJ. Chorda tympani nerve injury following inferior alveolar injection: a review of a case. *JADA* 1994;126:1003-6.

15. Harn SD, Durham TM. Incidence of lingual nerve trauma and postinjection complaints in conventional mandibular block anesthesia. *JADA* 1990;121:519-23.

16. Rezai RF, Bayley NC, Austin K. Lingual nerve damage: causative factors and management. *Quintessence Int* 1988;19:295-8.

17. Stacy GC, Hajjar G. Barbed needle and inexplicable paresthesias and trismus after dental regional anesthesia. *Oral Surg Oral Med Oral Pathol* 1994;78:680-1.

18. Pretterklieber ML, Skopakoff C, Mayr R. The human maxillary artery reinvestigated, I: topographical relations in the infratemporal fossa. *Acta Anat* 1991;142:281-7.

19. Cooley RL, Cottingham AJ Jr. Ocular complications from local anesthetic injections. *Gen Dent* 1979;27:40-3.

20. Penarrocha-Diago M, Sanchis-Biesa JM. Ophthalmologic compli-

cations after intraoral local anesthesia with articaine. *Oral Surg Oral Med Oral Pathol Oral Radiol Endod* 2000;90(1):21-4.

21. Kronman JH, Kabani S. The neuronal basis for diplopia following local anesthetic injections. *Oral Surg Oral Med Oral Pathol* 1984;58:533-4.

22. Rood JP. Ocular complications of inferior alveolar nerve block. *Br Dent J* 1972;132:23-4.

23. Traeger KA. Hematoma following inferior alveolar injection: a possible cause for anesthesia failure. *Anesth Prog* 1979;26:122-3.

24. Bishop PT. Frequency of accidental intravascular injection of local anesthetics in children. *Br Dent J* 1983;154:76-7.

25. Turvey TA, Fonseca RJ. The anatomy of the internal maxillary artery in the pterygopalatine fossa: its relationship to maxillary surgery. *J Oral Surg* 1980;38:92-5.

26. Lacouture C, Blanton PL, Hairston LE. The anatomy of the maxillary artery in the infratemporal fossa in relationship to oral injections. *Anat Rec* 1983;205:104A.

27. Bartlett SZ. Clinical observations on the effects of injections of local anesthetic preceded by aspiration. *Oral Surg Oral Med Oral Pathol* 1972;33:520-6.

28. Malagodi MH, Munson ES, Embro MJ. Relation of etidocaine and bupivacaine toxicity to the rate of infusion in rhesus monkeys. *Br J Anesth* 1977;49(2):121-5.