

## Iatrogenic Pneumomediastinum and Facial Emphysema after Tooth Extraction

Chenguir M\*, Loufad FZ, Elansari R, Abada R, Rouadi S, Roubal M and Mahtar M

Department of ENT and Neck Surgery Service, "20 August" Hospital, CHU Ibn Rochd, Casablanca, Morocco

\*Corresponding author: Chenguir M, Department of ENT and Neck Surgery Service, "20 August" Hospital, CHU Ibn Rochd, Casablanca, Morocco, E-mail: chenguirmeriem@yahoo.fr

**Citation:** Chenguir M, Loufad FZ, Elansari R, Abada R, Rouadi S, et al. (2016) Iatrogenic Pneumomediastinum and Facial Emphysema after Tooth Extraction. J Case Rep Stud 4(5): 505. doi: 10.15744/2348-9820.4.505

**Received Date:** March 23, 2016 **Accepted Date:** October 28, 2016 **Published Date:** October 31, 2016

### Abstract

Subcutaneous emphysema and pneumomediastinum following extraction of mandibular third molars are rare. These complications are caused by forceful injection of air into the connective tissue. The symptoms may vary depending on the quantity of air, its location and the presence or absence of infection. In most cases, the subcutaneous emphysema will begin to disappear in 3-5 days. This report presents a case of subcutaneous emphysema and pneumomediastinum after wisdom extraction.

**Keywords:** Subcutaneous Emphysema; Third Molar Extraction; Dental Surgery Complication

### Introduction

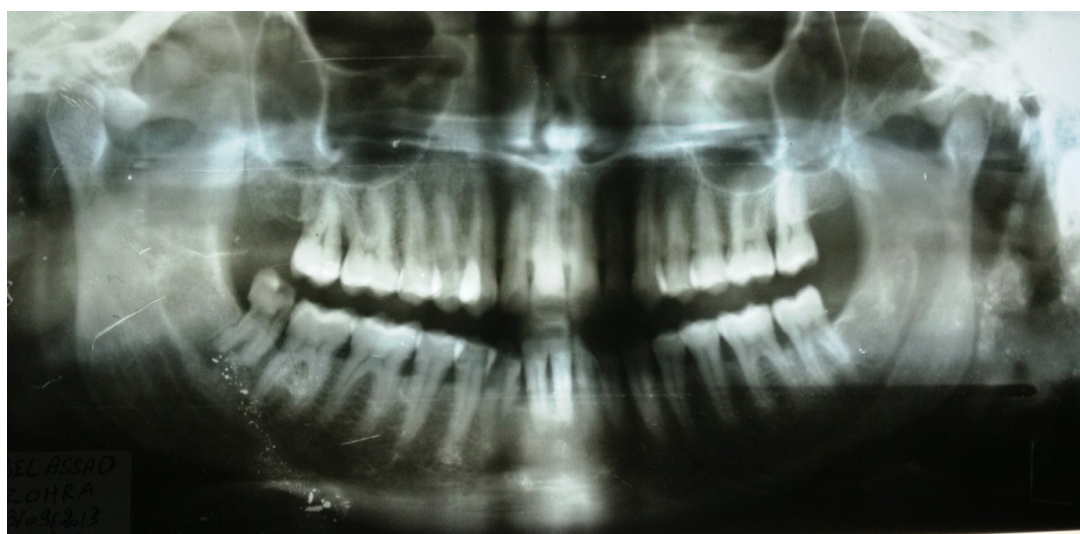The surgical extraction of the third molar is the most frequently carried out procedure in oral surgery [1]. Common complications include pain, bleeding, infection, perforation of the maxillary sinus and nerve injury [2]. Subcutaneous emphysema and pneumomediastinum are rare complications of dental treatment.

We present a case of cervicofacial emphysema and pneumomediastinum occurring in a 42-year-old female following the removal of the right third mandibular molar.

### Case Report

A 42-year-old female patient came to the emergency department, due to crepitations in the face and neck immediately after a right third molar extraction under local anesthesia. Patient presents to the emergency department in the same date of incident. At the admission, the patient had difficulty breathing but she was hemodynamically stable and afebrile.

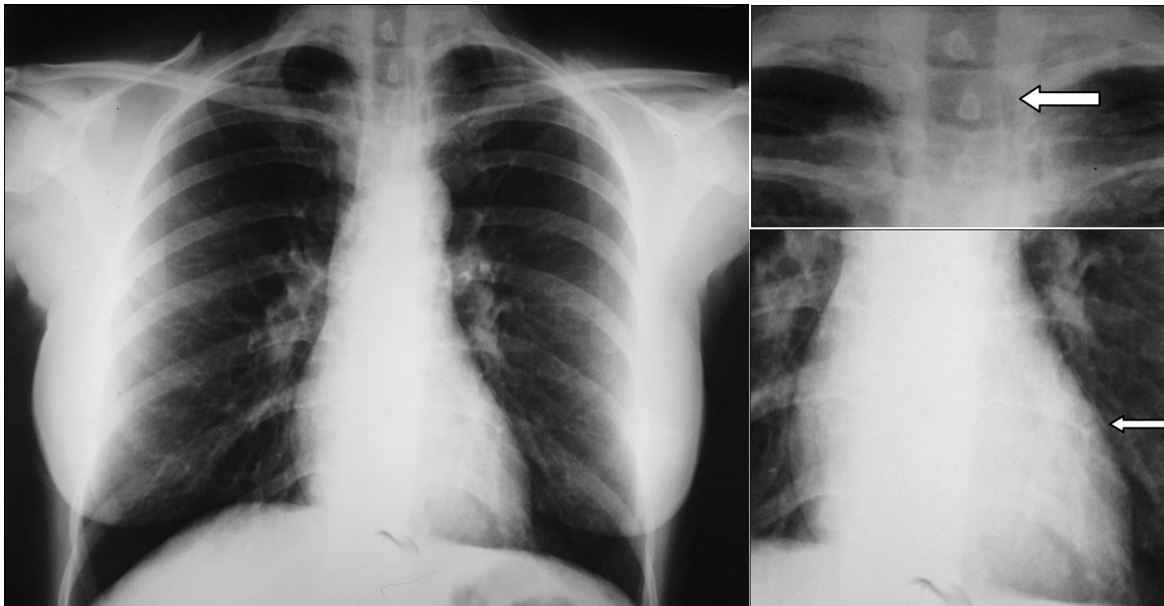
Clinically, an extensive swelling in right side of patient's face was visible. On palpation, there was a manifeste crepitus of the periorbital, cheek, laterocervical and supraclavicular region (Figure 1). The rest of physical examination was normal.



**Figure 1:** Preoperative radiograph showing right third mandibular molar with caries

The chest X-ray demonstrated pneumomediastinum and subcutaneous emphysema (Figure 2). No pneumothorax was detected. Endoscopic examination was normal.

The C reactive protein was within level ranges.



**Figure 2:** Chest X-ray showing pneumomediastinum

The patient was admitted to otolaryngology and neck surgery department for airway monitoring and parental antibiotic therapy. The patient was kept under observation.

The clinical course was favorable, with a progressive reduction in the emphysema and no apparent complications. The patient was discharged from the hospital 48h later. 7 days later chest x-ray control was normal.

## Discussion

Cervical emphysema and pneumomediastinum can be defined as the presence of air in subcutaneous soft tissue and mediastinum. It is produced by the entrance of air through the area of the wisdom tooth extraction [3].

The roots of molar teeth are connected directly with the submandibular space, which communicates with the retropharyngeal space and mediastinum [4].

Two factors are prerequisite for the formation of subcutaneous emphysema: air forced under pressure and a communication between the oral cavity and the subcutaneous tissue [5].

Air can be introduced into the soft tissue spaces using high speed air turbine drills [6]. In our case, a history of tooth extraction using compressed air equipment was available.

It is reported that subcutaneous emphysema and pneumomediastinum can also be seen after sneezing and nose blowing [4].

It should be noticed that surgery is not the only procedure at risk for the development of subcutaneous emphysema, as cases have been described during restorative procedures, crown preparation, and endodontic therapy [4].

The symptoms may vary depending on the quantity of air, its location and the presence or absence of infection. We may find from simple subcutaneous emphysema that is asymptomatic, to pneumomediastinum, pneumothorax or pneumopericardium [7]. The majority of patients are paucisymptomatic.

Crepitus on palpation and tenderness are findings of cervical emphysema. Retrosternal pain and dyspnea are characteristic findings of pneumomediastinum. Venous distension, hypotension, hypercarbia, and acidosis are life-threatening consequences of massive air trapping in the mediastinum. Infections can arise when these fascial planes are exposed, so that evaluation for infection and treatment with antibiotics might be necessary.

Complications of cervical emphysema and pneumomediastinum after oral surgery may include mediastinitis, cardiac tamponade and airway obstruction [8].

The diagnostic of a patient with suspected subcutaneous emphysema includes a clinical examination, laboratory analysis (CRP

levels) and a CT of the affected region [5]. Following the exclusion of potentially life-threatening complications, conservative treatment is recommended, with hospitalization under observation and prophylactic antibiotics [9].

In most cases, the subcutaneous emphysema will begin to disappear in 3-5 days [5].

## Conclusion

Subcutaneous emphysema and pneumomediastinum are rare complications after oral surgery and dental treatment. In order to prevent these complications, the compressed air should be used carefully and it is important for patients to avoid high intraoral pressures.

## References

1. Kunkel M, Morbach T, Kleis W, Wagner W (2006) Third molar complications requiring hospitalization. *Oral Surg Oral Med Oral Pathol Oral Radiol Endod* 102: 300-6.
2. Kunkel M, Kleis W, Morbach T, Wagner W (2007) Severe third molar complications including death-lessons from 100 cases requiring hospitalization. *J Oral Maxillofac Surg* 65: 1700-6.
3. Monsour PA, Savage NW (1989) Cervicofacial emphysema following dental procedures. *Aust Dent J* 34: 403-6.
4. Szubin L, La Bruna A, Levine J, Komisar A (1997) Subcutaneous and retropharyngeal emphysema after dental procedures. *Otolaryngol Head Neck Surg* 117: 122-3.
5. McKenzie WS, Rosenberg M (2009) Iatrogenic subcutaneous emphysema of dental and surgical origin: a literature review. *J Oral Maxillofac Surg* 67: 1265-8.
6. Ocakcioglu I, Koyuncu S, Kupeli M, Bol O (2016) Pneumomediastinum after Tooth Extraction. *Case Rep Surg* 10.1155/2016/4769180.
7. Abadal JM, Álvarez MJ, De la Torre J, Guerra AB (2002) Subcutaneous emphysema and pneumomediastinum secondary to dental extraction [Enfisema subcutáneo y neumomediastino secundarios a extracción dental]. *Radiología* 44: 27-9.
8. Ali A, Cunliffe DR, Watt-Smith SR (2000) Surgical emphysema and pneumomediastinum complicating dental extraction. *Br Dent J* 188: 589-90.
9. Picard M, Pham Dang N, Mondie JM, Barthelemy I (2015) Cervicothoracic Subcutaneous Emphysema and Pneumomediastinum After Third Molar Extraction. *J Oral Maxillofac Surg* 73: 10.1016/j.joms.2015.07.030.

Submit your next manuscript to Annex Publishers and benefit from:

- ▶ Easy online submission process
- ▶ Rapid peer review process
- ▶ Online article availability soon after acceptance for Publication
- ▶ Open access: articles available free online
- ▶ More accessibility of the articles to the readers/researchers within the field
- ▶ Better discount on subsequent article submission

Submit your manuscript at

<http://www.annexpublishers.com/paper-submission.php>