

Original Article

Bone islands of the craniomaxillofacial region

Na Li, Meng You, Hu Wang¹, Jiayin Ren, Shuping Zhao, Meng Jiang, Laiqing Xu, Yuanyuan Liu

Departments of Oral Radiology, ¹State Key Laboratory of Oral Diseases, West China College of Stomatology, Sichuan University, Chengdu, Sichuan, People's Republic of China

ABSTRACT

Objectives: To present and discuss the demographic and radiographic aspects of craniomaxillofacial bone islands (BIs) in the population of china.

Materials and Methods: A retrospective chart review was performed of all cases of BIs diagnosed in the Department of Oral Radiology in West China College of Stomatology, Sichuan University. The data collected included age at diagnosis, gender, race, location, presenting symptoms, type of BIs.

Results: In radiographic evaluation, BIs appear as localized, well-defined, non-expansile, radiopaque masses, which are round, elliptic or irregular in shape and are of variable size, ranging from a few millimetres to about 2 cm in diameter. The results of this study generally supported previous findings that BIs have an overwhelming mandibular predilection, especially, in the pre-molar/molar region, no sex predilection.

Conclusions: The presumptive diagnosis of a BI can easily be made if the individual clinical and radiologic findings, together with follow-up examinations, are taken into account. In addition, it is important to recognize this anomaly, evaluate radiographies carefully and distinguish it from other bone variations such as primary or metastatic tumours, which is much more significant clinically in dental examinations.

Keywords: Bone islands, idiopathic osteosclerosis, the jaws, variations

INTRODUCTION

Bone island (BI) is defined as a focus of compact bone within the spongiosa, probably representing a developmental error of endochondral ossification.^[1] BIs typically manifest as an incidentally discovered, well-defined homogenous radiopacity that is of unknown cause and cannot be attributed to any inflammatory, dysplastic, neoplasia, or systemic disorder. Once, the condition is diagnosed, treatment is neither indicated nor necessary. However, based on our clinical survey, BIs may pose a diagnostic

and management dilemma for the clinician who encounters them.

In this study, an attempt was made to investigate the prevalence of BIs in the Western Chinese population with respect to age at diagnosis, gender, race, location, presenting symptoms, type of BIs. The other aim was to attract the attention of clinician about the BIs.

MATERIALS AND METHODS

Samples

The retrospective study included 7389 panoramic radiographs obtained from the patients (3206 men and 4183 women Chinese subjects), presented to the Department of Oral Diagnosis and Radiology in West China College of Stomatology, Sichuan University. Descriptive characteristics of radiopacities, including localization and dental relationship were recorded.

Access this article online

Quick Response Code:



Website:

www.cranioimaxillary.com

DOI:

10.4103/2278-9588.113565

Correspondence to:

Dr. Hu Wang, Department of Oral Radiology, State Key Laboratory of Oral Diseases, West China College of Stomatology, Sichuan University, Chengdu, Sichuan, 610041, People's Republic of China. E-mail: wanghu200108@163.com

The prevalence of BIs assessment method

A BI typically manifested well-defined homogenous radiopacity in the mandible or maxilla that was of unknown cause and could not be attributed to any inflammatory, dysplastic, neoplasia or systemic disorder. All of the involved teeth were sound, noncaries. Cases where the involved teeth had large restorations in proximity to the pulp horns or dental pulp were excluded. The following radiopacities were specifically excluded:^[2,3]

- The characteristic mixed radiopaque-radiolucent areas of periapical cemental dysplasia and other benign fibroosseous lesions of periodontal ligament origin.
- Increased thickening of the lamina dura around teeth that showed marked malposition or that served as abutments for fixed bridges or partial dentures.
- Clearly, identifiable remnants of deciduous or permanent teeth.
- Radiopacities were interpreted as tori or exostoses, salivary calculus, tonsolith, or calcified lymph node.
- Solitary radiopacities in edentulous regions.
- Patients with Gardner's syndrome and other diseases with bone metabolic disturbance.

The shape of the BI was classified as either round or irregular. The location of the lesion was classified as mandibular or maxillary firstly, then further by region of the jaw: Incisive, canine, canine-premolar, pre-molar, pre-molar-molar or molar.

Radiopaque areas were classified according to site and internal characteristics as noted as follows^[3] [Figures 1, Types I-IV]:

- Type I. Interradicular: Limited to the area between the roots;
- Type II. Apical and interradicular: At the apices with extension between the roots;
- Type III. Separate: Apical and clearly separated from teeth and lamina dura;
- Type IV. Apical: Predominantly located around the apices of the roots.

Assessment of the study sample

All digital radiographs were viewed on the same LCD (liquid crystal display) monitor. Two well-trained examiners observed the radiographs after a period of mutual calibration without the knowledge of age and

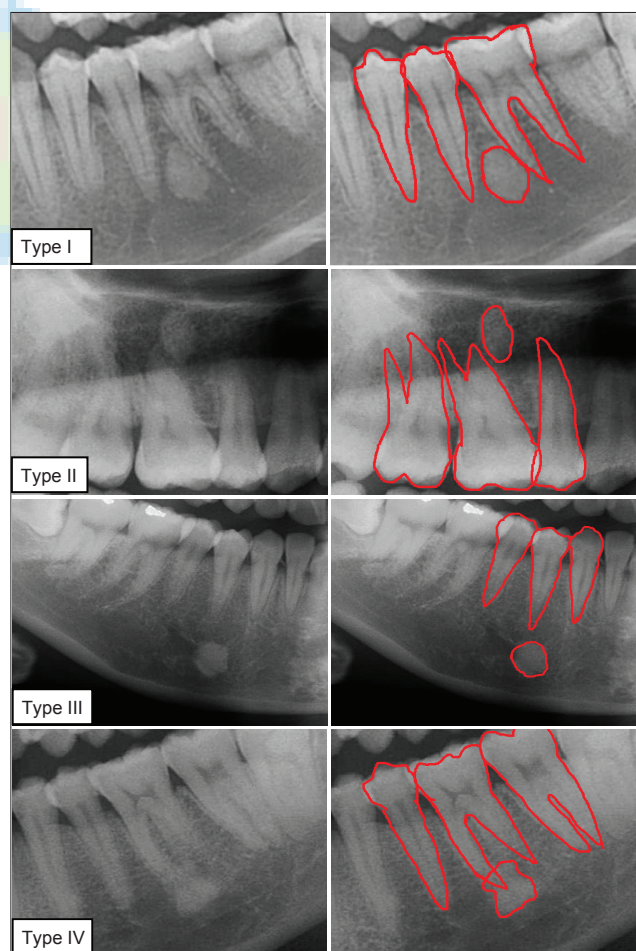
gender. Chi-square test was performed to evaluate the difference in the prevalence of BIs between gender groups and radiographic appearance of BIs. All statistical analyses were performed by using the SPSS 17.0 (SPSS Inc., Chicago, IL, USA) for Windows.

Reproducibility

To test intra- and inter-examiner reliabilities, two different examiners staged the prevalence of BIs on 100 randomly selected radiographs. Each examiner repeated the process after 1 month (intra-examiner), and Cohen's kappa test was performed to calculate the intra- and inter-examiner agreements.

RESULTS

Intra- and inter-observer differences were not found in the repeated observing of a sub-sample of 100 radiographs ($P > 0.05$). Intra-observer consistency was rated at 94%, whereas inter-observer agreement was 89%.



Figures 1: Bone islands in terms of dental relationships

Incidence

A total of 136 patients in the BIs group were identified from a total sample population of 7389 patients (incidence 1.84%).

Gender and age predilection

The patient population as a whole consisted of approximately 60.3% females and 39.7% males. The prevalence of BIs among females was 1.96% (82 females) and 1.64% (54 males) among males. There was no statistically significant difference in the prevalence of BIs between the males and females (Chi-square test, $P = 0.107$).

The ages of the study group ranged from 8 years to 80 years with a median of 24 years. The earliest age at which a BI was detected was 8 years. The number of BIs in the present study was found to be significantly higher in the 2nd decades and 3rd decades in life (10-19 and 20-29 years) than in other periods ($P < 0.01$) [Table 1].

The distribution predilection and presentation

Of the BIs we investigated, BIs was detected more often in the mandible than in the maxilla. There were 149 variations detected of 136 patients in the BIs group, and 142 (95.3%) were present in the mandible with only 7 (8.7%) in the maxilla. Of the subjects with multiple variations, 12 patients had 2 BIs, and 2 patients had 3 BIs.

Pre-molar and molar localization in the mandible was the most common localization, whereas in the maxilla, the most common location of BIs was the anterior area [Table 2].

DISCUSSION

To our knowledge, the study was the first study providing reference data of BIs in the jaws and using a large sample size in the West Chinese population. Previous studies showed that BIs, congenital or developmental in origin, are developmental variations of normal bone architecture unrelated to a local stimulant. None showed bony expansion buccolingually, nor did they displace adjacent teeth or bony anatomic structures. They can be found in the most parts of the skeleton with a frequency reported to be approximately 1%.^[4] The overall frequency of 1.84% in this survey was less than

previously reported by Geist and Katz^[2] In addition, in the past, a range of different prevalence rates were presented by Eliasson *et al.*,^[5] Miloglu *et al.*,^[6] Petrikowski and Peters^[7] and Williams and Brooks [Table 3].^[8] The main reason for the difference in prevalence rate might be the difference in ethnic group. Cavalli-Sforza *et al.*,^[9] divided the population of the world into four main ethnic groups. These are Africans, Australians, Europoids, and Mongoloids. According to the classification of the ethnic groups, Chinese population belongs to Mongoloids. Comparing with the other ethnic

Table 1: Age and sex distribution of individuals with BIs

Age (years)	Male	Female	Total	All patients	Percentage
0-9	1	0	1	101	0.99
10-19	24	37	61	2387	2.56
20-29	16	30	46	1819	2.53
30-39	5	7	12	1189	1.01
40-49	5	4	9	977	0.92
50-59	2	2	4	645	0.62
60+	1	2	3	271	1.11
Total	54	82	136	7389	1.84

BIs=Bone islands

Table 2: The localization of BIs in the maxilla and mandible

Localization	Maxilla				Mandibular			
	I	II	III	IV	I	II	III	IV
Incisive	0	0	0	1	0	0	1	1
Canine	0	1	0	1	0	2	2	2
Canine-premolar	0	0	0	0	0	3	4	3
Premolar	0	0	0	1	2	11	14	25
Premolar-molar	0	1	0	0	1	4	5	6
Molar	1	0	0	1	1	5	9	39
Total	1	2	0	4	4	25	35	76

BIs=Bone islands

Table 3: Study and patient characteristics of the reviewed studies for BIs

Reference (with name of the 1 st author and year)	Study group	Dateline (year)	Sample size	Prevalence of BIs %
Eliasson <i>et al.</i>	Sweden	1984	1,149	2.0
Geist and Katz	USA	1990	1,921	5.4
Kawai <i>et al.</i>	Japan	1992	1,203	6.1
Petrikowski and Peters	Canada	1997	2,991	3.1
Yonetsu <i>et al.</i>	Japan	1997	1,047	6.1
Williams and Brooks	USA	1998	1,585	5.7
Miloglu	Turkey	2009	6,154	2.44

BIs=Bone islands

groups, our results showed that the frequency of BIs was lower in Western Chinese population. Another reason for the difference in prevalence rate is the difference in definition for BIs. BIs used to be described as 'dense BI' by McDonnell,^[10] 'idiopathic osteosclerosis' by Geist and Katz^[2] or 'enostosis' by Eselman^[11]. In statistics, some authors included BIs, which appeared in periapical areas related to teeth as non-vital or significantly inflamed pulps; these lesions most likely represent a response to a low-grade inflammatory stimulus. Such reactive variations should be designated as condensing osteitis or focal chronic sclerosing osteomyelitis, and our study has excluded these conditions in the surveys. In addition, different ethnic groups living in different areas have special habits, genetic variations and addictions, which may also affect the frequency and distribution of BIs.

The same as Chinese, Japanese belong to the Mongoloids ethnic group. However, differences exist as well. Results of Yonetsu *et al.*,^[12] and Kawai *et al.*,^[13] reported that there was no significant difference in prevalence rate of BIs among age groups. One reason might be the different criteria. In our study, we excluded Solitary radiopacities in edentulous regions, which may represent as residual condensing osteitis or excessively ossified surgical sites, while Kawai *et al.*, included these conditions. The other reason is that our sample population is much greater than others. To our knowledge, the sample size of our study was the largest in examining the prevalence of BIs in the jaws to date.

In the present study, BIs of the jaws as areas of increased osseous density or radiopacities in the maxilla or mandible with defined borders are ascribed. There was no statistically significant difference in the prevalence of BIs between the males and females in our study. This finding agrees with Yonetsu *et al.*,^[12] and Kawai *et al.*,^[13] However, Geist and Katz^[2] and McDonnell^[10] reported a higher prevalence among women than among men. The main cause might be closely related to the sample size and age.

BIs can arise at any age, and furthermore the number of BIs was found to be significantly higher in the 2nd decades and 3rd decades in life (10-19 and 20-29 years) than in other periods [Table 1].

However, Miloglu^[6] found in the 3rd and 4th decades of life with a marked frequency. Based on the present study, the sample size and following criteria are the major factors behind the phenomenon. For instance, we excluded radiopacities occurring in edentulous regions, and these regions might also be areas of condensing osteitis that remained after tooth extraction. As another reason, the high prevalence of BIs lesions in the 2nd decades and 3rd decades in life (10-19 and 20-29 years) coincides with the maximum bone mass acquisition in these periods. Petrikowski and Peters,^[13] in their follow-up study on orthodontic patients with BIs and a mean age of 14 years, found that lesions are apt to change and grow, particularly during adolescence.

It is generally believed that BIs usually do not show radiographic evidence of change in size over time. Nonetheless, several studies have reported size changes in BIs, some of which exhibited metabolic activity.^[4,5,14,15] On the contrary, Geist and Katz^[2] suggested that BIs were an anatomic variation. In the present study, Separate BIs, that is Type III, accounted for 23.8%. These variations were clearly separated from the teeth, and there were no residual tooth fragments and stimulatory effects of excessive occlusion. It might be expected that the appearance of BIs in this area were a developmental anatomic variation.

On the other hand, BIs have an overwhelming mandibular predilection that account 95.3% (142), with presentation primarily in the pre-molar/molar region. There is no doubt that panoramic radiographs have more problems in the maxilla than in the mandible about the superimposition of anatomic structures. Another reason might be the differences in blood supply and anatomy of the jaws.

CONCLUSIONS

In light of the present study, BIs can arise at any age, any location with no sex predilection, and have an overwhelming mandibular predilection, with presentation primarily in the pre-molar/molar region. The presumptive diagnosis of a BI can easily be made if the individual clinical and radiologic findings, together with follow-up examinations, are taken into account. In addition, it is important to

recognize this anomaly, evaluate radiographies carefully and distinguish it from other bone variations such as primary or metastatic tumours, which is much more significant clinically in dental examinations.

The authors express their sincere appreciations to all the observers who assessed the test radiographs.

REFERENCES

1. Greenspan A. Sclerosing bone dysplasias – A target-site approach. *Skeletal Radiol* 1991;20:561-83.
2. Geist JR, Katz JO. The frequency and distribution of idiopathic osteosclerosis. *Oral Surg Oral Med Oral Pathol* 1990;69:388-93.
3. Wood NK, Goaz PW. Differential diagnosis of oral lesions and maxillofacial lesions. Mosby St. Louis; 1997.
4. Onitsuka H. Roentgenologic aspects of bone Islands. *Radiology* 1977;123:607-12.
5. Eliasson S, Halvarsson C, Ljungheimer C. Periapical condensing osteitis and endodontic treatment. *Oral Surg Oral Med Oral Pathol* 1984;57:195-9.
6. Miloglu O, Yalcin E, Buyukkurt MC, Acemoglu H. The frequency and characteristics of idiopathic osteosclerosis and condensing osteitis lesions in a Turkish patient population. *Med Oral Patol Oral Cir Bucal* 2009;14:e640-5.
7. Petrikowski CG, Peters E. Longitudinal radiographic assessment of dense bone islands of the jaws. *Oral Surg Oral Med Oral Pathol Oral Radiol Endod* 1997;83:627-34.
8. Williams TP, Brooks SL. A longitudinal study of idiopathic osteosclerosis and condensing osteitis. *Dentomaxillofac Radiol* 1998;27:275-8.
9. Cavallisforza LL, Menozzi P, Piazza A. The history and geography of human genes. Princeton, New Jersey, US: Princeton University Press; 1994.
10. McDonnell D. Dense bone island. A review of 107 patients. *Oral Surg Oral Med Oral Pathol* 1993;76:124-8.
11. Eselman JC. A roentgenographic investigation of enostosis. *Oral Surg Oral Med Oral Pathol* 1961;14:1331-8.
12. Yonetsu K, Yuasa K, Kanda S. Idiopathic osteosclerosis of the jaws: Panoramic radiographic and computed tomographic findings. *Oral Surg Oral Med Oral Pathol Oral Radiol Endod* 1997;83:517-21.
13. Kawai T, Hirakuma H, Murakami S, Fuchihata H. Radiographic investigation of idiopathic osteosclerosis of the jaws in Japanese dental outpatients. *Oral Surg Oral Med Oral Pathol* 1992;74:237-42.
14. Blank N, Lieber A. The significance of growing bone Islands. *Radiology* 1965;85:508-11.
15. Go RT, El-Khoury GY, Wehbe MA. Radionuclide bone image in growing and stable bone Island. *Skeletal Radiol* 1980;5:15-8.

How to cite this article: Li N, You M, Wang H, Ren J, Zhao S, Jiang M, Xu L, Liu Y. Bone islands of the craniomaxillofacial region. *J Cranio Max Dis* 2013;2:5-9.

Source of Support: Nil. **Conflict of Interest:** There is no conflict of interest. **Submission:** February 20, 2013, **Acceptance:** April 21, 2013

Announcement

Android App



Download
**Android
application**

FREE

A free application to browse and search the journal's content is now available for Android based mobiles and devices. The application provides "Table of Contents" of the latest issues, which are stored on the device for future offline browsing. Internet connection is required to access the back issues and search facility. The application is compatible with all the versions of Android. The application can be downloaded from <https://market.android.com/details?id=comm.app.medknow>. For suggestions and comments do write back to us.