

Orthodontic Extraction of High-Risk Impacted Mandibular Third Molars in Close Proximity to the Mandibular Canal: A Systematic Review

Mahmood Reza Kalantar Motamedi, DDS,* Majid Heidarpour, DDS, MS,†
Sara Siadat, DDS,‡ Alimohammad Kalantar Motamedi, DMD, MSD,§
and Ali Akbar Babreman, DDS, MS||

Purpose: Extraction of mandibular third molars (M3s) in close proximity to the mandibular canal has some inherent risks to adjacent structures, such as neurologic damage to teeth, bone defects distal to the mandibular second molar (M2), or pathologic fractures in association with enlarged dentigerous cysts. The procedure for extrusion and subsequent extraction of high-risk M3s is called *orthodontic extraction*. This is a systematic review of the available approaches for orthodontic extraction of impacted mandibular M3s in close proximity to the mandibular canal and their outcomes.

Materials and Methods: The PubMed, Scopus, Cochrane Central Register of Controlled Trials (CENTRAL), DOAJ, Google Scholar, OpenGrey, Iranian Science Information Database (SID), Iranmedex, and Irandoc databases were searched using specific keywords up to June 2, 2014. Studies were evaluated based on predetermined eligibility criteria, treatment approaches, and their outcomes.

Results: Thirteen articles met the inclusion criteria. A total of 123 impacted teeth were extracted by orthodontic extraction and 2 cases were complicated by transient paresthesia. Three types of biomechanical approaches were used: 1) using the posterior maxillary region as the anchor for orthodontic extrusion of lower M3s, 2) simple cantilever springs attached to the M3 buttonhole, and 3) cantilever springs tied to a bonded orthodontic bracket on the M3 plus multiple-loop spring wire for distal movement of the M3. Osteo-periodontal status of M2s also improved uneventfully.

Conclusion: Despite the drawbacks of orthodontic extraction, removal of deeply impacted M3s using the described techniques is safe with regard to mandibular nerve injury and neurologic damage. Orthodontic extraction is recommended for extraction of impacted M3s that present a high risk of postoperative osteo-periodontal defects on the distal surface of the adjacent M2 and those associated with dentigerous cysts.

© 2015 American Association of Oral and Maxillofacial Surgeons
J Oral Maxillofac Surg 73:1672-1685, 2015

*Scientific Researcher, Department of Orthodontics, School of Dentistry, Isfahan Branch, Islamic Azad University, Isfahan, Iran.

†Assistant Professor, Dental Materials Research Center, and Department of Orthodontics, School of Dentistry, Isfahan University of Medical Sciences, Isfahan, Iran.

‡Postgraduate Student, Department of Orthodontics, School of Dentistry, Isfahan Branch, Islamic Azad University, Isfahan, Iran.

§Assistant Professor, Department of Orthodontics, School of Dentistry, Isfahan Branch, Islamic Azad University, Isfahan, Iran.

||Clinical Professor, Orthodontic and Pediatric Dentistry Programs, Eastman Institute for Oral Health, University of Rochester, NY.

Conflict of Interest Disclosures: None of the authors reported any disclosures.

Address correspondence and reprint requests to Dr A. Kalantar Motamedi: Department of Orthodontics, School of Dentistry, Isfahan Branch, Islamic Azad University, Isfahan 81551-39998, Iran; e-mail: a_motamedi@hotmail.com

Received September 13 2014

Accepted March 9 2015

© 2015 American Association of Oral and Maxillofacial Surgeons

0278-2391/15/00282-7

<http://dx.doi.org/10.1016/j.joms.2015.03.031>

Extraction of mandibular third molars (M3s) is one of the most common procedures in oral and maxillofacial surgery.^{1,2} However, this procedure has some potential risks and complications, including nerve damage and paresthesias, which can be temporary or permanent.^{3,4} The risk of inferior alveolar nerve (IAN) injury increases when the roots of impacted mandibular M3s are in close proximity to the mandibular canal.^{1,2,5} Damage to this nerve has been reported to occur in up to 8.4% of cases.⁶⁻⁸

Bone defects adjacent to the site of extraction and distal to the second molar (M2) are other potential complications of extracting impacted M3s. These defects are more likely to occur in patients older than 25 years, those with high plaque scores, those with pre-existing unhealthy periodontium around the M2s, and after the extraction of mesioangular and horizontally impacted teeth. At times, impacted mandibular M3s have been associated with an enlarged dentigerous cyst that can lead to bone resorption and pathologic fractures.⁹ Moreover, as cysts become larger, the risk of postoperative neurologic damage and bone defects increases.^{10,11}

There are several ways to decrease the risk of nerve injury after the extraction of impacted mandibular M3s. Pogrel et al¹² introduced coronectomy (intentional partial odontectomy), which is sectioning of the crown and leaving the roots in situ, for high-risk impacted mandibular M3s. This method leads to spontaneous mesial migration of the roots of the impacted M3 owing to the elimination of contact between the crown of the M3 and the distal surface of the mandibular M2.^{12,13} Although this technique considerably decreases the risk of nerve injury compared with traditional total extraction of the impacted M3,¹⁴ it has some limitations. Because of possible pulp chamber exposure with this technique, the IAN is at risk of apical periodontitis.¹⁵ Infection,^{13,16} failed coronectomy, reoperation, root migration, root exposure,^{15,17,18} hypersensitivity, and food impaction are other possible adverse outcomes associated with this method.

Guided tissue regeneration has been proposed as a possible treatment for osteo-periodontal defects after removal of impacted M3s. However, outcomes have been controversial.¹⁹⁻²⁴ In addition, postoperative inflammatory complications associated with the use of bone substitutes are other limitations of guided tissue regeneration therapy.^{19-21,24}

Orthodontic extraction is another technique that decreases the risk of IAN injury. It is a combined orthodontic-assisted surgical approach that decreases the risk of neurologic complications and facilitates the surgical extraction of impacted mandibular M3s that are in close proximity to the mandibular canal,²⁵⁻²⁷ even when associated with cystic

lesions.^{27,28} This method can also improve the osteo-periodontal status of the M2s that are adjacent to the impacted M3.^{27,29} Orthodontic extraction is reported to be safe with regard to nerve injury³⁰ and to have good postoperative outcomes for the periodontium of the mandibular M2.^{27,29} However, it is expensive and time consuming. Moreover, some patients might not tolerate the presence of orthodontic appliances in their oral cavity. The indications for orthodontic extraction are discussed in this article.

Many different orthodontic therapies have been reported in the literature, each with certain advantages and disadvantages.²⁵⁻³⁴ It is important for dentists to be aware of these options and know the risks, benefits, and outcomes to tailor their treatment plan to meet each patient's specific needs.

This study is a systematic review of the available orthodontic approaches to extract impacted mandibular M3s in close proximity to the mandibular canal and their outcomes.

Materials and Methods

ELIGIBILITY CRITERIA

Study Types

The authors searched for case reports, case series, retrospective analyses, and clinical trials that reported orthodontic extraction of M3s with high risk of IAN injury. They did not find any prospective clinical trials.

Patient Population

The study population included all patients scheduled for elective surgical removal of impacted mandibular M3s in close proximity to the mandibular canal as visualized by radiographic examination.

SEARCH STRATEGY

The authors reviewed PubMed, Scopus, Cochrane Central Register of Controlled Trials (CENTRAL), DOAJ, Google Scholar, and the Grey Literature of OpenGrey up to June 2, 2014 for the following key terms: *orthodontic, orthodontic extraction, orthodontic extrusion, nerve, mandibular nerve, inferior alveolar nerve, inferior dental nerve, and third molar*. No language limitation was used for the selection of studies. In addition, the following national databases were included: the Iranian Science Information Database (SID; <http://www.sid.ir/>), Iranmedex (<http://www.iranmedex.com/>), and the Iranian Research Institute for Information Science and Technology (IranDoc; <http://www.irandoc.ac.ir>). The authors also reviewed each article's references to find any articles that were not in the initial literature search. Corresponding authors were contacted by e-mail for missing and

unreported data. Articles were excluded if the author did not provide the requested information.

STUDY SELECTION

Two independent evaluators (M.R.K.M. and S.S.) performed the literature searches and reviewed the articles. Disagreements between evaluators were resolved by discussion until a consensus agreement was reached.

DATA COLLECTION

The following data were collected for each study: author, year, country of origin, study design, participants, diagnostic imaging modality used, IAN injury, osteo-periodontal status, length of follow-up, length of treatment and retention phases, checkup intervals, inclination of M3s, summary of treatment, crown sectioning performed, occurrence of infection and swelling, and surgical procedures.

Data were collected by 3 independent evaluators (M.R.K.M., M.H., and S.S.) and disagreements were resolved by discussion.

Results

INCLUDED STUDIES

After eliminating duplicates and irrelevant studies based on title and abstract, 15 studies were selected. Two other studies were excluded owing to incomplete data, such as exact number of participants, duration of treatment, treatment failures, or occurrence of nerve injury.^{32,35} Thirteen articles,^{25-29,31-38} consisting of 2 case series, 9 case reports, and 2 retrospective cohort

studies, were included for data extraction. The authors did not find any prospective clinical trials or any non-English-language articles. The flow diagram of electronic searches and study selection is shown in Figure 1.

STUDY CHARACTERISTICS

General Finding

The selected studies consist of publications from August 1996 to March 2014 and the number of impacted mandibular M3s ranged from 1 to 64, with a total of 143 cases of mandibular impactions reported.

One hundred twenty-three impacted mandibular M3s were extracted by an orthodontic-assisted technique and 20 were extracted by the traditional method. General characteristics and details of orthodontic approaches from each study are presented in Tables 1 and 2, respectively.

Radiographic Assessment

Initial examination in nearly all the studies was based on panoramic images to assess the distance between M3s and the mandibular canal. Computed tomographic (CT) or cone-beam CT (CBCT) images were obtained to determine the exact position of the impacted M3s. Radiographic evaluations by Celebi et al³⁶ and Guida et al³⁵ were based only on panoramic images.

Ma et al²⁶ used predetermined criteria for the initial diagnosis of tooth proximity to the mandibular canal. The following radiologic characteristics were accepted as indicators of probable root proximity to the IAN: diversion of the mandibular canal, darkening

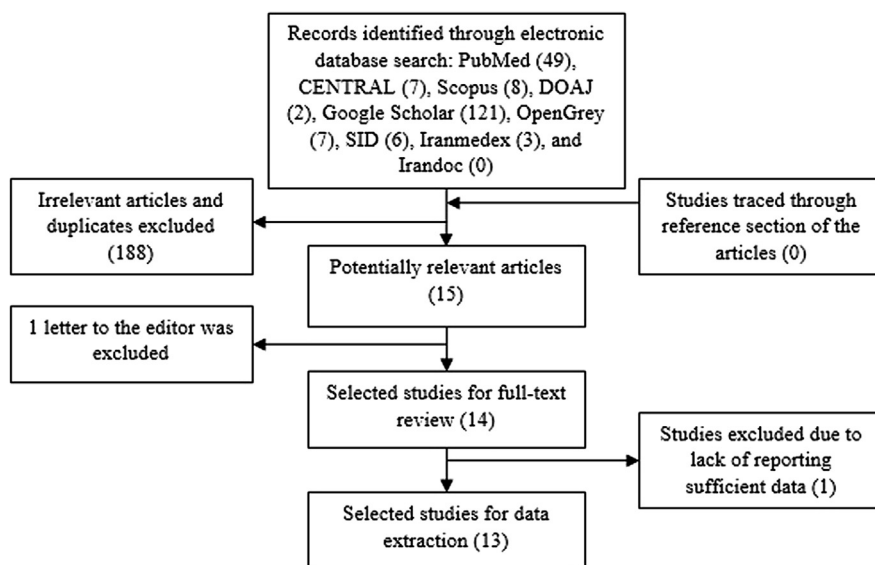


FIGURE 1. Flowchart of article selection.

Table 1. GENERAL CHARACTERISTICS OF SELECTED STUDIES

Study	Year	Country	Study Design	Participants	Primary Diagnostic Radiography	IANI	Osteo-Periodontal Status of M2	Follow-Up Period
Wang et al ³²	2012	China	cohort retrospective study	40 lower M3s (n = 20 orthodontic extraction; n = 20 traditional total extraction), 40 F, mean age 24.5 yr	panoramic and CT	no damage in orthodontic extraction group; 5 transient IANIs in traditional extraction group (25%)	not recorded	0
Hirsch et al ³⁴	2003	Israel	case series	18 lower M3s, 7 M, 11 F, mean age 23.3 ± 0.9 yr	panoramic and CT (for exceptional situations, PA, oblique lateral radiographs, and CBCT used)	no	distobuccal PPD: B: 7.9 ± 1.6, A: 1.8 ± 0.7 (<i>P</i> < .001); distolingual PPD: B: 7.4 ± 1, A: 1.9 ± 0.7 (<i>P</i> < .001); CAL: B: 5.4 ± 1, A: 0.4 ± 0.5 (<i>P</i> < .001); keratinized tissue: B: 2.9 ± 0.7, A: 3.8 ± 0.6 (<i>P</i> < .001)	23.56 ± 1.25 mo
Flanagan ³⁷	2012	USA	case report	3 lower M3s, 3 M, mean age 34 yr	panoramic and CBCT	no	not recorded	0
Checchi et al ²⁵	1996	Italy	case report	2 lower M3s of 21-yr-old F	panoramic and CT	no	not recorded	0
Alessandri Bonetti ³³	2008	Italy	case report	1 lower M3 of 28-yr-old M	panoramic and CT	no	distobuccal PPD: B: 7, A: 2; distolingual PPD: B: 11, A: 3; CBL: B: 14, A: 2	3 yr
Montevecchi et al ²⁹	2014	Italy	cohort retrospective study	64 lower M3s, 27 M, 37 F, mean age 30 ± 9 yr	panoramic and CBCT	no	distolingual, mid-distal, and distobuccal PPD: B: 10, A: 4 (<i>P</i> < .0001); CAL: B: 10, A: 4 (<i>P</i> < .0001)	24 ± 11 mo
Montevecchi et al ²⁷	2012	Italy	case report	1 lower M3 of 33-yr-old M	panoramic and CT	no	distolingual PPD: B: 9, A: 2; distobuccal PPD: B: 7, A: 3; CBL: B: 16, A: 2	2 yr
Marchetti et al ²⁸	2004	Italy	case report	1 lower M3 of 53-yr-old M	panoramic and CT	no	radiographic examination showed good results	1 and 6 mo
Celebi et al ³⁶	2012	Turkey	case report	1 lower M3 of 33-yr-old F	panoramic	transient paresthesia occurred and improved rapidly	not recorded	3 mo

Table 1. Cont'd

Study	Year	Country	Study Design	Participants	Primary Diagnostic Radiography	IANI	Osteo-Periodontal Status of M2	Follow-Up Period
Guida et al ³⁵	2011	Italy	case report	1 lower M3 of 21-yr-old F	panoramic and PA	no	distobuccal PPD: B: 4, A: 1; distolingual PPD: B: 8, A: 3	3 yr
Yekiner et al ³⁸	2014	Turkey	case report	1 lower M3 of 41-yr-old F	panoramic and CBCT	no	PA radiography showed good healing	6 mo
Ma et al ²⁶	2013	China	case series	8 lower M3s, 5 M, 3 F; mean age 29.4 yr	panoramic and CBCT	no	CBCT showed good bone apposition	0
Park et al ³¹	2010	Korea	case report	2 lower M3s, 2 F; mean age 31.5 yr	panoramic and CT	1 temporary paresthesia occurred and disappeared by 3 mo	not recorded	0

Abbreviations: CAL, clinical attachment level; CBCT, cone-beam computed tomography; CBL, crestal bone loss; CT, computed tomography; F, female; IANI, inferior alveolar nerve injury; M, male; M2, second molar; M3, third molar; PA, periapical; PPD, probing pocket depth.

Kalantar Motamedli et al. *Orthodontic Extraction of Impacted Third Molar. J Oral Maxillofac Surg* 2015.

of the root, interruption of the canal walls, and narrowing of the root. Panoramic images showing interruption of the IAN was used in 3 patients, diversion in 2, darkening of the root in 2, and narrowing in 1. Park et al³¹ described a case of the IAN crossing the root of the M3; the superimposed area exhibited a different radiodensity and a radiolucent band according to the criteria of Rood et al.³⁹

The other included studies did not report any diagnostic criteria for the determination of the proximity of the M3 root to the mandibular canal.

Surgical Procedure (First Surgery)

Surgical exposure was dependent on the level of impaction. In some cases of superficial semi-impactions, surgical exposure was not necessary and the bracket was attached directly to the occlusal surface of the tooth.^{26,34} However, surgical exposure, including elevation of a full-thickness mucoperiosteal flap and osteotomy, were necessary in most cases.^{25-29,31,32,34-38}

Orthodontic Mechanotherapy

Figure 2 presents a summary of the orthodontic mechanical therapies used in the included studies. It should be noted that this figure does not provide the exact details of the mechanical therapies; however, it is meant to be a suitable guide for easier comprehension.

Wang et al³² published a retrospective study of 40 surgical candidates for removal of impacted mandibular M3s with risk of IAN injury. Twenty patients underwent orthodontic extraction and the remaining patients underwent traditional total extraction by the same surgeon.

In the first group, rubber bands were used to apply force and the anchorage unit was placed in the posterior maxillary segment (Fig 2). Brackets were placed on the opposing maxillary molars (4 posterior teeth) and, if the maxillary molars were missing or had inadequate crowns for anchorage, bone miniscrews were installed in the posterior maxilla (between the upper molars).

For vertically or distally positioned M3s, rubber bands were fixed between the mandibular M3 and maxillary anchorage screws or brackets, and then fine steel wires were used to fix the rubber bands in place. For mesially inclined M3s, the crown was sectioned on the mesial aspect to avoid impaction of the M3 behind the mandibular M2 during traction (Fig 2). For horizontally inclined teeth, the crown was cut off before application of traction to prevent uncontrolled movement of the roots during elastic traction. Patients were instructed to perform daily mouth-opening exercises to help with mandibular M3 traction.

Table 2. DETAILS OF ORTHODONTIC APPROACHES EMPLOYED IN THE SELECTED STUDIES

Study	Length of Treatment Phase	Length of Retention Phase	Checkup Interval	M3 Inclination	Summary of Orthodontic Approach	Crown Sectioning
Wang et al ³²	3-10 wk (mean 35 days)	0	every 2-3 wk	mesially, vertically, and distally inclined (corresponding numbers were not reported)	extrusion of M3 using maxillary teeth as anchorage or bone miniscrew in posterior maxilla if molars were missing or had inadequate crowns for anchorage	mesioangular M3s crowns were sectioned; horizontally M3s crowns were removed
Hirsch et al ³⁴	3 mo	0	every 2 wk	3 diagonally, 9 horizontally, 6 vertically inclined	3 approaches were used: attachment of bracket, placement of post in root canal, or placement of orthodontic wire through buccolingual canal of M3; M3s were extruded using maxillary teeth as anchorage	14 M3s were sectioned (pulp extirpation performed for post placement)
Flanagan ³⁷	6-10 wk	0	every 2-3 wk	3 mesially inclined	posterior maxillary teeth as anchorage, extrusion with elastomeric chain	all M3 crowns were sectioned
Checchi et al ²⁵	3 mo	0	every month	2 mesially inclined	1 SS cantilever spring was inserted in pre-existing occlusal amalgam filling connected to M3 with rubber band; bicuspid and molars were reinforced with twisted SS wire (0.036 inch) on buccal surface and bonded directly using composite resin; no lingual arch was used	no
Alessandri Bonetti et al ³³	5 mo	3 mo	not mentioned	1 mesially inclined	cantilever spring applied to M1 and tied to occlusal surface M3; anchorage reinforced by lingual arch from M1 to M1 and sectional archwire on premolars and molars	no
Montevecchi et al ²⁹ (2014)	6 ± 2 mo	3 ± 1 mo	not mentioned	28 horizontally, 12 vertically, 24 mesially inclined	cantilever spring applied to M1 and tied to occlusal surface of M3; anchorage reinforced by lingual arch from M1 to M1 and sectional archwire on premolars and molars	no
Montevecchi et al ²⁷ (2012)	7 mo	3 mo	not mentioned	1 vertically inclined	marsupialization of cyst combined with orthodontic extraction; active force applied using cantilever spring bonded to M1 and tied to button on occlusal surface of M3; anchorage reinforced by lingual arch from M1 to M1 and passive sectional SS wire bonded directly to buccal surface of lower molars and premolars using light-cure composite resin	no

Table 2. Cont'd

Study	Length of Treatment Phase	Length of Retention Phase	Checkup Interval	M3 Inclination	Summary of Orthodontic Approach	Crown Sectioning
Marchetti et al ²⁸	3 mo	0	not mentioned	1 vertically inclined	marsupialization of cyst combined with orthodontic extraction; 1 sectional SS wire inserted in lower molars and premolars and connected to M3 with elastic force; anchorage of M1 reinforced with lower lingual arch	no
Celebi et al ³⁶	4 mo	0	every month	1 vertically inclined	marsupialization of cyst combined with orthodontic extraction; extrusion by cantilever spring connected to M3 with elastic thread; no lingual arch used	no
Guida et al ³⁵	5 mo	0	not mentioned	1 mesially inclined	orthodontic extrusion with cantilever sectional SS wire applied to premolars and molars tied to M3 attachment; no lingual arch used	all M3 crowns were slightly sectioned
Yetkiner et al ³⁸	9 mo	0	not mentioned	1 mesially inclined	0.016- × 0.016-inch rectangular SS cantilever arm passively fitting the buccal aspects of premolars and M1 with loop medially positioned to M1 tied to a wire ligature extending from M3; no lingual arch used	no
Ma et al ²⁶	4-10 mo (mean 6.6 mo)	0	every month	2 horizontally, 4 mesially, 2 vertically inclined	3-loop spring wire with 4- to 5-mm activation move M3 distally; then, a 0.017- × 0.025-inch TMA cantilever spring was hooked on main archwire to extrude tooth; lingual arch from M2 to M2 reinforced anchorage	no
Park et al ³¹	6-9 mo (mean 7.5 mo)	0	not mentioned	2 vertically inclined	leveling M3 with 0.016-inch NiTi wire and thus active extrusion by 0.016- × 0.022-inch SS spring wire using miniscrew attached to second premolar and M1 for maximum skeletal anchorage	no

Abbreviations: M1, first molar; M2, second molar; M3, third molar; NiTi, nickel and titanium; SS, stainless steel; TMA, tungsten and molybdenum alloy.

Kalantar Motamedi et al. Orthodontic Extraction of Impacted Third Molar. J Oral Maxillofac Surg 2015.

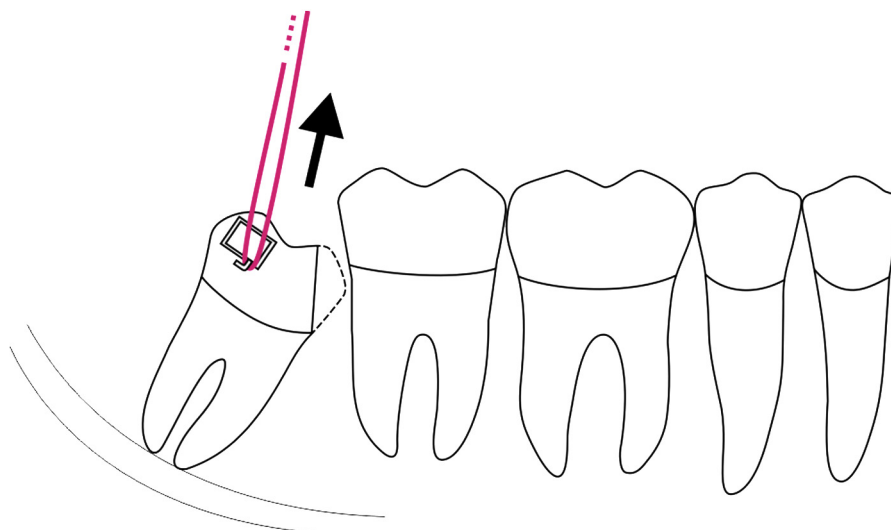


FIGURE 2. Using rubber bands as the source of force and the posterior maxillary segment as the anchorage unit.

Kalantar Motamedi et al. Orthodontic Extraction of Impacted Third Molar. J Oral Maxillofac Surg 2015.

Hirsch et al³⁴ used the maxillary teeth as an anchorage unit and applied orthodontic force with rubber bands, elastomeric chains, or orthodontic wires to the impacted mandibular M3. Force was applied to impacted M3s by orthodontic brackets (Fig 2), placement of a post in the root canal, or drilling a buccolingual hole in the M3 crown. Because the movement of the lower M3s is uncontrolled in this biomechanical system and the force direction is usually occlusal and mesial, the tooth will tend to tip mesially and extrude.

Flanagan³⁷ used at least 2 posterior maxillary teeth as anchorage units for extrusive force application and an elastomeric chain, which was flaccid in

maximum intercuspation and active in maximum freeway space applied for traction (Fig 2). This technique follows similar biomechanics as the other aforementioned techniques. Patients were also instructed to perform cyclic depression of the mandible to increase elastic tension.

Checchi et al²⁵ bonded a 0.018- \times 0.25-inch stainless steel wire to the distal boxes of lower M2s to form a cantilever, extruding the mandibular M3 with rubber bands to the occlusal surface of the M3 (Fig 3). This method overcomes the difficulties of M3 extrusion by using the opposing arch as anchorage. The lower molars and premolars were used as anchorage units and were connected with a 0.036-inch twisted steel

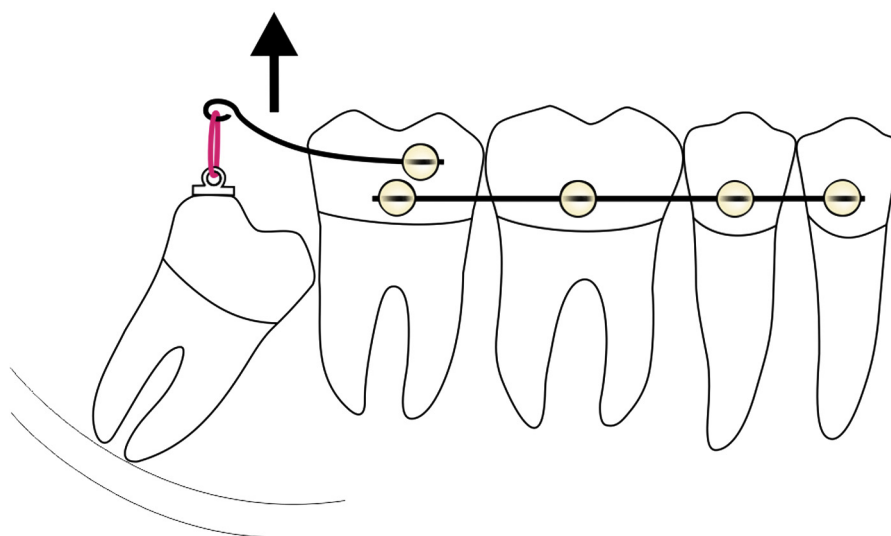


FIGURE 3. Using a type of cantilever for extruding the mandibular third molar with rubber bands.

Kalantar Motamedi et al. Orthodontic Extraction of Impacted Third Molar. J Oral Maxillofac Surg 2015.

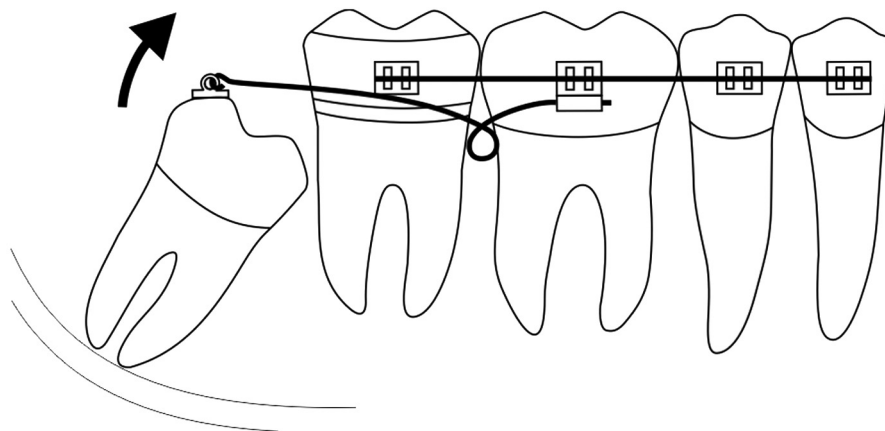


FIGURE 4. Using a cantilever spring in the auxiliary tube of the mandibular first molar to extrude the impacted mandibular third molar.

Kalantar Motamedi et al. *Orthodontic Extraction of Impacted Third Molar. J Oral Maxillofac Surg* 2015.

wire, which was directly bonded to them. No lingual arch was used in this study.

In a similar approach, Alessandri Bonetti et al³³ used a cantilever spring in the auxiliary tube of the mandibular first molar (M1) to extrude the impacted M3 (Fig 4). The attachment was a stiff wire bonded to the occlusal surface of the M3 and a lingual arch was used between the molars to increase their anchorage. Although the orthodontic movement in this approach is uncontrolled tipping, these biomechanical systems are more consistent for the type and direction of applied force.

In 2014, Montevecchi et al²⁹ applied the same cantilever spring used by Checchi et al²⁵ and Alessandri Bonetti et al^{30,33} in a retrospective cohort study of periodontal healing after orthodontic extraction of impacted M3s.

In other case reports, Montevecchi et al²⁷ (in 2012), Marchetti et al,²⁸ and Celebi et al³⁶ used a similar

cantilever for extrusion of impacted M3s around which dentigerous cysts had formed. As seen in Figure 5, Marchetti et al²⁸ used a sectional wire to connect the elastic band to the buttonhole bracket owing to deep impaction of the M3. Celebi et al³⁶ were the only group who did not use a lingual arch. Guida et al³⁵ and Yetkiner et al³⁸ applied cantilever force systems for orthodontic extraction of the impacted mandibular M3s. In these 2 studies, no lingual arch was applied.

Ma et al²⁶ proposed a 2-step method for orthodontic extraction of lower M3s. In the first stage, a multiple-loop stainless steel spring wire was used to distally move mesially impacted teeth (Fig 6A); in the second stage, the tooth was tipped back and upright and extracted using a spring hooked to the main archwire (Fig 6B). The force system applied by their tungsten and molybdenum alloy (TMA) spring is shown in

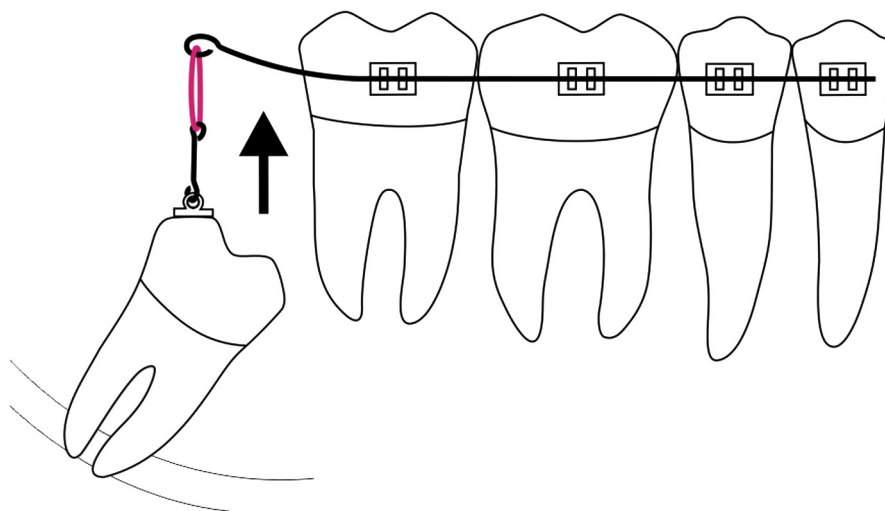


FIGURE 5. Using a sectional wire to connect the elastic band to the buttonhole bracket owing to deep impaction of the mandibular third molar.

Kalantar Motamedi et al. *Orthodontic Extraction of Impacted Third Molar. J Oral Maxillofac Surg* 2015.

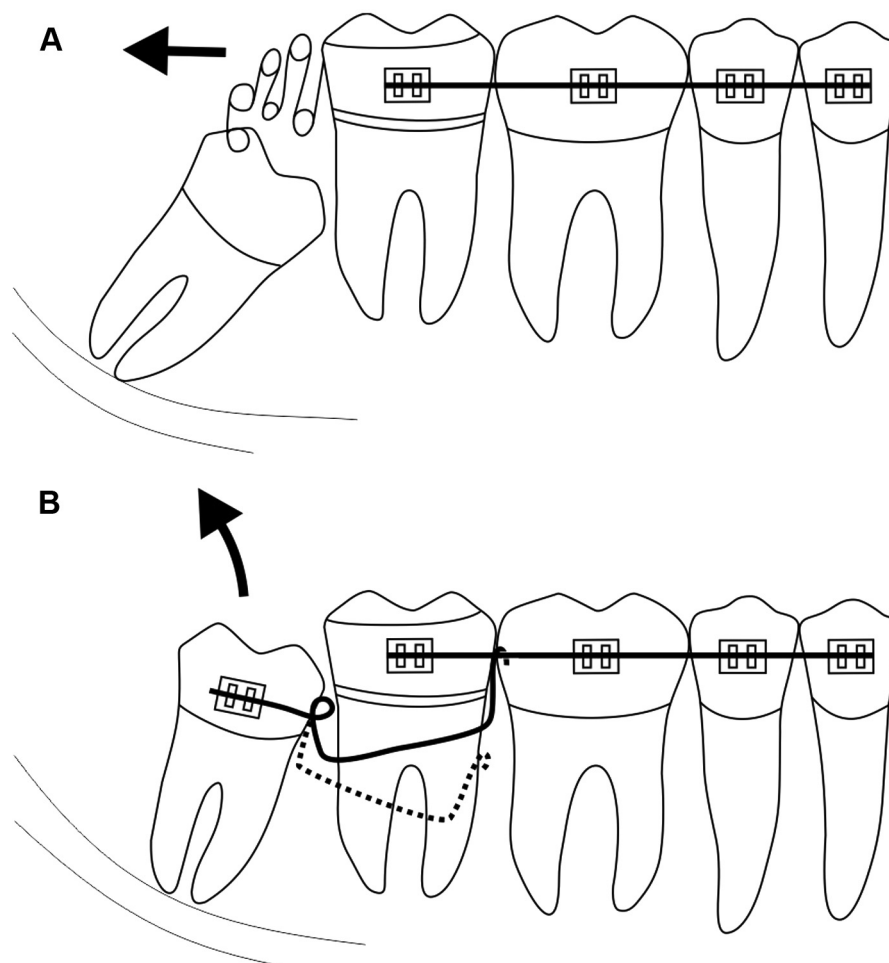


FIGURE 6. Using a 2-step method for orthodontic extraction of the mandibular third molar. A, In the first stage, a multiple-loop stainless steel spring wire is used to distally move mesially impacted teeth. B, In the second stage, the tooth is tipped back and upright and extracted using a spring hooked to the main archwire.

Kalantar Motamedi et al. Orthodontic Extraction of Impacted Third Molar. *J Oral Maxillofac Surg* 2015.

Figure 6. As depicted in this schematic, the moment of couple applied to the M3 bracket applies intrusive and extrusive forces on the anchorage unit and M3, respectively. At the same time, the TMA wire creates a counterclockwise movement against the M3 and moves it upright. Ma et al used a lower lingual arch between the M2s to improve the anchorage unit.

Park et al³¹ introduced a technique of M3 extraction, in which a continuous nickel and titanium archwire was used in the leveling stage of treatment (Fig 7A); subsequently, a 0.016- × 0.22-inch stainless steel archwire with a loop was used to actively extrude the M3 in the second stage (Fig 7B). The anchorage unit was strengthened with a miniscrew installed between the mandibular second premolar and the M1 (Fig 7A, B). Skeletal anchorage was achieved by bonding the second premolar and M1 to the miniscrew with the aid of wire and resin. In this method, maximal anchorage was achieved without a lingual arch.

Duration of Treatment

Regardless of the retention phase used,^{27,29,33} the duration of orthodontic treatment varied from 3 weeks to 10 months in different studies (Table 2). If a retention phase was used, an extra 2 to 4 months was added to the treatment duration. The orthodontic approach used by Wang et al³² and Flanagan³⁷ took the shortest time (Table 2).

Removal of Impacted M3 (Second Surgery)

Before extraction of the extruded M3, the safety of extraction should be re-evaluated by imaging. The minimum safe distance between the nerve and root apex was reported only in a few studies and was 1 to 2 mm.^{32,37}

All the included studies emphasized the ease of extraction of the extruded M3s owing to the mobility and accessibility of the tooth and reported minimal postoperative complications or discomfort.

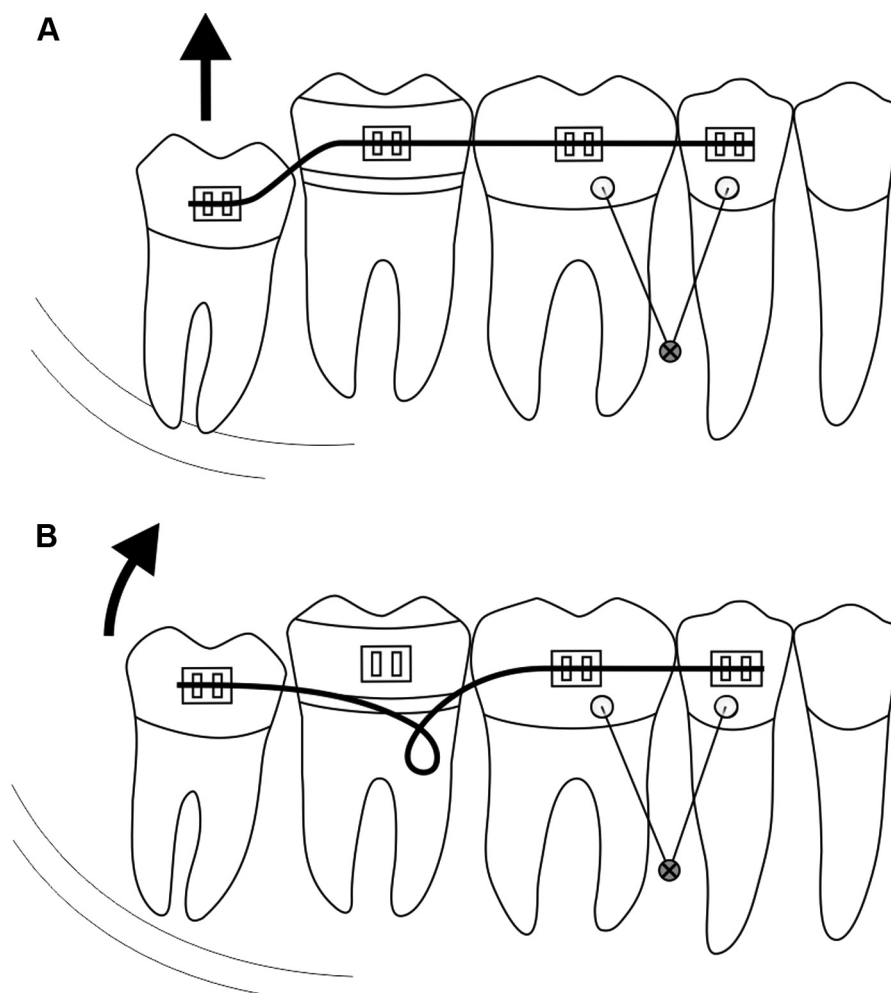


FIGURE 7. Using a 2-step method for orthodontic extraction of the mandibular third molar. A, A continuous nickel-titanium archwire is used in the leveling stage of treatment. B, Subsequently, a stainless steel archwire with a loop is used to actively extrude the mandibular third molar. In this schematic, the anchorage unit is strengthened with a miniscrew.

Kalantar Motamedei et al. Orthodontic Extraction of Impacted Third Molar. *J Oral Maxillofac Surg* 2015.

Periodontal Status

Table 1 presents a summary of studies that evaluated the periodontal status of mandibular M2s before and after removal of the M3s.

Osteo-periodontal status was evaluated by clinical factors such as periodontal probing pocket depth (PPD),^{27,29,33-35} clinical attachment level (CAL),^{29,34} keratinized tissue gain,³⁴ and radiographic crestal bone loss (CBL)^{27,33} (Table 1). In total, the osteo-periodontal status improved uneventfully.

Three studies reported radiographic evidence of good osteo-periodontal results or healing after their follow-up, but did not report their predetermined criteria (eg, PPD, CAL, CBL, etc) for such claims.^{26,28,38}

Cyst Management

In 3 studies,^{27,28,36} the impacted mandibular M3s in close proximity to the IAN were associated with cystic disease. These investigators used

marsupialization during the first surgery. During orthodontic extraction of the tooth, the cyst exhibited considerable shrinkage. At the end of treatment, when the impacted tooth was extracted, the cysts were enucleated. However, Celebi et al³⁶ failed to complete the orthodontic migration of the impacted M3 because the mesial cusp of the M3 was trapped under the M2 distal surface; therefore, they removed the tooth and enucleated the cyst at a second surgery. This incomplete procedure led to transient paresthesia. Follow-up radiographs showed good postoperative results regarding the osteo-periodontal status distal to the M2.

Side-Effects of Interventions

IAN injury. Of the 123 included surgical candidates to undergo orthodontic M3s extraction, only 2 cases showed temporary paresthesia.^{31,36} Of the 20 patients who underwent total extraction, 5 developed

transient paresthesia.³² All cases of paresthesia resolved without any permanent symptoms.

Infection and swelling. No infection was reported in any of the studies. However, Wang et al³² mentioned various degrees of inflammation, which required intravenous antibiotics for at least 3 weeks in the orthodontic and total extraction groups.

Discussion

To the authors' knowledge, this is the first systematic review of the reported orthodontic approaches for extraction of impacted mandibular M3s and their outcomes. Thirteen articles were evaluated for their mechanical approach, safety, and other characteristics and complications, such as diagnostic methods, surgical procedure, M2 periodontal status, cyst-related M3 management, swelling and infection, treatment failure, and IAN injury.

In total, 143 cases were included in this review. Of these, 123 underwent orthodontic extraction and only 2 patients developed temporary paresthesia. However, the reason for the occurrence of paresthesia could be related to the surgical approach for tooth extraction. For instance, in the study of Celebi et al,³⁶ the orthodontic approach failed and the impacted M3 had to be removed surgically.

The orthodontic extraction procedure is comprised of 6 phases: 1) risk assessment, 2) establishment of the orthodontic anchorage, 3) surgical exposure of the impacted M3, 4) orthodontic extrusion of the M3, 5) clinical and radiographic evaluation of the level of extrusion, and 6) extraction of the M3.³⁰

The first and most important phase of orthodontic extraction is risk assessment. A panoramic radiograph was the primary diagnostic predictor in all the included studies. If the M3 is deemed to be in close proximity to the mandibular canal, then a CBCT or CT scan should be ordered for further evaluation. A single panoramic radiograph could be insufficient owing to image disturbance compared with a CT scan.⁴⁰ However, CBCT is the gold standard owing to lower radiation exposure and lower cost compared with CT.

Impacted M3s associated with a cyst can further complicate the surgical procedure. In this regard, 3 studies were included that focused on M3s associated with cysts.^{27,28,36} Marsupialization was performed during the first surgery. This procedure led to a gradual decrease in the size of the cyst during tooth extrusion. During the second surgery, the tooth was extracted and the cyst was enucleated. Follow-up ranged from 1 month to 2 years and showed complete resolution of the symptoms in the region of the previous M3 and cyst.

Different orthodontic mechanical therapies were carried out in these studies. It is imperative for an

orthodontist to be aware of the details of each procedure (discussed in the Results section) and be familiar with their strengths and limitations.

Unfortunately, owing to the difficulty of access during surgical exposure of horizontally and mesially inclined M3s, the point of attachment is usually the disto-occlusal aspect of the tooth, which is the least favorable considering the resultant orthodontic movement. To overcome this difficulty and decrease the probability of M3 impingement under the M2, the mesial cusp of the M3 was removed in some studies.^{32,34,35,37} One shortcoming of this procedure can be the increased risk of pulp exposure or necrosis of the M3, resulting in patient discomfort, infection, or inflammation.

In the cantilever archwire system, uncontrolled tipping is the most common orthodontic movement. However, these systems provide a more consistent direction of force application. The direction of force can be changed and controlled by modifying the length of the cantilever spring. Therefore, mesially inclined and horizontally impacted M3s can be extruded without odontoplasty, which is a drawback of the previous techniques. In this type of orthodontic movement, force is applied to the tooth in a more vertical direction, resulting in counterclockwise rotation of the M3 and bone forming distal to the M2.

In general, biomechanical systems used for orthodontic extraction in different articles can be categorized in 3 groups:

1. Orthodontic extrusion of lower M3s using the posterior maxillary region as the anchor.
2. Simple cantilever springs attached to the M3 buttonhole.
3. Cantilever springs tied to an orthodontic bracket on the M3 in addition to multiple-loop spring wire for distal movement of the M3.

In daily clinical practice, the first category is the simplest, but has the highest probability of M3 impaction under the M2 and extrusion of anchored upper posterior teeth. The second category requires bonding of the posterior mandibular region, but does not apply any uprighting moment of the couple on the M3 and the kind of rotation it creates depends on the point of attachment of the cantilever to the tooth, which is mostly the distobuccal aspect. Therefore, it can rotate M3s mesially, especially if the tooth is already mesially inclined. The third category can be particularly useful because a cantilever spring can simultaneously upright the M3 with a moment of couple and extrude it.

The decision to perform a retention phase after the tooth is sufficiently extruded is controversial. Impacted mandibular M3s can affect the periodontium of the

adjacent M2s, leading to increased PPD or CBL. As mentioned earlier, orthodontic traction of the M3 can improve bone apposition, thus improving PPD and CBL. Some studies used a retention phase^{27,29,33} and others did not. In these 2 conditions, the final outcome was favorable and considerable pocket depth improvement and bone apposition were observed. Therefore, clinical trials are needed to determine whether it is necessary to apply a retention phase for M2s that have compromised periodontal status.

Some surgeons have proposed using coronectomy to prevent IAN injury for mesioangular and vertically impacted mandibular M3s.^{12,13,17} This is an easy approach that avoids using any orthodontic appliances. A meta-analysis has suggested this method should be used instead of traditional total extraction of mandibular M3s to decrease the risk of nerve injury.¹⁴ This is a safe technique and, to the authors' knowledge, only 1 case of permanent IAN injury has been reported in the literature.⁴¹ However, this technique has its own limitations and, unlike the orthodontic-assisted M3 extraction, it does not affect the periodontal structures of the adjacent teeth. In fact, orthodontic traction can promote bone apposition and decrease periodontal defects by putting tension on the periodontal fibers.

Other disadvantages of coronectomy are the possible need for a subsequent surgery to remove the retained roots, delayed infection in the remaining roots, and a high rate of unsatisfactory healing.^{13,17,42} Furthermore, when the tooth is associated with a dentigerous cyst, coronectomy might not be possible.

As mentioned earlier, coronectomy is suitable for mesially and vertically impacted M3s. Coronectomy might not be suitable for horizontally or distally impacted teeth, and orthodontic appliances might be needed to extract teeth in these positions. However, Landi et al⁴³ extracted horizontally impacted M3s successfully by coronectomy. Coronectomy could be a practical solution for tooth ankylosis, where the orthodontic extraction technique is contraindicated.⁴² Orthodontic-assisted extraction has some disadvantages. It sometimes requires a second surgery similar to coronectomy, it is time consuming and expensive, and needs a cooperative patient. In addition, orthodontic appliances can result in patient discomfort. Because of the inherent complication and drawbacks of this technique, it should be reserved only for patients with obvious risks for intraoperative or postoperative complications. The risk assessment should be performed with careful radiographic and clinical examination and the patient should be compliant with the proposed treatment plan and maintenance therapy. Dentists should choose the best treatment plan, be it traditional total extraction, coronectomy, or orthodontic extraction, based on multiple factors,

such as risk of nerve injury, angulation of the M3, periodontal status of the adjacent M2, presence of a dentigerous cyst, tooth ankylosis, patient cooperation, patient's economic status, and consent. After the diagnosis of an impacted M3 with high risk of nerve injury is made, the authors recommend using the orthodontic extraction technique in the following situations:

1. For horizontally and distally impacted M3s or when it appears that a 1-stage coronectomy will not move the tooth far enough from the mandibular canal.
2. For impacted M3s associated with cysts.
3. When the postoperative osteo-periodontal status of the adjacent M2 is a concern.
4. When wide-sectioning of the M3 is needed and consequent pulp exposure and infection are probable. However, this is controversial because infection is not frequently reported after coronectomy.¹⁴

To summarize, each clinical case of tooth impaction must be considered separately and orthodontic extraction approach should be chosen only in carefully selected cases. Before treatment, it is important to discuss the risks and benefits of the available treatments thoroughly with patients to help them make the best possible decision.⁴⁴

This review shows the lack of good evidence in the current literature on this topic, with no prospective clinical trials in this area. Future randomized studies are needed to compare the outcomes of coronectomy, orthodontic extraction, and traditional total extraction of high-risk impacted mandibular M3s.

Despite the drawbacks of orthodontic extraction, the removal of deeply impacted mandibular M3s with a combined orthodontic and surgical approach minimizes the risk of IAN injury in patients at high risk of nerve damage. Orthodontic extraction also is recommended for impacted M3s that present a high risk of postoperative osteo-periodontal defects on the distal surface of the adjacent M2 and M3s associated with dentigerous cysts. However, owing to the lack of high-quality studies in this area, future high-quality clinical trials are needed.

References

1. Robinson PP, Loescher AR, Yates JM, et al: Current management of damage to the inferior alveolar and lingual nerves as a result of removal of third molars. *Br J Oral Maxillofac Surg* 42:285, 2004
2. Valmaseda-Castellón E, Berini-Aytés L, Gay-Escoda C: Inferior alveolar nerve damage after lower third molar surgical extraction: A prospective study of 1117 surgical extractions. *Oral Surg Oral Med Oral Pathol Oral Radiol Endod* 92:377, 2001
3. Kipp DP, Goldstein BH, Weiss W Jr: Dysesthesia after mandibular third molar surgery: A retrospective study and analysis of 1,377 surgical procedures. *J Am Dent Assoc* 100:185, 1980

4. Chiapasco M, De Cicco L, Marrone G: Side effects and complications associated with third molar surgery. *Oral Surg Oral Med Oral Pathol* 76:412, 1993
5. Bui CH, Seldin EB, Dodson TB: Types, frequencies, and risk factors for complications after third molar extraction. *J Oral Maxillofac Surg* 61:1379, 2003
6. Bataineh AB: Sensory nerve impairment following mandibular third molar surgery. *J Oral Maxillofac Surg* 59:1012, 2001
7. Queral-Godoy E, Valmaseda-Castellón E, Berini-Aytés L, et al: Incidence and evolution of inferior alveolar nerve lesions following lower third molar extraction. *Oral Surg Oral Med Oral Pathol Oral Radiol Endod* 99:259, 2005
8. Güllicher D, Gerlach K: Sensory impairment of the lingual and inferior alveolar nerves following removal of impacted mandibular third molars. *Int J Oral Maxillofac Surg* 30:306, 2001
9. Daley TD, Wysocki GP: The small dentigerous cyst: A diagnostic dilemma. *Oral Surg Oral Med Oral Pathol Oral Radiol Endod* 79:77, 1995
10. Chiapasco M, Rossi A, Motta JJ, et al: Spontaneous bone regeneration after enucleation of large mandibular cysts: A radiographic computed analysis of 27 consecutive cases. *J Oral Maxillofac Surg* 58:942, 2000
11. Enislidis G, Fock N, Sulzbacher I, et al: Conservative treatment of large cystic lesions of the mandible: A prospective study of the effect of decompression. *Br J Oral Maxillofac Surg* 42:546, 2004
12. Pogrel MA, Lee J, Muff D: Coronectomy: A technique to protect the inferior alveolar nerve. *J Oral Maxillofac Surg* 62:1447, 2004
13. Dolanmaz D, Yildirim G, Isik K, et al: A preferable technique for protecting the inferior alveolar nerve: Coronectomy. *J Oral Maxillofac Surg* 67:1234, 2009
14. Long H, Zhou Y, Liao L, et al: Coronectomy vs. total removal for third molar extraction: A systematic review. *J Dent Res* 91:659, 2012
15. Frafjord R, Renton T: A review of coronectomy. *Oral Surg* 3:1, 2010
16. Garcia-Garcia A: Coronectomy: A questionable procedure. *J Oral Maxillofac Surg* 63:723, 2005
17. Renton T, Hankins M, Sproate C, et al: A randomised controlled clinical trial to compare the incidence of injury to the inferior alveolar nerve as a result of coronectomy and removal of mandibular third molars. *Br J Oral Maxillofac Surg* 43:7, 2005
18. Hatano Y, Kurita K, Kuroiwa Y, et al: Clinical evaluations of coronectomy (intentional partial odontectomy) for mandibular third molars using dental computed tomography: A case-control study. *J Oral Maxillofac Surg* 67:1806, 2009
19. Oxford GE, Quintero G, Stuller CB, et al: Treatment of 3rd molar-induced periodontal defects with guided tissue regeneration. *J Clin Periodontol* 24:464, 1997
20. Karapatakis S, Hugoson A, Kugelberg CF: Healing following GTR treatment of bone defects distal to mandibular 2nd molars after surgical removal of impacted 3rd molars. *J Clin Periodontol* 27:325, 2000
21. Dodson TB: Management of mandibular third molar extraction sites to prevent periodontal defects. *J Oral Maxillofac Surg* 62:1213, 2004
22. Eslami A, Sadeghi E, Van Swol R: The prevalence of osseous defects on the distal aspect of the mandibular second molar in the absence of the third molar in a dental student population. *Quintessence Int* 16:363, 1985
23. Pecora G, Celletti R, Davarpanah M, et al: The effects of guided tissue regeneration on healing after impacted mandibular third-molar surgery: 1-Year results. *Int J Periodontics Restorative Dent* 13:397, 1993
24. Karapatakis S, Hugoson A, Falk H, et al: Healing following GTR treatment of intrabony defects distal to mandibular 2nd molars using resorbable and non-resorbable barriers. *J Clin Periodontol* 27:333, 2000
25. Checchi L, Alessandri BG, Pelliccioni G: Removing high-risk impacted mandibular third molars: A surgical-orthodontic approach. *J Am Dent Assoc* 127:1214, 1996
26. Ma Z-G, Xie Q-Y, Yang C, et al: An orthodontic technique for minimally invasive extraction of impacted lower third molar. *J Oral Maxillofac Surg* 71:1309, 2013
27. Montevicchi M, Checchi V, Bonetti GA: Management of a deeply impacted mandibular third molar and associated large dentigerous cyst to avoid nerve injury and improve periodontal healing: Case report. *J Can Dent Assoc* 78:59, 2012
28. Marchetti C, Bonetti DA, Pieri F, et al: Orthodontic extraction: Conservative treatment of impacted mandibular third molar associated with a dentigerous cyst. *Quintessence Int* 35:371, 2004
29. Montevicchi M, Parenti SI, Checchi V, et al: Periodontal healing after 'orthodontic extraction' of mandibular third molars: A retrospective cohort study. *Int J Oral Maxillofac Surg* 43:1137, 2014
30. Bonetti GA, Bendandi M, Laino L, et al: Orthodontic extraction: Riskless extraction of impacted lower third molars close to the mandibular canal. *J Oral Maxillofac Surg* 65:2580, 2007
31. Park W, Park JS, Kim YM, et al: Orthodontic extrusion of the lower third molar with an orthodontic mini implant. *Oral Surg Oral Med Oral Pathol Oral Radiol Endod* 110:e1, 2010
32. Wang Y, He D, Yang C, et al: An easy way to apply orthodontic extraction for impacted lower third molar compressing to the inferior alveolar nerve. *J Craniomaxillofac Surg* 40:234, 2012
33. Bonetti GA, Parenti SI, Checchi L: Orthodontic extraction of mandibular third molar to avoid nerve injury and promote periodontal healing. *J Clin Periodontol* 35:719, 2008
34. Hirsch A, Shteyman S, Boyan B, et al: Use of orthodontic treatment as an aid to third molar extraction: A method for prevention of mandibular nerve injury and improved periodontal status. *J Periodontol* 74:887, 2003
35. Guida L, Cuccurullo GP, Lanza A, et al: Orthodontic-aided extraction of impacted third molar to improve the periodontal status of the neighboring tooth. *J Craniofac Surg* 22:1922, 2011
36. Celebi N, Canakci GY, Sakin C, et al: Combined orthodontic and surgical therapy for a deeply impacted third molar related with a dentigerous cyst. *J Maxillofac Oral Surg* 14(suppl 1):93, 2015
37. Flanagan D: Forced extrusion for removal of impacted third molars close to the mandibular canal. *Rev Esp Cir Oral Maxillofac* 34:25, 2012
38. Yetkiner E, Mutlu E, Akar G: Orthodontic extraction of a mandibular third molar to avoid nerve injury: A case report. *J Orthod Res* 2:42, 2014
39. Rood JP, Shehab BA: The radiological prediction of inferior alveolar nerve injury during third molar surgery. *Br J Oral Maxillofac Surg* 28:20, 1990
40. Monaco G, Montevicchi M, Bonetti GA, et al: Reliability of panoramic radiography in evaluating the topographic relationship between the mandibular canal and impacted third molars. *J Am Dent Assoc* 135:312, 2004
41. O'Riordan BC: Coronectomy (intentional partial odontectomy of lower third molars). *Oral Surg Oral Med Oral Pathol Oral Radiol Endod* 98:274, 2004
42. Ramaraj PN: Orthodontic extraction: The riskless extraction of the impacted lower third molars close to the mandibular canal. *J Oral Maxillofac Surg* 66:1317, 2008
43. Landi L, Manicone PF, Piccinelli S, et al: A novel surgical approach to impacted mandibular third molars to reduce the risk of paresthesia: A case series. *J Oral Maxillofac Surg* 68:969, 2010
44. Kalantar Motamedi MR, Kalbassi S, Kalantar Motamedi A: Shared decision-making for restoration of missing tooth. *Scimetr* 3: e25239, 2015