

Immunopathology of Apical Periodontitis and Refractory Cases

Etsuko Matsuzaki*, Hisashi Anan*, Noriyoshi Matsumoto, Junko Hatakeyama, Masahiko Minakami and Toshio Izumi

Section of Operative Dentistry and Endodontology, Department of Odontology, Fukuoka Dental College, Fukuoka, Japan

Abstract

Apical periodontitis is a relatively frequently encountered disease in clinical dentistry; however, its pathogenesis and etiology are not easily elucidated. Therefore, it is not always cured, even when carefully following the highest standards of treatment and intractable apical periodontitis may occur. In addition, in long-term root canal treatment of difficult cases with intractable pain, there may be misunderstandings between the dentist and patient. While acute pain is an indispensable symptom in detecting lesions and disease, sustained chronic pain can decrease an individual's quality of life with various negative outcomes, including decreased motivation to work. Therefore, endodontic treatments and pain control measures for a diseased tooth in intractable apical periodontitis must be developed. This review outlines the progression from the onset of the lesion and examines the immunology of apical periodontitis based on studies of model animals, indicating that interleukin-1 β is a key factor in elucidating the disease state and is expected to lead to the development of an effective treatment for refractory cases.

Keywords: Apical periodontitis; Bone resorption; IL-1 β ; RANKL

Abbreviations: IL: Interleukin; RANKL: Receptor Activator of NF- κ B Ligand; TGF: Transforming Growth Factor; TNF: Tumor Necrosis Factor

Introduction

In clinical dentistry, apical periodontitis caused by bacterial infection of apical foramen is a frequently encountered disease. Acute inflammation can develop into chronic inflammation due to the attenuation of inflammatory stimulation via the root canal. In apical periodontitis, tissue destruction is caused by both the bacterial infection and the immune response, as a biological defense reaction to remove the pathogenic substances. Once the causative agent is removed by the immune reaction, restoration of the immune response is activated and tissue repair and healing can occur. Among various immune responses, cytokines such as interleukin (IL)-1 and tumor necrosis factor (TNF) have been shown to involve in acute apical periodontitis and bone destruction. This review describes the mechanism of apical periodontitis development, and the involvement of cytokine in exacerbating apical periodontitis based on immune response and bone destruction.

Mechanism of Apical Periodontitis Development

Apical periodontitis occurs due to bacterial infection of the apical foramen, which causes acute inflammation of the apical periodontal tissue. Neutrophil and macrophage infiltration is observed in periapical lesions during the acute phase. Acute inflammation can develop into chronic inflammation due to the attenuation of inflammatory stimulation via the root canal (Figure 1). Acute serous apical periodontitis can occur after operations to treat apical periodontitis (e.g. pulpectomies and root canal treatments). In successful root canal treatments with aseptic decoration and stimulus removal, inflammation disappears and the healing process begins. However, bacterial infections can occur on the outside of the apical foramen and lesions can progress to acute purulent apical periodontitis (Figure 2). Acute suppurative apical periodontitis can develop following the progression of suppurative pulpitis, gangrenous pulpitis, and dental pulp gangrene; this generally occurs via bacterial proliferation in the root canal. In addition, acute purulent apical periodontitis can occur after the activation of osteoclastic bone resorption and spread within the alveolar bone marrow as acute alveolitis and to the jawbone marrow. Although rare, this can develop into osteomyelitis of the jaw, which can lead to sepsis.

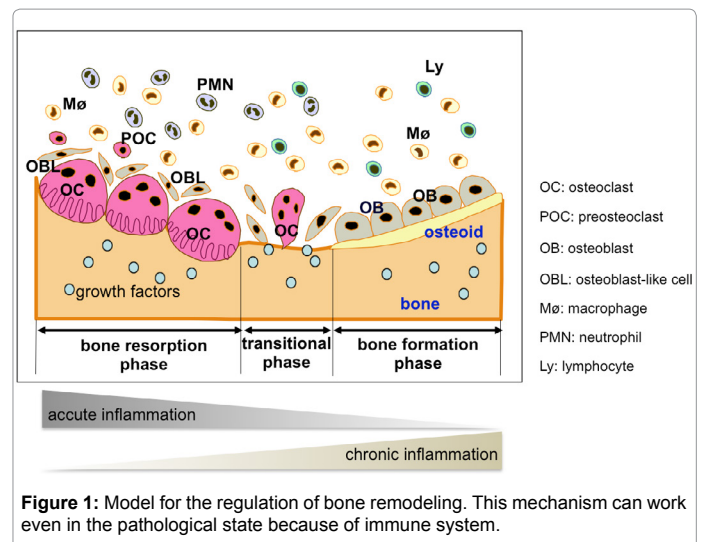


Figure 1: Model for the regulation of bone remodeling. This mechanism can work even in the pathological state because of immune system.

In many cases, the abscess destroys the relatively thin bone cortex on the buccal or lingual side. Abscesses form under the periosteum, causing the inflammation to expand further into the surrounding soft tissue, which can result in the formation of a fistula and a shift from acute apical periodontitis to chronic apical periodontitis.

In contrast, when the bacterial infection in the root canal weakens,

***Corresponding author:** Etsuko Matsuzaki Section of Operative Dentistry and Endodontology, Department of Odontology, Fukuoka Dental College, 2-15-1 Tamura, Sawara-ku, Fukuoka 814-0193, Japan, Tel: +81 92 801 0411; Fax: +81 92 871 9494; E-mail: matsuzaki@college.fdcnet.ac.jp

Hisashi Anan, Section of Operative Dentistry and Endodontology, Department of Odontology, Fukuoka Dental College, 2-15-1 Tamura, Sawara-ku, Fukuoka 814-0193, Japan, Tel: +81 92 801 0411; Fax: +81 92 871 9494; E-mail: hanan@college.fdcnet.ac.jp

Received October 14, 2016; **Accepted** November 10, 2016; **Published** November 17, 2016

Citation: Matsuzaki E, Anan H, Matsumoto N, Hatakeyama J, Minakami M, et al. (2016) Immunopathology of Apical Periodontitis and Refractory Cases. J Tissue Sci Eng 7: 184. doi:10.4172/2157-7552.1000184

Copyright: © 2016 Matsuzaki E, et al. This is an open-access article distributed under the terms of the Creative Commons Attribution License, which permits unrestricted use, distribution, and reproduction in any medium, provided the original author and source are credited.

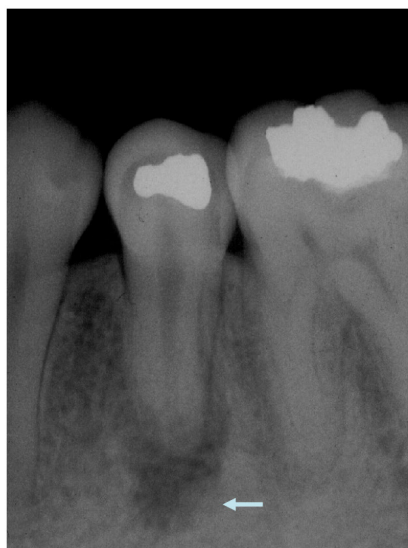

Figure 2: Chronicity of acute apical periodontitis. Arrowhead indicates the abscess.

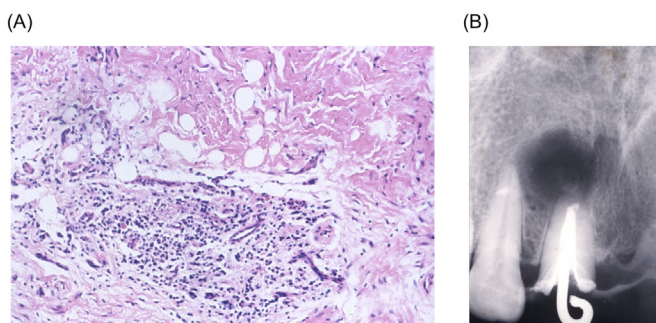


Figure 3: Histological finding (A) and X-ray (B) of periapical granuloma. (A) Development of granulation tissue is observed. (B) Clear radiolucency is observed.

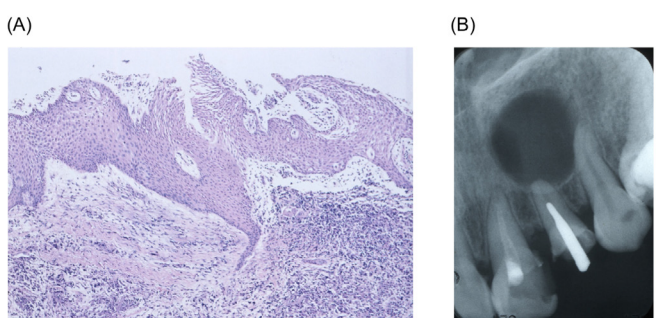


Figure 4: Histological finding (A) and X-ray (B) of radicular cyst. (A) As a result of proliferation of the epithelial rests of Malassez within the lesions, the epithelial layer is observed. (B) Densification of bone is observed in the vicinity of the lesion.

the lesion shifts from the active phase to the repair phase. Granulation tissue grows in the abscess, gradually absorbing the abscess and shifting into granulomatous inflammation. At this stage, it is considered to be a periapical granuloma and many macrophages and lymphocytes can be observed in the lesion (Figure 3). In chronic periapical abscesses

or periapical granulomas, epithelial rests of Malassez often proliferate within the lesions (Figure 4) and can occur as cysts [1].

In apical periodontitis, tissue destruction is caused by both the bacterial infection and the immune response, as a biological defense reaction to remove the pathogenic substances. If the causative agent is removed by the immune reaction, restoration of the immune response is activated and tissue repair and healing can occur (Figure 5).

Since it is difficult to directly sample lesions to study apical periodontitis in humans, animal models are often used. Figure 6 shows a time course of the inflammatory response in apical periodontal tissue based on a histological investigation in rats with experimentally induced apical periodontitis. An acute inflammatory reaction was observed in the lesions, composed mainly of neutrophils. The reaction peaked on day 14, after which a chronic inflammatory reaction was observed in the lesions, composed mainly of lymphocytes and plasma cells. Bone resorption increased biphasically on days 2 and 14. The first

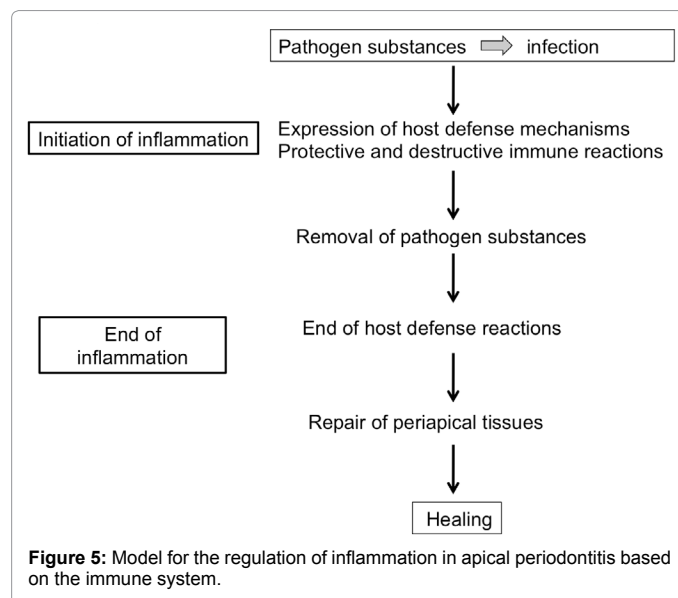


Figure 5: Model for the regulation of inflammation in apical periodontitis based on the immune system.

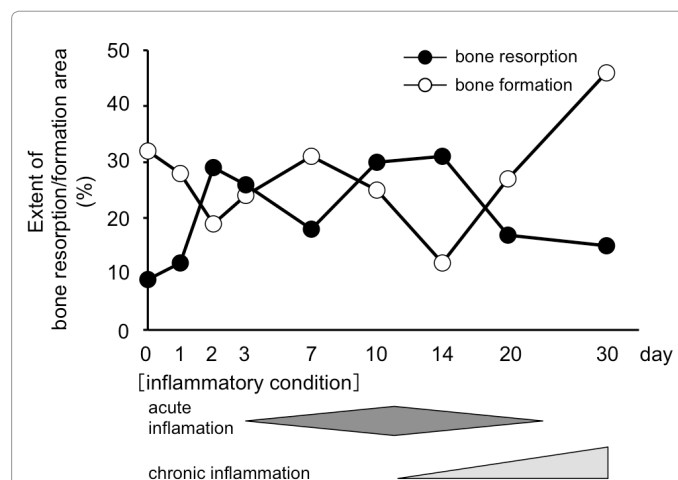


Figure 6: A time course of the inflammatory response in apical periodontal tissue in rat experimental apical periodontitis. Extent of bone resorption (black circle), or bone formation (open circle) for the indicated times is determined and calculated as the percentages of total bone surface.

bone resorption peak on day 2 was likely due to mechanical stimuli applied to the dental pulp and apical portion during the induction of apical periodontitis. The second peak on day 14 was likely related to the acute inflammatory response [2]. After the strong acute inflammatory response subsided, active bone formation and fibrous bone tissue formation increased when the majority of pathogenic substances and necrotic tissues were removed.

Cytokine Involvement in the Immune Response during Acute Apical Periodontitis

Although various immune responses can occur, the proliferation and differentiation of individual cells progress via direct contact between cells. In this case, cytokines act as information transfer factors between cells, and a number of cytokines have been reported to be involved in various immune reactions (Table 1). Aside from their role in immunoreactivity, it has been suggested that these cytokines are closely related to bone metabolism [3-5]. In addition, cytokines produced at sites of inflammation may be involved in the pathogenesis of direct or indirect apical periodontitis.

Among these numerous cytokines, IL-1 and TNF are thought to be powerful osteoclast-activating factors; thus, they have attracted increasing academic attention. In a clinical endodontic report, high IL-1-like activity was detected in the root canal exudate of a patient with apical periodontitis and clinical symptoms. IL-6 acts as an osteoclast-activating factor, as well as a growth factor for B lymphocytes, promoting antibody production. Furthermore, it affects the differentiation and activation of T lymphocytes. IL-8 is a chemokine responsible for the migration and activation of neutrophils, T lymphocytes, and basophils. These inflammatory cytokines increase the production of prostaglandins and proteases at inflammatory sites, enhances inflammatory reactions and induce the destruction of apical periodontal tissue.

Cytokines are signaling molecules that mediate and regulate immunity, inflammation, hematopoiesis, and many other cellular processes via cytokine networks [6]. Moreover, they are believed to be deeply involved in the onset and exacerbation of apical periodontitis (Figure 7).

Factors Exacerbating Apical Periodontitis

A number of recent reports have suggested the involvement of biofilms formed by various bacteria on the apical foramen inside and outside the apex in prolonged inflammation [7]. It has been suggested that pulp deactivators, including arsenite and paraformaldehyde, as well as intracanal disinfectants, including phenol and formocresol, induce fairly strong irritation. When these irritants are used incorrectly, they leak into the periapical tissue and cause severe inflammation, inducing symptoms of acute apical periodontitis. Application of the excessive

formocresol in root canal triggers the expansion of apical lesion, leading to the activation of osteoclasts and macrophages expressing IL-1 β in the vicinity of bone, resulting in bone resorption (Figure 8).

Although formocresol is a powerful disinfectant, it can cause tissue damage. Apical periodontitis induced by pharmacological factors exhibits severe inflammation, and clinical symptoms are more persistent than those caused by mechanical stimulation. The effects of formocresol applied directly to the open apex are thought to be related to severe destruction of periapical lesions, resulting in markedly higher infiltration by inflammatory cells. This induces IL-1 β overproduction by macrophages, exacerbating the periapical lesion and leading to apical periodontitis. A recent report suggested that IL-1 β has a central role in tissue destruction in apical periodontitis [8]. In bacterial infections, IL-1 β production is

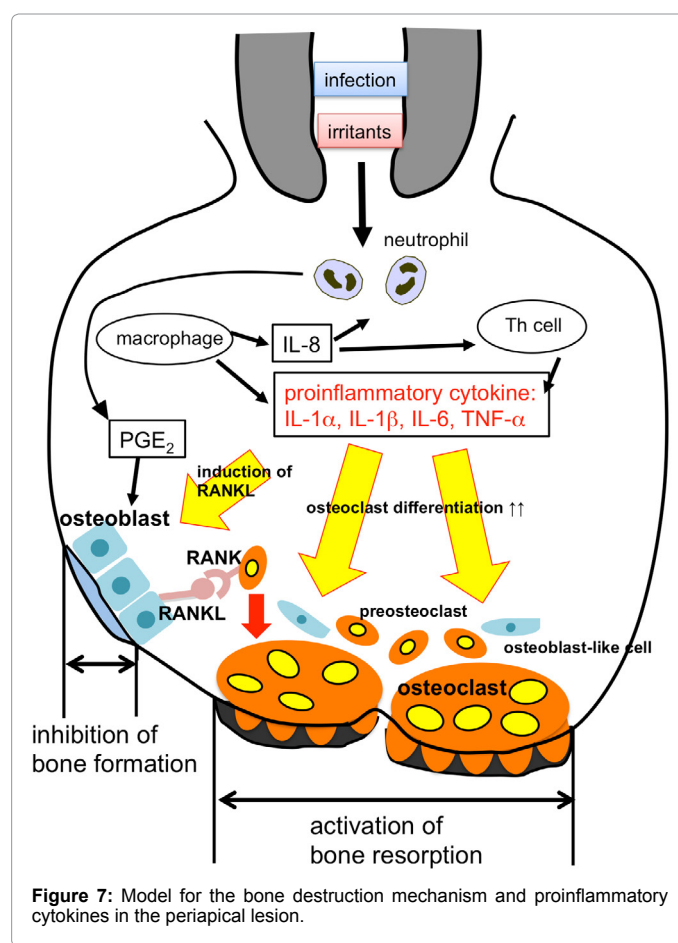


Figure 7: Model for the bone destruction mechanism and proinflammatory cytokines in the periapical lesion.

Cytokine	Cytokine-producing cell	Target cell	Main function	Effects on bone
IL-1 α /IL-1 β	monocyte, dendritic cell, B cell, fibroblast, epithelial cell, endothelial cell, macrophage	thymus lymphocytes, T cell, B cell, neutrophil, tissue cell, osteoblast	immune regulation, inflammation	Bone destruction
IL-6	macrophage, T cell, monocyte, fibroblast, B cell	T cell, B cell, thymus lymphocytes, tissue cell, osteoblast	cell differentiation, protein synthesis of acute phase	Bone destruction
IL-8	macrophage	neutrophils, basophils	chemotactic factor	
IL-10	T cell	Th1 cell	inhibition of cytokine synthesis	
IL-17	T cell	T cell, macrophage, fibroblast, endothelial cell	inflammation, neutrophil migration	Bone destruction
IFN- γ	T cell, NK cell	lymphocytes, monocytes, tissue cells	immune regulation, B cell differentiation, MHC I expression	
TNF- α	macrophage, lymphocyte, mast cell	macrophage, granulocyte, endothelial cell	inflammation, fibrosis	Bone destruction

Table 1: Involvement of cytokines in the immune response and bone destruction.

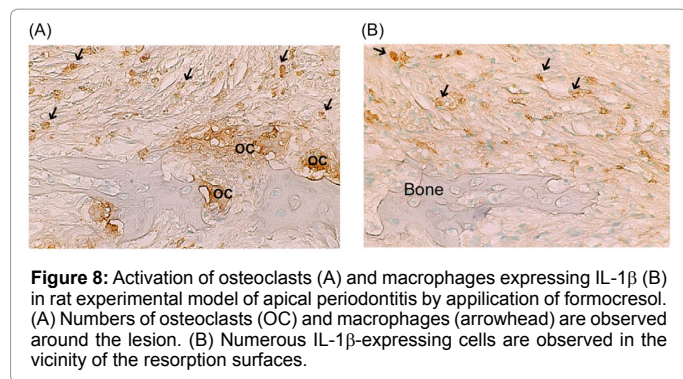


Figure 8: Activation of osteoclasts (A) and macrophages expressing IL-1 β (B) in rat experimental model of apical periodontitis by application of formocresol. (A) Numbers of osteoclasts (OC) and macrophages (arrowhead) are observed around the lesion. (B) Numerous IL-1 β -expressing cells are observed in the vicinity of the resorption surfaces.

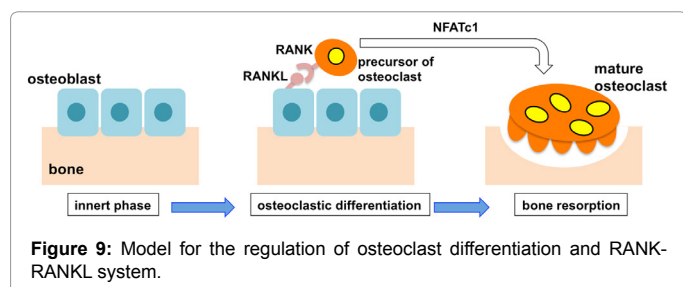


Figure 9: Model for the regulation of osteoclast differentiation and RANK-RANKL system.

essential to the biological defense system; however, overexpression of IL-1 β interferes with normal healing and leads to intractable inflammation.

Cellular Mechanisms of Bone Destruction in Apical Periodontitis: Involvement of TNFS and Osteoclasts

In periapical regions, the bone remodeling mechanism is maintained by a delicate balance of bone resorption and formation. Failure of this balance due to the production of cytokines associated with prolonged inflammation impedes apical periodontitis healing, allowing it to become intractable. Particularly, pro-inflammatory cytokines such as IL-1 β and TNF α are osteoclast-activating factors. They recently discovered involvement with skeletal system cells, including osteoclasts, as well as their role in the immune system has led to the proposal of osteoimmunology as a new branch of science studying bone immunology [9]. In periodontitis, osteoclasts aid in the resorption of alveolar bone. Receptor activator of NF- κ B ligand (RANKL) is essential for inducing osteoclastogenesis. Osteoblasts and bone marrow stromal cells produce RANKL, and its signal is transduced by its specific receptor, RANK, which is expressed on the cell surface of osteoclast progenitors. IL-1 β produced by macrophages affects osteoclastogenesis indirectly by altering osteoblast RANKL expression; it also influences osteoclast maturation directly.

Takayanagi et al. observed that synovial fibroblasts and T cells expressed RANKL on their cell membranes and that T cells directly released soluble RANKL and activated osteoclast formation [10,11]. This suggests that inflammatory cells are important in bone remodeling during apical periodontitis. Activation of IL-1 receptors and RANK in osteoclast precursor cells induces nuclear factor of activated T cells, cytoplasmic 1 [5], which is a master transcription factor that promotes osteoclast differentiation (Figure 9).

TNF α is in the same family as RANKL and acts directly on osteoclast progenitor cells by inducing RANKL expression in osteoblasts to promote the differentiation of osteoclasts. TNF α inhibits

bone formation by inducing the expression of Dickkopf1 and sclerostin, which inhibits Wnt signaling during osteoblast differentiation. IL-1 signaling also promotes RANKL-RANK signaling.

The Role of Macrophages

Macrophages produce both bone resorption cytokines and osteoblast growth factors such as transforming growth factor (TGF)- β [12]. TGF- β primarily inhibits T cell proliferation and blocks the effects of pro-inflammatory cytokines. It has been suggested that macrophages are not only related to enhancing tissue destruction in apical periodontitis, but also to the suppression of tissue destruction and the activation of healing mechanisms [13].

Intractable Disease Control

Anti-cytokine therapies that attempt to reduce inflammatory cytokine activity by controlling their production have attracted attention for their potential in treating intractable diseases [14]. Recent animal and human studies have shown that blocking IL-1 activity may be therapeutically beneficial. For example, IL-1RA or soluble type IL-1R treatment reduces the severity of endotoxin-induced sepsis and impedes the progression of arthritis in experimental models [15]. Additionally, IL-1 β -converting enzyme inhibitor blocks the progression of type II collagen-induced arthritis in mice [16]. In an attempt to find an effective novel cure for periapical lesions that have difficulty in subsiding due to severe inflammation, healing mechanisms could be activated by suppressing IL-1 β production and secretion using a combination of antibacterial agents and IL-1 β inhibitors. However, the mechanisms underlying the pathogenesis and progression of periapical lesions remain unclear; additional research is necessary to define the roles of immunological elements such as inflammatory cytokines like IL-1 β in order to develop more effective treatments for refractory periapical lesions.

Conclusion

IL-1 β is closely involved in the repression of intractable apical periodontitis and the bone destruction mechanism of inflammation regulation. Investigating a variety of inflammatory regulators, including inflammatory and anti-inflammatory cytokines that are likely involved in tissue destruction in apical periodontitis, will be necessary to develop novel endodontic treatments for intractable apical periodontitis. This is a key factor in elucidating the disease state and is expected to lead to the development of an effective treatment for refractory cases.

References

- Nair PNR (2011) Pathobiology of primary apical periodontitis. (10thedn), Cohen's Pathways of the Pulp, St. Louis, Mosby.
- Anan H, Akamine A, Hara Y, Maeda K, Hashiguchi I, et al. (1991) A histochemical study of bone remodeling during experimental apical periodontitis in rats. *J Endod* 17: 332-337.
- Matsumoto A, Anan H, Maeda K (1998) An immunohistochemical study of the behavior of cells expressing interleukin-1 α and interleukin-1 β within experimentally induced periapical lesions in rats. *J Endod* 24: 811-816.
- Martinez ZR, Naruishi K, Yamashiro K, Myokai F, Yamada T, et al. (2007) Gene profiles during root canal treatment in experimental rat periapical lesions. *J Endod* 33: 936-943.
- Zupan J, Jeras M, Marc J (2013) Osteoimmunology and the influence of pro-inflammatory cytokines on osteoclasts. *Biochemia Medica* 23: 43-63.
- Stashenko P (1990) The role of immune cytokines in the pathogenesis of periapical lesions. *Endod Dent Traumatol* 6: 89-96.
- Leonardo MR, Rossi MA, Silva LA, Ito MA, Bonifácio KC (2002) EM evaluation of bacterial biofilm and microorganisms on the apical external root surface of human teeth. *J Endod* 28: 815-818.

8. Marton IJ and Kiss C (2014) Overlapping protective and destructive regulatory pathways in apical periodontitis. *J Endod* 40: 155-163.
9. Aron JR, Choi Y (2000) Bone versus immune system. *Nature* 408: 535-536.
10. Takayanagi H, Ogasawara K, Hida S, Chiba T, Murata S, et al. (2000) T-cell-mediated regulation of osteoclastogenesis by signalling cross-talk between RANKL and IFN-gamma. *Nature* 408: 600-605.
11. Takayanagi H (2005) Inflammatory bone destruction and osteoimmunology. *Journal of Periodontal Research* 40: 287-293.
12. Kaneko T, Yamanaka Y, Shigetani Y, Yoshida K, Okiji T (2014) M2 macrophages participate in the biological tissue healing reaction to mineral trioxide aggregate. *J Endod* 40: 379-383.
13. Tang Y, Wu X, Lei W, Pang L, Wan C, et al. (2009) TGF-beta1-induced migration of bone mesenchymal stem cells couples bone resorption with formation. *Nat Med* 15: 757-765.
14. van Vollenhoven RF, Fleischmann R, Cohen S, Lee EB, Garcia Mejjide JA, et al. (2012) Tofacitinib or adalimumab versus placebo in rheumatoid arthritis. *N Engl J Med* 367: 508-519.
15. Alexander HR, Doherty GM, Buresh CM, Venzon DJ, Norton JA (1991) A recombinant human receptor antagonist for interleukin-1 improves survival after lethal endotoxemia in mice. *J Exp Med* 173: 1029-1032.
16. Ku G, Faust T, Lauffer LL, Livingston DJ, Harding MW (1996) Interleukin-1b converting enzyme inhibition blocks progression of type II collagen-induced arthritis in mice. *Cytokine* 8: 377-386.