

Complex and compound odontomas: Analysis of 69 cases and a rare case of erupted compound odontoma

C Bereket, N Çakır-Özkan, İ Şener, E Bulut, M Tek¹

Department of Oral and Maxillofacial Surgery, Faculty of Dentistry, Ondokuz Mayıs University, Samsun, ¹Department of Oral and Maxillofacial Surgery, Faculty of Dentistry, Abant İzzet Baysal University, Bolu, Turkey

Abstract

Objective: The purpose of this study was to analyze clinic and radiologic features of the 69 odontoma cases and present a rare case of erupted compound odontoma in the oral cavity.

Material and Methods: The 69 cases were analyzed with regard to the following parameters: age, gender, location, associated unerupted teeth, missing teeth, radiological and histopathological features and treatment protocols.

Results: Of the 69 cases, 49 were compound odontoma and 20 were complex odontoma. There was a female predilection for both compound and complex odontomas. Compound odontoma occurred more often in the anterior region of the jaws; complex lesions occurred more often at the posterior mandible. The most common clinical manifestations were the retention of permanent teeth.

Conclusion: Compound odontomas rarely erupt into the mouth. The presented case is the 13th case of erupted compound odontoma reported in the literature. The treatment of choice is surgical removal of the odontoma. In the case of odontomas associated to impacted teeth, the teeth should be preserved in wait of spontaneous eruption, or alternatively fenestration followed by orthodontic traction is indicated. Regular follow-up period is crucial to evaluate the prognosis of these teeth.

Key words: Complex odontoma, compound odontoma, delayed eruption, impacted tooth, odontogenic tumor, radiopaque lesion

Date of Acceptance: 26-Feb-2015

Introduction

Odontomas are odontogenic tumors, which are considered developmental malformations of dental tissues. These tumors are formed from enamel and dentin, and can have variable amounts of cement and pulp tissues. According to radiographic, microscopic, and clinical features, two types of odontomas are recognized: Complex and compound odontomas. A compound odontoma forms a conglomeration of small structures resembling teeth, whereas a complex odontoma forms an irregular mass in a disorderly pattern.^[1-3] The etiology of odontomas remains unknown, although local trauma, infection, and genetic factors have been suggested.

Their growth is typically slow and asymptomatic. Therefore, odontomas are generally diagnosed by routine radiological examination in the second and third decades of the life.^[4-6]

Most of the odontomas are found in the areas of the upper incisors and canines, followed by the antero- and postero-inferior regions. Complex odontomas are more often found in the area of the second and third lower molars. These lesions tend to be located between the roots of erupted teeth, or between the deciduous and permanent dentition.^[7-10]

Address for correspondence:

Dr. Cihan Bereket,
Department of Oral and Maxillofacial Surgery, Faculty of Dentistry,
Ondokuz Mayıs University, Samsun, Turkey.
E-mail: cihanbereket@hotmail.com

Access this article online

Quick Response Code:



Website: www.njcponline.com

DOI: 10.4103/1119-3077.154209

Radiologically, odontomas present as a well-defined radiopacity situated in bone surrounded by a radiolucent halo, typically encompassed by a thin sclerotic line. The developmental stages can be identified based on radiological features and the degree of calcification of the lesion. The first stage is characterized by radiolucency; the second stage shows partial calcification, and the third stage exhibits predominant tissue calcifications with the surrounding radiolucent halo. Compound odontomas show an irregular radiopaque image composed of multiple radiopacities, which correspond to the so-called denticles. In the complex lesion, radiopacity is not specific; disorganized, irregular, single or multiple mass is identified.^[11-13]

Erupted odontomas, especially compound type were rarely seen in the clinical practice. The present study reports our experience with 69 odontomas and a rare case of erupted compound odontoma. To date, 12 cases of erupted compound odontomas are reported in the literature; the last case was reported by Hanemann *et al.* and to our knowledge our case is the 13th compound odontoma.

Material and Methods

We retrospectively analyzed 69 cases diagnosed as odontomas in the Department of Oral and Maxillofacial Surgery (from 2000 to 2011), the Dental Faculty of Ondokuzmayis University. The subjects were 24 men and 45 women, ranging in age from 8 to 70 years (mean 25.86 ± 14.3). The 69 cases were analyzed according to the following parameters: Age, gender, location, associated impacted teeth, radiologic, and histopathologic features and treatment protocols. The morphologic criteria for subclassification of the odontomas into complex and compound types are those listed by the World Health Organization in 1992.

The 69 cases were diagnosed based on clinical history, physical examination, radiological examination (panoramic, occlusal, periapical X-ray and computed tomography), and histopathological analysis of the surgical specimen.

The Chi-square test was performed to determine the statistical significance of differences in prevalence of findings between the sexes, between upper and lower jaws, between the right and left sides of the patient, as well as the type of odontoma and complications. Differences with $P < 0.05$ were considered statistically significant.

Results

Histopathologically, 20 (28.9%) complex odontomas and 49 (71%) compound odontomas were found. 35 (50.7%) cases were in the maxilla, and 34 (49.3%) cases were in the mandible [Table 1].

The average age of complex odontoma diagnosis was 32.5 years. The sex distribution was 12 (60%) females and

Table 1: The clinical features of the odontoma cases

	Complex n = 20 (%)	Compound n = 49 (%)
The mean age of the patient	32.5	23.1
Male/female ratio	8/12	16/33
Lower jaw	11 (55)	23 (46.9)
Upper jaw	9 (45)	26 (53.1)
Odontomas associated with unerupted teeth	10 (50)	34 (69.4)

8 (40%) males. There were 11 (55%) complex odontomas located in the mandible and 9 (45%) cases in the maxilla. Complex odontomas associated with unerupted teeth were detected in 10 (50%) cases. Most of the cases 9 (45%) were located in the area of lower second or third molars. There were no cases associated with missing teeth.

Radiographically, in the complex lesions, radiopacity was not specific and disorganized, irregular, single or multiple masses were observed.

The average age of compound odontoma diagnosis was 23.1 years. The sex distribution was 33 (67.3%) females and 16 (32.7%) males. There were 23 (46.9%) compound odontomas located in the mandible and 26 (53.1%) cases in the maxilla. Compound odontomas associated with unerupted teeth were detected in 34 (69.4%) cases. Most of the cases 33 (67.3%) were located in the anterior region.

Radiographically, compound odontomas demonstrated an irregular radiopaque image composed of multiple radiopacities, surrounded by a narrow radiolucent halo. Histologically, compound lesions were composed of many small denticles with a greater degree of morphologic differentiation.

All of the 69 odontomas were surgically removed. In three patients, associated unerupted teeth were orthodontically treated. In the remaining cases, associated unerupted teeth were surgically extracted due to poor prognosis. There was no statistically significant difference between the sexes, between upper and lower jaws, and between the right and left sides of the patient, the type of odontomas and complications.

Case of erupted compound odontoma

A 19-year-old man was referred to our clinic by his dentist for evaluation of a radiopaque lesion in anterior maxillary region of the second quadrant that caused impaction of the left canine tooth. There was a history of swelling in the left anterior maxillary region for 4 years in his anamnesis, and he received orthodontic treatment 3 years ago. His medical history was unremarkable.

Intraoral examination revealed a white colored tooth-like structure erupting into the oral cavity. It was located in

the left maxillary canine region. It was approximately 0.1 cm × 0.1 cm in diameter, showing a smooth surface. Surrounding mucosa was normal, and there were no signs of pain, infection, erythema or ulceration [Figure 1]. The panoramic and periapical radiographs showed

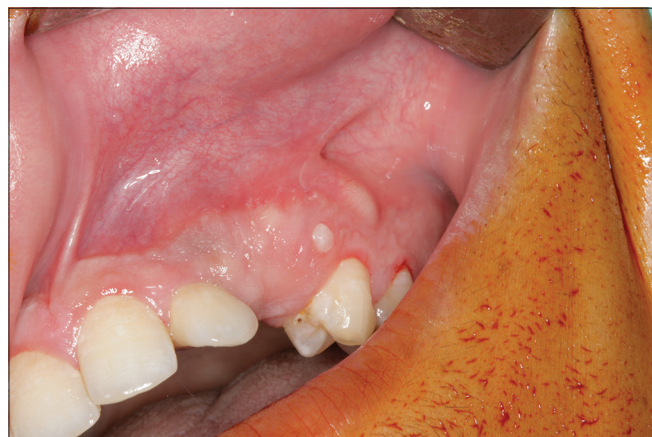

Figure 1: Intraoral view showing the eruption of compound odontoma

impaction of the upper left canine tooth and multiple small tooth-like radiopaque structures in this same quadrant [Figure 2]. The treatment consisted of surgical removal of the lesion, followed by histopathological study, which confirmed the diagnosis of compound odontoma [Figures 3-5]. Orthodontic treatment offered to the patient, but he refused treatment because of military service. The canine teeth erupted without the need for orthodontic traction at 6 months postoperative follow-up period [Figure 6].

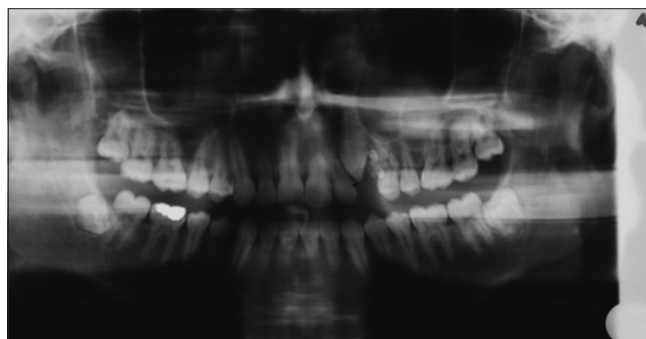


Figure 2: Panoramic radiograph showing impacted canine tooth and compound odontoma

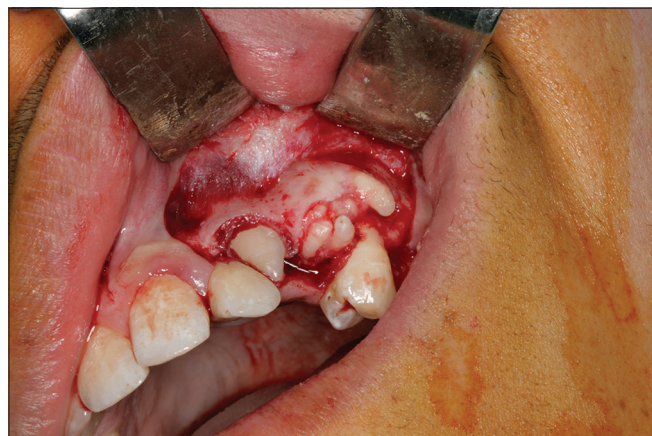

Figure 3: Intraoral view showing multiple small tooth-like structures

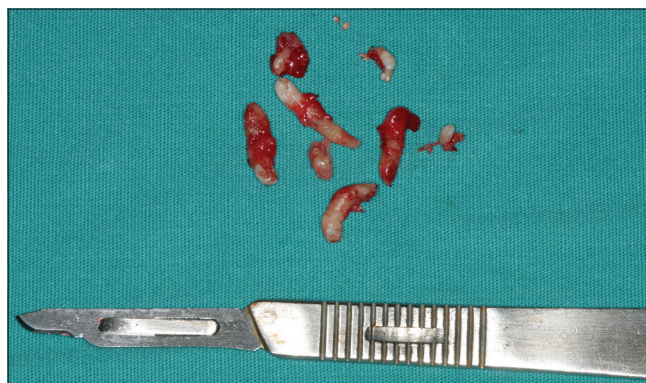

Figure 4: Excised multiple small tooth-like structures

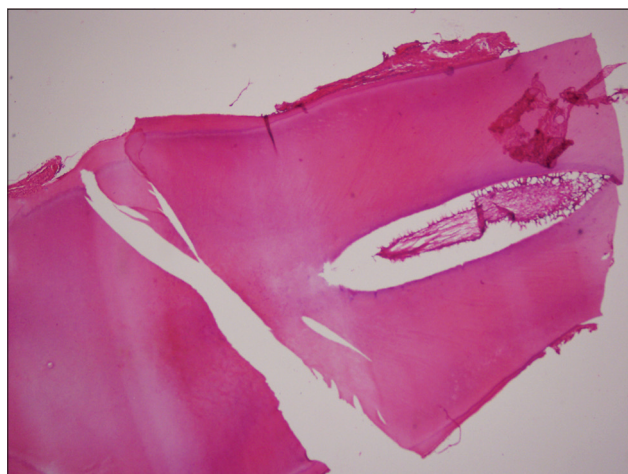


Figure 5: Photomicrograph showing decalcified dentin, sementum and pulp (H and E, ×40)

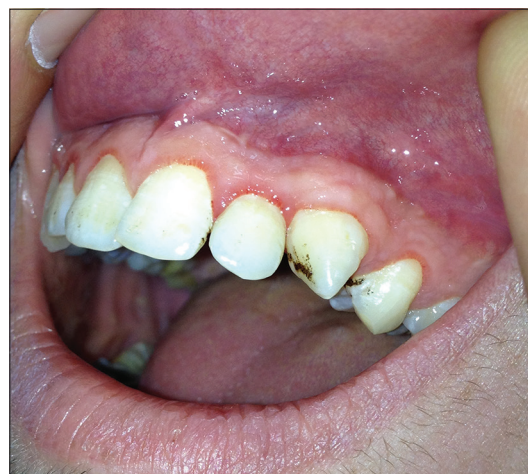

Figure 6: Intraoral photograph showing eruption of odontoma associated impacted canine tooth

Discussion

Odontomas are benign tumors that are frequently seen in oral pathology, and they are usually asymptomatic. A number of studies have examined a large series of odontomas, and they have been identified as the most frequent odontogenic tumors.^[13-15]

There is no consensus among authors regarding gender predilection. The male/female ratio of complex odontomas varies from 1:0.8 to 1.6:1, and the ratio of compound odontomas varies from 1.2:1 to 1:1.^[16] Although some differences exist in the literature, there is a general agreement on equal sex incidence.^[17] In the present study, the female predilection was observed for both compound (2:1) and complex (1.5:1) odontomas.

Regarding patient age at the time of diagnosis, these lesions can be diagnosed at any age. The majority of authors report a peak incidence in the second decade of life consistent with our results.^[17,18] Some studies have reported a correlation between patient age and the type of odontoma. It has been reported that compound odontomas are diagnosed at an earlier age than complex odontomas.^[4,17,19] With regard to the relation between patient age and tumor type, our results are in line with the literature.^[14,17] In our study, compound odontomas were diagnosed at an earlier age than complex lesions.

In relation to tumor location, the majority of the compound odontomas are found in the anterior maxilla while the most common location of complex odontomas is the posterior mandible followed by the anterior maxilla.^[20,21] In the present study, the location of both the complex and compound odontomas exhibited a similar pattern.

The complex form of odontomas is less common than the compound type and is more often associated with unerupted teeth. The results of our study are consistent with previous research, and we observed a clear predominance of compound lesions over complex odontomas, 2.5:1.^[13,20] However, contrary to some reports, we found that compound odontomas are associated with the unerupted teeth more often than complex lesions.

Odontomas are generally asymptomatic. However, they can, at times, cause signs and symptoms (e.g. delayed eruption or impaction, pain, infection) that lead to the conduction of X-ray examinations, which, in turn, reveal the presence of an odontoma.^[4] In such cases, in line with our results, the upper incisors and canines are the most commonly affected teeth. The treatment of choice is generally surgical removal to prevent associated complications. Clinical and radiographic follow-up should be performed when surgical treatment is deferred.^[21,22]

If no signs or symptoms appear, they can remain within the bone for many years without producing clinical manifestations. Rarely, there are some manifestations, such as cyst formation as a dentigerous cyst and a calcifying epithelial odontogenic cyst.^[23,24]

The eruption of odontomas is rare and in the literature of the 21 reported cases of odontoma, nine were compound odontomas and 12 were complex odontomas.^[25,26] Finally, Hanemann *et al.*^[27] reported the 12th case of erupted compound odontoma. The presented case is the 13th case of erupted compound odontoma reported in the English literature. Erupted odontomas are generally seen in older people. It is likely that resorption of the edentulous part of the alveolar process plays a role, or reactive growth of the capsule may lead to this situation.^[5] In younger age, eruption may be occur because of bone remodeling that might have resulted from the presence of dental follicles.

Although odontomas are usually asymptomatic, their eruption into the oral cavity can give rise to pain or inflammation.^[22] Our case was asymptomatic, but it was associated with impacted canine tooth. There is no general agreement on the best management approach for impacted teeth associated with odontomas. The treatment choices are surgical extraction, fenestration, orthodontic traction or regular clinical and radiological follow-up.^[11,25] In our case, impacted canine tooth spontaneously erupted into the oral cavity without orthodontic traction.

Conclusion

Compound odontomas rarely erupt into the mouth and tend to be associated to impacted teeth. The treatment of choice is surgical removal of the odontoma, followed by histological analysis. In the case of odontomas associated to impacted teeth, the teeth should be preserved in wait of spontaneous eruption, or alternatively fenestration followed by orthodontic traction is indicated. Regular follow-up period is crucial to evaluate the prognosis of these teeth.

References

1. Junquera L, de Vicente JC, Roig P, Olay S, Rodríguez-Recio O. Intraosseous odontoma erupted into the oral cavity: An unusual pathology. *Med Oral Patol Oral Cir Bucal* 2005;10:248-51.
2. Katz RW. An analysis of compound and complex odontomas. *ASDC J Dent Child* 1989;56:445-9.
3. Bordini J Jr, Contar CM, Sarot JR, Fernandes A, Machado MA. Multiple compound odontomas in the jaw: Case report and analysis of the literature. *J Oral Maxillofac Surg* 2008;66:2617-20.
4. Amado Cuesta S, Gargallo Albiol J, Berini Aytés L, Gay Escoda C. Review of 61 cases of odontoma. Presentation of an erupted complex odontoma. *Med Oral* 2003;8:366-73.
5. Ragalli CC, Ferreria JL, Blasco F. Large erupting complex odontoma. *Int J Oral Maxillofac Surg* 2000;29:373-4.
6. Kaneko M, Fukuda M, Sano T, Ohnishi T, Hosokawa Y. Microradiographic and microscopic investigation of a rare case of complex odontoma. *Oral Surg Oral Med Oral Pathol Oral Radiol Endod* 1998;86:131-4.

7. Owens BM, Schuman NJ, Mincer HH, Turner JE, Oliver FM. Dental odontomas: A retrospective study of 104 cases. *J Clin Pediatr Dent* 1997;21:261-4.
8. Iwamoto O, Harada H, Kusakawa J, Kameyama T. Multiple odontomas of the mandible: A case report. *J Oral Maxillofac Surg* 1999;57:338-41.
9. Miki Y, Oda Y, Iwaya N, Hirota M, Yamada N, Aisaki K, *et al.* Clinicopathological studies of odontoma in 47 patients. *J Oral Sci* 1999;41:173-6.
10. Yildirim-Oz G, Tosun G, Kiziloglu D, Durmus E, Sener Y. An unusual association of odontomas with primary teeth. *Eur J Dent* 2007;1:45-9.
11. Liu JK, Hsiao CK, Chen HA, Tsai MY. Orthodontic correction of a mandibular first molar deeply impacted by an odontoma: A case report. *Quintessence Int* 1997;28:381-5.
12. Slootweg PJ. An analysis of the interrelationship of the mixed odontogenic tumors – ameloblastic fibroma, ameloblastic fibro-odontoma, and the odontomas. *Oral Surg Oral Med Oral Pathol* 1981;51:266-76.
13. Buchner A, Merrell PW, Carpenter WM. Relative frequency of central odontogenic tumors: A study of 1,088 cases from Northern California and comparison to studies from other parts of the world. *J Oral Maxillofac Surg* 2006;64:1343-52.
14. Ochsenius G, Ortega A, Godoy L, Peñafiel C, Escobar E. Odontogenic tumors in Chile: A study of 362 cases. *J Oral Pathol Med* 2002;31:415-20.
15. Mosqueda-Taylor A, Ledesma-Montes C, Caballero-Sandoval S, Portilla-Robertson J, Ruiz-Godoy Rivera LM, Meneses-García A. Odontogenic tumors in Mexico: a collaborative retrospective study of 349 cases. *Oral Surg Oral Med Oral Pathol Oral Radiol Endod* 1997;84:672-5.
16. Philipsen HP, Reichart PA, Praetorius F. Mixed odontogenic tumours and odontomas. Considerations on interrelationship. Review of the literature and presentation of 134 new cases of odontomas. *Oral Oncol* 1997;33:86-99.
17. Hisatomi M, Asaumi JI, Konouchi H, Honda Y, Wakasa T, Kishi K. A case of complex odontoma associated with an impacted lower deciduous second molar and analysis of the 107 odontomas. *Oral Dis* 2002;8:100-5.
18. Tomizawa M, Otsuka Y, Noda T. Clinical observations of odontomas in Japanese children: 39 cases including one recurrent case. *Int J Paediatr Dent* 2005;15:37-43.
19. Hidalgo-Sánchez O, Leco-Berrolcal MI, Martínez-González JM. Metaanalysis of the epidemiology and clinical manifestations of odontomas. *Med Oral Patol Oral Cir Bucal* 2008;13:E730-4.
20. Piattelli A, Perfetti G, Carraro A. Complex odontoma as a periapical and interraderic radiopacity in a primary molar. *J Endod* 1996;22:561-3.
21. Piattelli M, Paolantonio M. Compound odontoma associated with a primary molar. *Acta Stomatol Belg* 1995;92:129-30.
22. Vengal M, Arora H, Ghosh S, Pai KM. Large erupting complex odontoma: A case report. *J Can Dent Assoc* 2007;73:169-73.
23. Fernandes AM, Duarte EC, Pimenta FJ, Souza LN, Santos VR, Mesquita RA, *et al.* Odontogenic tumors: A study of 340 cases in a Brazilian population. *J Oral Pathol Med* 2005;34:583-7.
24. Batra P, Duggal R, Kharbanda OP, Parkash H. Orthodontic treatment of impacted anterior teeth due to odontomas: A report of two cases. *J Clin Pediatr Dent* 2004;28:289-94.
25. Serra-Serra G, Berini-Aytés L, Gay-Escoda C. Erupted odontomas: A report of three cases and review of the literature. *Med Oral Patol Oral Cir Bucal* 2009;14:E299-303.
26. Tozoglu S, Yildirim U, Buyukkurt MC. An erupted complex odontoma. *N Y State Dent J* 2010;76:52-3.
27. Hanemann JA, Oliveira DT, Garcia NG, Santos MR, Pereira AA. Peripheral compound odontoma erupting in the gingiva. *Head Face Med* 2013;9:15.

How to cite this article: Bereket C, Çakır-Özkan N, Şener İ , Bulut E, Tek M. Complex and compound odontomas: Analysis of 69 cases and a rare case of erupted compound odontoma. *Niger J Clin Pract* 2015;18:726-30.

Source of Support: Nil, **Conflict of Interest:** None declared.