

“Pyogenic Granuloma - Hyperplastic Lesion of the Gingiva: Case Reports”

Pushpendra Kumar Verma^{*}, Ruchi Srivastava, H.C. Baranwal, T.P. Chaturvedi, Anju Gautam[#] and Amit Singh[#]

Faculty of Dental Sciences, I.M.S, Banaras Hindu University, Varanasi- 221005, Uttar Pradesh, India

Abstract: Pyogenic granuloma is a reactive hyperplasia of connective tissue in response to local irritants. It is a tumour-like growth of the oral cavity, frequently located surrounding the anterior teeth or skin that is considered to be neoplastic in nature. It usually arises in response to various stimuli such as low-grade local irritation, traumatic injury, hormonal factors, or certain kinds of drugs. Histologically, the surface epithelium may be intact, or may show foci of ulcerations or even exhibiting hyperkeratosis. It overlies a mass of dense connective tissue composed of significant amounts of mature collagen. Gingiva is the most common site affected followed by buccal mucosa, tongue and lips. Pyogenic granuloma in general, does not occur when excised along with the base and its causative factors. This paper presents some cases of a pyogenic granuloma managed by surgical intervention.

Keywords: Pyogenic granuloma, benign neoplasm, hyperplastic lesion.

INTRODUCTION

Localized hyperplastic lesions of the gingiva or “Epulides” as they are commonly known, are a well recognized entity since generations. The word ‘epulis’ is derived from Greek “epi” and “elon”; meaning ‘on the gingiva’. Thus logically this term can be used to describe the clinical appearance of any lesion that appears on the gingiva. This term however, does not give any indication about the nature of the lesion [1, 2].

The term “pyogenic granuloma” is a misnomer because the lesion does not contain pus and is not strictly speaking a granuloma. Approximately one-third of the lesions occur due to trauma and poor oral hygiene may also be one of the precipitating factors [3]. It often presents as a painless, pedunculated, or sessile mass of gingiva.

Pyogenic granuloma is the most common of all the oral tumorlike growths. While the terminology implies a benign neoplasm, most if not all fibromas represent reactive focal fibrous hyperplasias due to trauma or local irritation. Although the term “focal fibrous hyperplasia” more accurately describes the clinical appearance and pathogenesis of this entity, it is not commonly used.

Pyogenic granuloma is a hyperactive benign inflammatory lesion that occurs mostly on the mucosa of females with high levels of steroid hormones. It is generally believed that female sex hormones play important roles in its pathogenesis [3]. It is a tumourlike growth of the oral cavity (frequently located surrounding the anterior teeth) or skin that is considered to be neoplastic in nature [4]. It usually arises in response to various

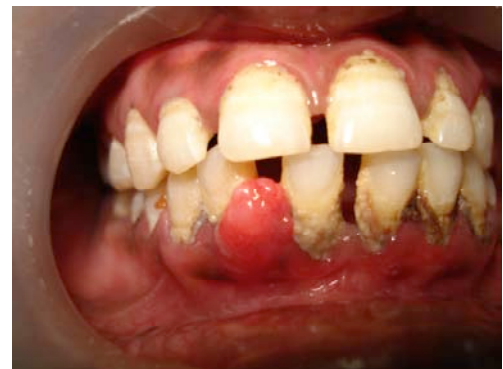

Fig. (1). Pre-operative.

stimuli such as low-grade local irritation [5], traumatic injury, hormonal factors [6], or certain kinds of drugs [7].

CASE REPORTS

Case 1

A 30 years old female patient presented to the Faculty of Dental Sciences, BHU, Varanasi, with a chief complaint of pain and swelling on gums at lower front region of the jaw lasting 2 months and which was gradually increasing in size. On clinical examination a localized gingival swelling of 1.5cm X 1cm size with clear signs of inflammation was present in relation to 41, 42 (Fig. 1). The swelling was a smooth exophytic lesion manifested as a small erythematous papule on a pedunculated base which was hemorrhagic with spontaneous bleeding on probing the area (Fig. 2). The lesion was painless and asymptomatic except for the slight discomfort to the patient due to the growth. Physical examination revealed no other abnormalities, and there was no cervical lymphadenopathy. On hard tissue examination there were 31 teeth with atraumatic occlusion. There was moderate supra- and subgingival calculus with moderate gingivitis. Grade 1

^{*}Address correspondence to this author at the Faculty of Dental Sciences, I.M.S, Banaras Hindu University, Varanasi- 221005, Uttar Pradesh, India; Tel: +91-8009752090; E-mail: pushpendrakgmc@gmail.com

[#]Both author contribute equally

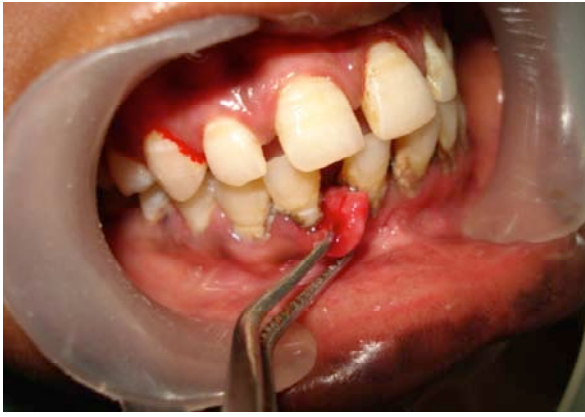

Fig. (2). Pre-operative (lateral view).

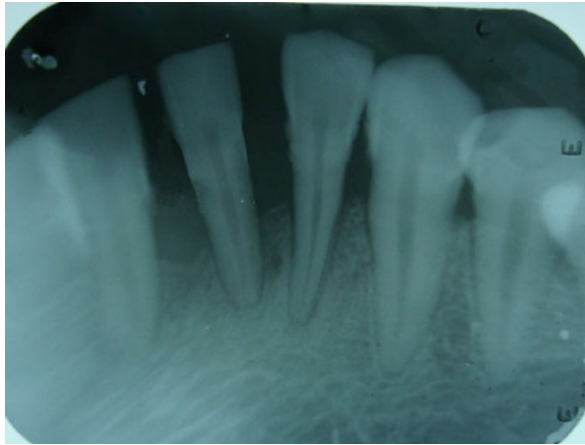


Fig. (3). I.O.P.A. radiograph showing bone loss.

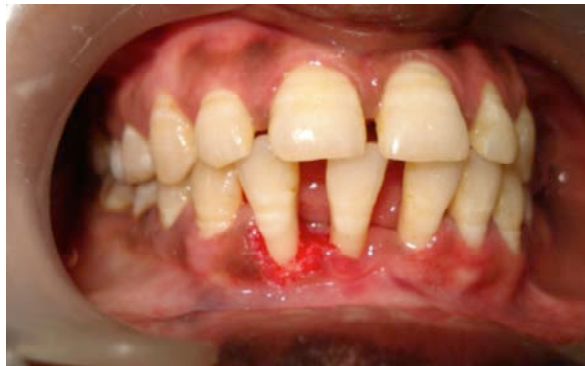

Fig. (4). After excision.

mobility was present in tooth 42. The patient's medical history was uneventful. The periapical radiograph showed a deep bony defect extending from 41 to 42 (Fig. 3).

So by considering all the above features a provisional diagnosis of pyogenic granuloma was made and excisional biopsy was planned. A conventional non-surgical therapy was first of all performed, with full mouth scaling and root planing. There was severe bleeding while doing scaling and curettage. However, the bleeding stopped within a few minutes by applying pressure with gauze. The patient was advised to perform and maintain their oral hygiene by brushing twice a day and to use a chlorhexidine mouth rinse of 0.2% twice daily. On observation, there was a gradual reduction in the growth after 2 weeks.

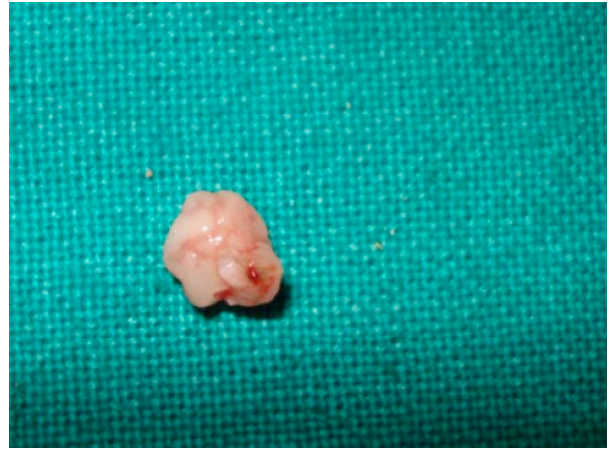

Fig. (5). Excised tissue.

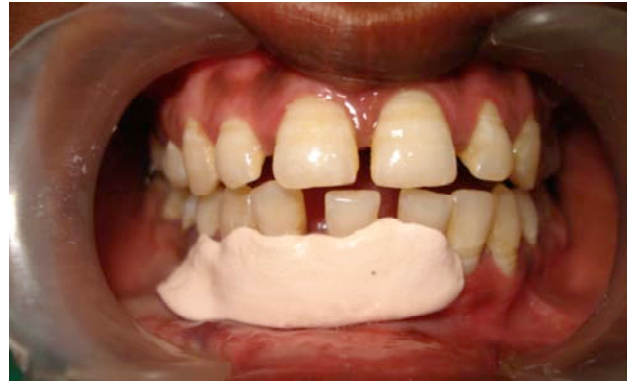

Fig. (6). Periodontal dressing.

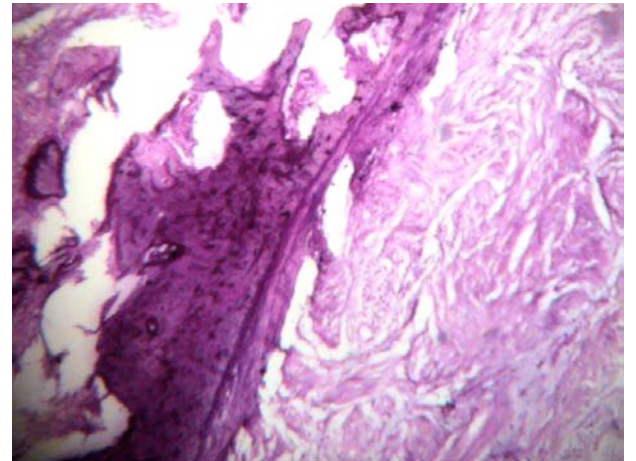


Fig. (7). Histopathologic slide.

Thereafter, it was decided to further treat the lesion with a surgical approach. After local anesthesia, the enlarged localized lesion was excised with help of a 15 no. B.P. blade up to the base of the lesion (Fig. 4, 5). It was ensured that the lesion was completely excised by trimming up the remnants of the soft tissue adjacent to the tooth to prevent recurrence of the lesion. After excision, a periodontal dressing was applied to prevent the wound from trauma and to enhance healing for 1 week (Fig. 6). Antibiotics and analgesics were prescribed for 1 week. The excised tissue was sent for histological examination (Fig. 7). Based on a histological report it was finally diagnosed as a pyogenic granuloma.

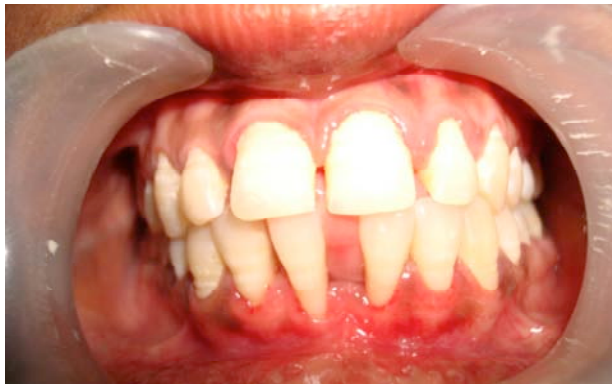

Fig. (8). Post-operative.

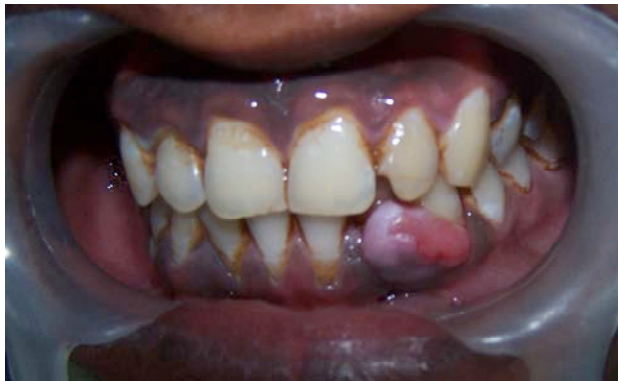

Fig. (9). Pre-operative.

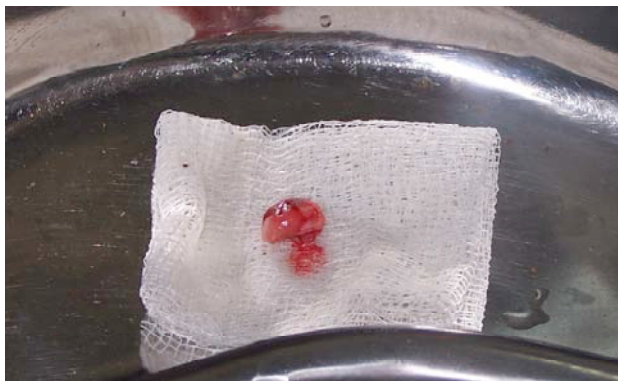

Fig. (10). Excised tissue.

The patient was recalled every month for a checkup. After 4 weeks there was no growth visible clinically. It was totally eliminated (Fig. 8). Supportive periodontal maintenance at 3 months was prescribed to maintain periodontal health and to re-evaluate this area. There was no recurrence even at the end of 6 months. At 1-yr recall, the gingival tissues were healthy with successful healing and no more recurrence. Furthermore, the patient was referred for a periodontal bone grating procedure for management of bone loss and thereafter for orthodontic treatment of mal-aligned teeth.

Case 2

A 27 year-old male patient presented to the Faculty of Dental Sciences, BHU, Varanasi, with a chief complaint of a swelling on the gums at the lower front region of the jaw lasting 3 months (Fig. 9). On clinical examination, a localized gingival swelling of 2cm X 1cm in size with clear signs

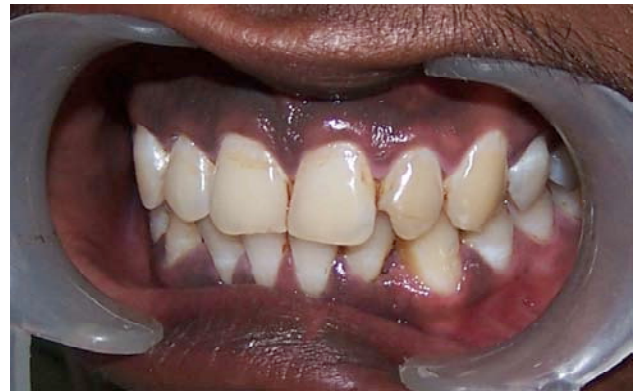

Fig. (11). Post-operative.

of inflammation was present in relation to 32,33. The lesion was firm in consistency and bleeding on probing was present. The patient’s medical history was uneventful. First of all, full mouth scaling and root planing were done. After reduction in the inflammation, at about 10 days, surgery was planned for excision of the lesion. After local anesthesia, the lesion was excised with the help of a 15 no. B.P. blade up to the base of the lesion (Fig. 10). It was ensured that the lesion was completely excised to prevent recurrence of the lesion. After excision a periodontal dressing was applied for 1 week. Antibiotics and analgesics were prescribed for 1 week. The patient was monitored on a weekly schedule postoperatively, to ensure good oral hygiene in the surgical area (Fig. 11). At 1-yr recall, the gingival tissues were healthy with successful healing and no more recurrence.

DISCUSSION

Pyogenic granuloma is an inflammatory hyperplasia affecting the oral tissues. Hullihen’s description in 1844 was most likely the first pyogenic granuloma reported in the English literature. It was only in 1904 that Hartzell first ever introduced the term pyogenic granuloma [8]. It is now universally agreed that this lesion is formed as a result of an exaggerated localized connective tissue reaction to a minor injury or any underlying irritation [9]. The irritating factor can be calculus, poor oral hygiene, nonspecific infection, over hanging restorations, cheek biting etc. Because of this irritation, the underlying fibrovascular connective tissue becomes hyperplastic and there is proliferation of granulation tissue which leads to the formation of a pyogenic granuloma [10]. Pyogenic granuloma may occur at all ages but is predominantly seen in the second decade of life in young adult females, possibly because of the vascular effects of female hormones [11]. The gingiva is the most commonly site affected followed by the buccal mucosa, tongue and lips [8]. Pyogenic granuloma in general, does not reoccur when excised along with its base and all the causative factors are removed. This paper presents a case of a pyogenic granuloma managed by surgical intervention.

According to Vilmann et al, the majority of the pyogenic granulomas are found on the marginal gingiva with only 15% of the tumors on the alveolar part [4]. Studies by Zain RB *et al.*, in Singapore populations have also shown the greatest incidence of pyogenic granuloma in the second decade of life [12].

Clinically pyogenic granuloma is generally seen as a smooth or lobulated exophytic lesion with a pedunculated or a sessile base. Pyogenic granuloma grows in size from a few millimeters to several centimetres in size but rarely exceed more than 2.5cm.. Many of the pyogenic granulomas grow rapidly and attain large sizes [13]. It has been reported many times that pyogenic granulomas may cause significant bone loss [14]. In case report-1 a significant bone loss can be clearly seen (Fig. 3).

Treatment of pyogenic granuloma involves a complete surgical excision [8]. Recurrence of pyogenic granuloma after excision is a known complication but can be prevented. The recurrence rate for pyogenic granuloma is said to be 16% of the treated lesions and so re-excision of such lesions might be necessary [8]. Various other benign soft tissue lesions need to be differentiated from pyogenic granuloma. A few of these include peripheral giant cell granuloma, pregnancy tumor; and conventional granulation tissue [8, 11]. Differentiation is done on clinical and histological features which help in providing adequate treatment and therefore a good prognosis. Histologically, the surface epithelium may be intact, or may show foci of ulcerations or even exhibit hyperkeratosis. It overlies a mass of dense connective tissue composed of significant amounts of mature collagen (Fig. 7). Pyogenic granuloma can be adequately treated with the correct diagnosis and proper treatment planning. A careful management of the lesion also helps in preventing the recurrence of this benign lesion.

CONCLUSION

With the presentation of this paper it can be concluded that the combinations of various etiological factors might have caused the inflammatory tissue to cross the threshold from regular gingivitis to granuloma formation. The lesion was painless as nerves do not proliferate within the reactive hyperplastic tissue. Surgical excision is a successful treatment of choice in minimizing the recurrence of lesion. So, the consideration should also be given to correct diagnosis and proper treatment planning. A careful management of the lesion should be performed while preserving and improving the mucogingival complex.

CONFLICT OF INTEREST

The authors confirm that this article content has no conflicts of interest.

ACKNOWLEDGEMENT

None declared.

REFERENCES

- [1] Macleod RI, Soames JV. Epulides: a clinicopathological study of a series of 200 consecutive lesions. *Br Dent J* 1997; 163 : 51-3.
- [2] Anneroth G, Sigurdson A. Hyperplastic lesion of the gingiva and oral mucosa: a study of 175 cases. *Acta Odontol Scand* 1983; 41: 75-86.
- [3] Bhaskar SN, Jacoway JR. Pyogenic granulom: clinical features, incidence, histology, and result of treatment: report of 242 cases. *J Oral Surg* 1966; 24(5): 391-8.
- [4] Vilmann A, Vilmann P, Vilmann H. Pyogenic granuloma: evaluation of oral conditions. *Br J Oral Maxillofac Surg* 1986; 24(5): 376-82.
- [5] Regezi JA, Sciubba JJ, Jordon RCK. *Oral pathology: clinical pathological considerations*. 4th ed. Philadelphia, Pa, USA: WB Saunders 2003.
- [6] Mussalli NG, Hopps RM, Johnson NW. Oral pyogenic granuloma as a complication of pregnancy and the use of hormonal contraceptives. *Int J Gynaecol Obstet* 1976; 14(2): 187-91.
- [7] Miller RAW, Ross JB, Martin J. Multiple granulation tissue lesions occurring in isotretinoin treatment of acne vulgaris: successful response to topical corticosteroid therapy. *J Am Acad Dermatol* 1985; 12 (5): 888-9.
- [8] Jafarzadeh H, Sanatkhan M, Mohtasham N. Oral pyogenic granuloma: a review. *J Oral Sci* 2006; 48(4): 167-75.
- [9] Mathur LK, Bhalodi AP, Manohar B, Bhatia A, Rai N, Mathur A. Focal fibrous hyperplasia: a case report. *Int J Dent Clin* 2010; 2(4): 56-7.
- [10] Kerr DA. Granuloma pyogenicum. *Oral Surg Oral Med Oral Pathol* 1951; 4(2): 158.
- [11] Lawoyin J, Arotiba J, Dosumu O. Oral pyogenic granuloma: a review of 38 cases from Ibadan, Nigeria. *Br J Oral Maxillofac Surg* 1997; 35(3): 185-9.
- [12] Zain R, Khoo S, Yeo J. Oral pyogenic granuloma clinical analysis of 304 cases. *Singapore Dent J* 1995; 20(1): 8-10.
- [13] Parisi E, Glick P, Glick M. Recurrent intraoral pyogenic granuloma with satellitosis treated with corticosteroids. *Oral Dis* 2006; 12(1): 70-2.
- [14] Goodman-Topper E, Bimstein E. Pyogenic granuloma as a cause of bone loss in a twelve-year-old child: report of case. *ASDC J Dent Child* 1994; 61(1): 65-7.

Received: June 24, 2012

Revised: July 31, 2012

Accepted: August 07, 2012

© Verma et al.; Licensee Bentham Open.

This is an open access article licensed under the terms of the Creative Commons Attribution Non-Commercial License (<http://creativecommons.org/licenses/by-nc/3.0/>) which permits unrestricted, non-commercial use, distribution and reproduction in any medium, provided the work is properly cited.