

# Use of AlloDerm Implant to Prevent Frey Syndrome After Parotidectomy

Uttam K. Sinha, MD; Daryoush Saadat, MD; Carolyn M. Doherty, MD; Dale H. Rice, MD

**Objective:** To evaluate the effectiveness of AlloDerm, an acellular human dermal matrix graft, as an interpositional physical barrier to prevent the development of Frey syndrome after parotidectomy.

**Methods:** The 30 patients included in the study were divided into 3 groups of 10. In group 1 (study group), patients underwent superficial parotidectomy with placement of an AlloDerm graft (LifeCell Corp, Branchburg, NJ). In group 2 (control) patients had superficial parotidectomy without placement of an interpositional barrier. In group 3 (control), patients underwent deep-plane rhytidectomy without disruption of the parotid fascia. All were evaluated after 1 year and questioned about gustatory sweating. Subjective assessment of Frey syndrome was documented when patients experienced gustatory sweating, even if they were not perturbed by the symptom. The Minor

starch-iodine test was performed in each patient for objective assessment.

**Results:** The incidence of subjective Frey syndrome was observed in 1 patient in group 1 and 5 patients in group 2. The incidence of objective Frey syndrome was noted in 2 patients in group 1 and 8 patients in group 2. Both subjective and objective differences in incidence of Frey syndrome were statistically significant. None of the group 3 patients had subjective or objective Frey syndrome. Two patients in group 1 and 3 patients in group 2 developed a transient seroma or sialocele that resolved with conservative management.

**Conclusion:** The use of AlloDerm graft as an interpositional barrier improves parotidectomy outcome by reducing the incidence of Frey syndrome.

*Arch Facial Plast Surg. 2003;5:109-112*

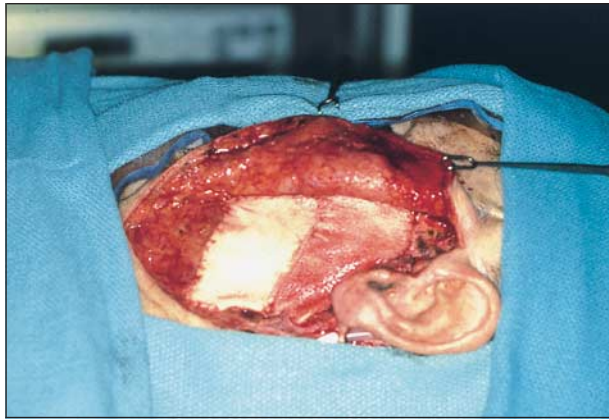
From the Department of Otolaryngology–Head and Neck Surgery, University of Southern California School of Medicine, Los Angeles.

**F**REY SYNDROME or gustatory sweating is described as the sweating and flushing of facial skin during salivation. Baillarger, in 1853, was probably the first to report this phenomenon but it was Frey who recognized its association with the auriculo-temporal nerve.<sup>1,2</sup> Frey syndrome is a common occurrence after parotidectomy and it usually develops within the first year after surgery.<sup>3</sup> The reported incidence in the literature varies enormously, ranging from 2% to 100%,<sup>3</sup> and this can be attributed to the assessment methods used. Low incidence is reported when assessed by patient report; high incidence is reported when assessed with sensitive objective testing (ie, the Minor starch-iodine test). It is postulated that this syndrome develops postoperatively, following disruption of the parotid fascia. It is caused by the exposure of postganglionic parasympathic fibers that,

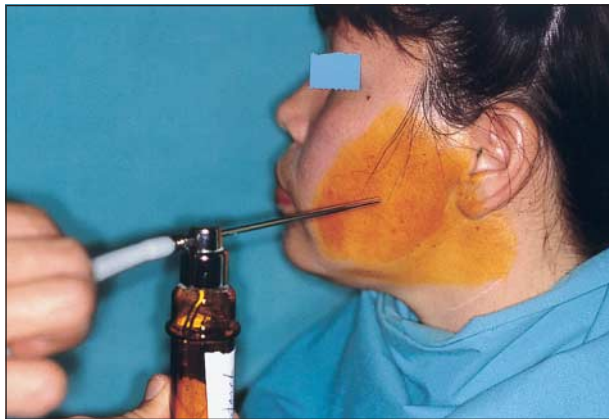instead of innervating the parotid salivary glands, aberrantly innervate cutaneous sweat glands.

Surgical and nonsurgical treatments of this socially embarrassing condition have been challenging. Nonsurgical treatments include topical antiperspirants, anticholinergic agents, antihistamine creams, alcohol injections in the otic ganglion, and tympanic neurectomy.<sup>4-6</sup> Recently, intradermal injection of botulinum toxin has gained popularity.<sup>7</sup> However, these interventions are not effective in controlling gustatory sweating. Moreover, they do not correct the facial deformity associated with parotidectomy.

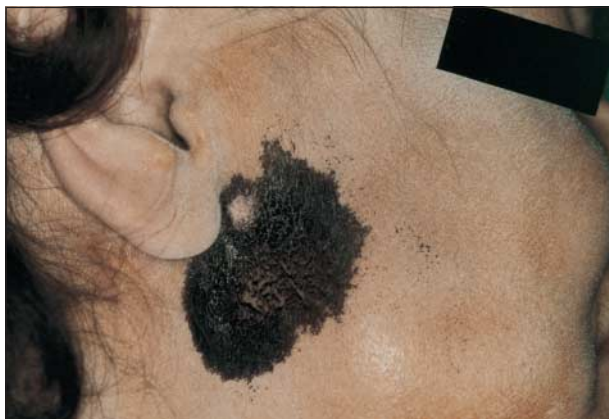Various surgical techniques have been used to prevent Frey syndrome. They involve placement of an interpositional barrier to separate skin flap from exposed parotid tissue. Autogenous vascularized tissue (sternocleidomastoid rotational flap, temporoparietal fascia rotational flap, subsuperficial musculoaponeurotic



**Figure 1.** Parotidectomy defect reconstruction with AlloDerm (acellular human dermal allograft).



**Figure 2.** Minor starch-iodine test. The parotid area is painted with iodine and sprayed with starch powder.



**Figure 3.** Positive Minor starch-iodine test result showing starch color change from white to dark purple.

system elevation of skin flap),<sup>8-11</sup> nonvascularized tissue (lyophilized dura, dermis fat grafts, fascia lata), and synthetic biomaterials (expanded polytetrafluoroethylene) have been used for this purpose.<sup>12,13</sup> These techniques all address the soft tissue defect associated with parotidectomy.

The purpose of this study was to test the effectiveness of AlloDerm (LifeCell Corp, Branchburg, NJ) both as an alternative interpositional barrier to prevent Frey

syndrome after parotidectomy and as a soft tissue filler to prevent the postoperative hollow deformity. We chose AlloDerm for its availability, its easiness of use, its incorporation in the recipient tissue, and its low risk of extrusion. AlloDerm, an acellular human dermal matrix, has been recently introduced as an implant for soft tissue support and coverage.<sup>14-16</sup> It is derived from cadaveric skin that has been screened for human immunodeficiency virus, hepatitis B and C virus, human T-lymphotropic virus type 1, and syphilis.<sup>14-16</sup> In the multistep processing of AlloDerm, the epidermis and all the dermal cellular components are removed, leaving no reservoir for viral agents.<sup>15</sup> As a result, no immune response is elicited after placement of the allograft. The biochemical and structural integrity of collagen type IV is maintained in the dermal matrix.<sup>15</sup>

## METHODS

### SUBJECTS

This study was performed in a university setting with institutional review board approval. It was designed to include 30 subjects divided into 3 groups of 10. Group 1 was the study group and groups 2 and 3 were controls. Patients in group 1 underwent superficial parotidectomy with placement of an AlloDerm graft and patients in group 2 had superficial parotidectomy without placement of an interpositional barrier. Group 3 patients underwent deep-plane rhytidectomy and, therefore, had surgery in the same region but without disruption of the parotid fascia. Patients were excluded if they were younger than 18 years, had a malignant parotid tumor, were allergic to iodine, or had a history of Frey syndrome before surgery. Subjective Frey syndrome was documented at the 1-year follow-up when patients were asked specifically whether they had experienced symptoms of gustatory sweating. Those who noticed gustatory sweating were determined to have subjective Frey syndrome even if they were not disturbed by the symptom.

### OPERATIVE TECHNIQUE

After performing superficial parotidectomy, the soft tissue defect was reconstructed with folded sheets of AlloDerm. After a satisfactory contour was obtained, a thick graft (900  $\mu\text{m}$ ) was used to cover the entire parotid bed. It was carefully sutured to the masseter muscle anteriorly, the zygomatic arch superiorly, the sternocleidomastoid muscle posteroinferiorly, the tragal perichondrium preauricularly, and the mastoid periosteum postauricularly (**Figure 1**). A suction drain was placed under the skin flap. All postoperative complications were documented.

### STARCH-IODINE TEST

The presence or absence of Frey syndrome was determined by performing the Minor starch-iodine test at least 1 year after surgery. Both the surgical side and the opposite side (control) of the face were painted with an iodine solution (**Figure 2**). The painted areas were then sprayed with powder starch and the patients sucked on a lemon-drop candy to stimulate salivation. The tested area was examined after 10 minutes for the presence of gustatory sweating. A color change of the starch to dark purple signified the presence of Frey syndrome and the test was considered positive (**Figure 3**). A  $\chi^2$  test was used to compare the results of the 2 parotidectomy groups.

## RESULTS

Subjective Frey syndrome was noted in 1 patient from group 1 and 5 patients from group 2. This difference was statistically significant ( $P < .05$ ). Two patients from group 1 and 8 from group 2 had a positive starch-iodine test. This difference was also statistically significant ( $P < .05$ ). As expected, none of the 10 postrhytidectomy patients had subjective or objective Frey syndrome. This confirmed the theory that disruption of the parotid fascia and exposure of parasympathetic fibers are necessary for development of Frey syndrome.

There were no major postoperative complications. Five of the 20 patients had transient seroma or sialocele that were successfully treated with needle aspiration and pressure dressing. Two were from group 1 and 3 from group 2. None of the patients developed hematoma, salivary fistula, wound infection, or facial nerve weakness. There was no case of allograft extrusion in the AlloDerm group.

## COMMENT

The use of AlloDerm significantly decreased the incidence of Frey syndrome in this study. We tested the patients at least 1 year after surgery. Subjective Frey syndrome was documented if the patients admitted on questioning that they had noticed gustatory sweating—even if they were not perturbed by the symptom. Objective evidence of this syndrome was established by performing the classic Minor starch-iodine test. Similar results have been reported using other interpositional barriers.<sup>8-13</sup> However, in these studies, comparison of the results is difficult owing to differences in protocol design. These differences include (1) method of assessment, ie, subjective only<sup>9</sup> or subjective and objective<sup>12,13</sup>; (2) classic Minor starch-iodine test,<sup>11</sup> or a variation of the Minor test, or newly developed tests for Frey syndrome<sup>12</sup>; and (3) the temporal relationship of surgery and testing for the presence of Frey syndrome.<sup>3</sup> Linder et al<sup>3</sup> documented the importance of the temporal relation of surgery to the development of Frey syndrome by observing the patients prospectively for 1 year. They reported that 38% of patients had a positive starch-iodine test 3 months after surgery, and 96% 1 year after surgery.

Autogenous interpositional barriers have the advantage of greater patient acceptability because of lower rates of infection, extrusion, and rejection. They are, however, associated with donor-site morbidity, longer operative times, a limited availability of tissue for larger defects, and a limited arc of rotation for vascularized tissue. In addition, their success rates in preventing Frey syndrome have been inconsistent.<sup>8-13</sup>

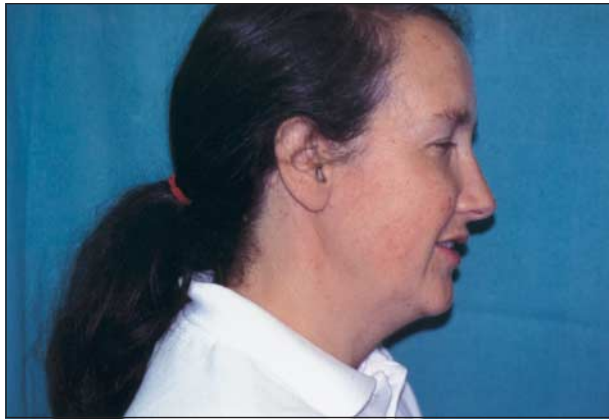Nonautologous implants have several advantages: an unlimited and readily available supply, ease of positioning and contouring, shorter operative times, and no donor-site morbidity. Their disadvantages are lower patient acceptability due to greater risks of infection, rejection, and/or extrusion. Shemen<sup>13</sup> reported the successful use of expanded polytetrafluoroethylene soft tissue patch to correct the postparotidectomy deformity. The incidence of Frey syndrome before expanded polytetra-

fluoroethylene reconstruction (after the initial parotidectomy) was not reported in Shemen's study. In a study by Dulguerov et al,<sup>12</sup> the incidence of Frey syndrome was reported both in the control group (no implant) and in patients with different types of implants (the study group). These authors reported a significant decrease in the incidence of Frey syndrome in patients with interpositional barriers. The lowest incidence (8%) was in the expanded polytetrafluoroethylene group; this group, however, had a 25% rate of salivary fistulas and 2 of the 25 implants had to be removed because of extrusion. In our study, AlloDerm implants resulted in Frey syndrome in 2 (20%) patients but none of the implants extruded. Two of our 10 parotidectomy patients who received an AlloDerm implant had a positive starch-iodine test but only 1 complained of subjective gustatory sweating. Even though it is unclear why these 2 cases of Frey syndrome occurred, we would like to emphasize the surgical technique that we used for AlloDerm parotidectomy. We recommend that the entire parotid bed be covered with AlloDerm and sutured in a watertight fashion to the masseter muscle anteriorly, the zygomatic arch superiorly, the sternocleidomastoid muscle posteroinferiorly, the tragal perichondrium preauricularly, and the mastoid periosteum postauricularly (Figure 1).

Use of AlloDerm or any interpositional barrier in parotidectomy raises two concerns. First, although the chance of recurrence for benign parotid disease is very low, the difficulties met in reoperating are uncharted, especially that of identifying and preserving the facial nerve during reexploration of the parotid bed. Second, long-term maintenance of the soft tissue augmentation is unpredictable because the amount of graft resorption cannot be assessed ahead of time. Obviously, long-term follow-up of a large study population is necessary to address these questions.

The only postoperative complication noted in the present study was transient seroma or sialocele in 5 patients (3 in group 1 and 2 in group 2). All lesions resolved within 1 week following aspiration and application of pressure dressing. Although postparotidectomy salivary fistulas have been documented as common complications of the procedure, seroma or sialoceles are rarely mentioned in most reviews.<sup>17</sup> Parotidectomy in these 5 patients was performed during the early part of the study; suction drains were removed on the first postoperative day and we did not use pressure dressing following parotidectomy. We now believe that the combination of early drain removal and absence of pressure dressing produced this complication. Currently, we do not remove the drain unless drainage is less than 10 mL per 8 hours. Patients are discharged with the drain in place and instructed to measure the output at home. They return to the office for removal of the drain when the output is less than 10 mL per 8 hours. This approach eliminates seroma or sialocele formation.

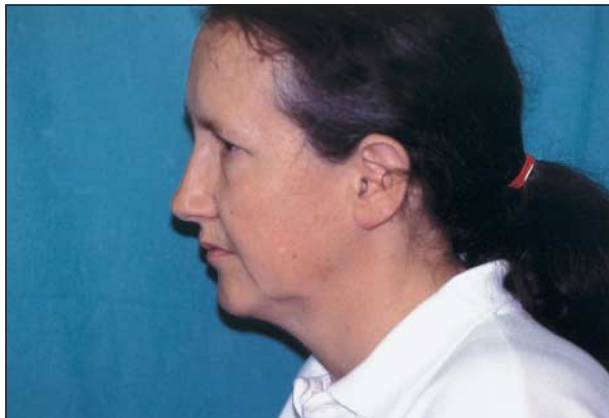Although determination of cosmetic improvement was not the goal of the study, using AlloDerm to fill in the parotid bed resulted in better cosmesis of the surgical site. This additional benefit of using AlloDerm was observed in all patients. The photographs of one of the representative patients showing frontal, lateral, and ob-



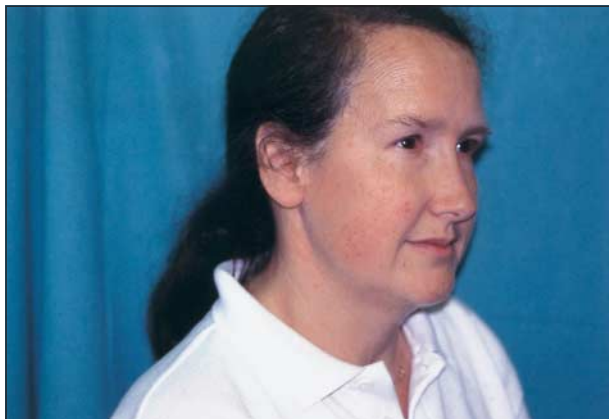**Figure 4.** Representative patient after AlloDerm (acellular human dermal allograft) reconstruction of right parotidectomy defect (right lateral view).



**Figure 7.** Same patient as in Figure 4, side not operated on (left oblique view).



**Figure 5.** Same patient as in Figure 4, side not operated on (left lateral view).



**Figure 6.** Same patient as in Figure 4, side operated on (right oblique view).

lique views demonstrate restoration of good soft tissue contour at the surgical site (**Figures 4, 5, 6, and 7**).

In conclusion, this study tested the effectiveness of AlloDerm as an alternative interpositional barrier during parotidectomy to prevent the development of Frey syndrome. Subjective and objective Frey syndrome were documented. Results showed that an AlloDerm implant improves parotidectomy outcome by reducing the incidence of Frey syndrome and improving cosmesis.

Accepted for publication June 2, 2001.

This study was supported by a grant from LifeCell Corp.

This study was presented at the American Academy of Facial Plastic and Reconstructive Surgery Section of the Combined Otolaryngological Spring Meetings, Orlando, Fla, May 12, 2000.

Corresponding author and reprints: Uttam K. Sinha, MD, Department of Otolaryngology–Head and Neck Surgery, University of Southern California School of Medicine, 1200 N State St, Box 795, Los Angeles, CA 90033 (e-mail: [sinhauk@aol.com](mailto:sinhauk@aol.com)).

## REFERENCES

- Baillarger M. Mémoire sur l'oblitération du canal de Sténon. *Gazette Méd Paris*. 1853;23:194.
- Frey L. Le syndrome du nerf auriculo-temporal. *Rev Neurol (Paris)*. 1923;2:97-104.
- Linder TE, Huber A, Schmid S. Frey's syndrome after parotidectomy: a retrospective and prospective analysis. *Laryngoscope*. 1997;107:1496-1501.
- Laage-Hellman JE. Treatment of gustatory sweating and flushing. *Acta Otolaryngol*. 1958;49:132-133.
- Hays LL, Novack AJ, Worsham JC. The Frey syndrome: a simple, effective treatment. *Otolaryngol Head Neck Surg*. 1982;90:419-425.
- Smith RO Jr, Hemmenway WC, Stevens KM, et al. Jacobson's neurectomy for Frey's syndrome. *Am J Surg*. 1970;120:470-481.
- Cohen AA, Blitzer A. Botulinum toxin treatment of symptomatic Frey's syndrome. *Otolaryngol Head Neck Surg*. 2000;122:237-240.
- Rubinstein RY, Rosen A, Leeman D. Frey syndrome: treatment with temporo-parietal fascia flap interposition. *Arch Otolaryngol Head Neck Surg*. 1999;125:808-811.
- Casler JD, Conley J. Sternocleidomastoid muscle transfer and superficial musculoaponeurotic system plication in the prevention of Frey's syndrome. *Laryngoscope*. 1991;101:95-100.
- Kornhub AD, Westphal P, Miehlke A. The effectiveness of a sternomastoid muscle flap in preventing post-parotidectomy occurrence of the Frey syndrome. *Acta Otolaryngol*. 1974;77:368-373.
- Taylor SM, Yoo J, Mathews TW, et al. Frey's syndrome and parotidectomy flaps: a retrospective cohort study. *Otolaryngol Head Neck Surg*. 2000;122:201-203.
- Dulguerov P, Qunodoz D, Cosendai G, et al. Prevention of Frey syndrome during parotidectomy. *Arch Otolaryngol Head Neck Surg*. 1999;125:833-839.
- Shemen LJ. Expanded polytef for reconstructing postparotidectomy defects and preventing Frey's syndrome. *Arch Otolaryngol Head Neck Surg*. 1995;121:1307-1309.
- Wainwright DJ, Madden M, Luterman A, et al. Clinical evaluation of an acellular allograft dermal matrix in full-thickness burns. *J Burn Care Rehabil*. 1996;17:124-136.
- Kridel RWH, Foda H, Luce KC. Septal perforation repair with acellular human dermal allograft. *Arch Otolaryngol Head Neck Surg*. 1998;124:73-78.
- Jones FR, Schwartz BM, Silverstein P. Use of a nonimmunogenic acellular dermal allograft for soft tissue augmentation. *Aesthetic Surg Q*. 1996;16:196-201.
- Wax M, Tarshis L. Post-parotidectomy fistula. *J Otolaryngol*. 1991;20:10-13.