

Investigation and diagnosis of an immediate allergy to amide local anaesthetic in a paediatric dental patient

G Allen,*  D Chan,† S Gue*

*Department of Paediatric Dentistry, Women's and Children's Hospital, North Adelaide, South Australia, Australia.

†Department of Allergy and Clinical Immunology, Women's and Children's Hospital, North Adelaide, South Australia, Australia.

ABSTRACT

Local anaesthetics remain the most common prescription medication utilized in dental practise. Adverse reactions following administration of local anaesthetic are somewhat common and are frequently reported as 'allergies'. However, of these events, it is estimated that only 1% are confirmed allergies to the local anaesthetic. This case report presents the process of referral for investigation and testing to confirm an amide local anaesthetic allergy in a paediatric patient. Testing for a safe alternative was also completed to identify local anaesthetic agents also of the amide variety that could be utilized safely on this individual. Following skin testing of alternative agents, intraoral challenges were completed. Finally, restorative dental treatment was provided safely for the patient with the use of an alternative amide local anaesthetic on a number of occasions with no further adverse outcomes.

Keywords: Adverse reaction, amide allergy, immediate allergy, local anaesthetic, paediatric.

Abbreviations and acronyms: BSACI = British Society for Allergy and Clinical Immunology; EAACI = European Academy of Allergy and Clinical Immunology; EDTA = ethylenediaminetetraacetic acid; ENDA = European Network on Drug Allergy; Ig = immunoglobulin.

(Accepted for publication 29 January 2017.)

INTRODUCTION

Local anaesthetics are reported to be the most common prescription or S4 drug utilized in dental practise with an estimate made in 2009 suggesting that 11 million cartridges of dental local anaesthetics were used per year in Australia.¹ Systemic reactions resulting from the administration of dental local anaesthetic are often described as a patient being 'allergic' to the local anaesthetic. Although there are a number of compounds present in dental local anaesthetic that patients can theoretically be allergic to, it is exceedingly rare for patients to have a true confirmed allergy to dental local anaesthetics.² More common explanations for the systemic sequelae are related to drug overdose, rapid absorption, intravascular injection, cardiovascular, central nervous system and psychogenic or idiosyncratic reactions.² Despite being reported by patients somewhat frequently, a true allergic reaction to dental local anaesthetic is rare with reports that an allergy to local anaesthetic is responsible for only 1% of adverse systemic reactions.^{2,3} Only case reports of confirmed local anaesthetic allergies exist in the literature, making it difficult to accurately report on the prevalence. Rood completed skin and intraoral challenges of 44

adult patients suspected of having a local anaesthetic allergy to conclude that a confirmed allergy was not present in any of the cases but rather most reactions were of a psychogenic origin.⁴

Of the components that may be present in dental local anaesthetic cartridges, it is reported that the most likely allergen is the preservative metabisulphite which is added to a number of formulations.² Metabisulphite is added as an antioxidant to formulations that contain a vasoconstrictor, adrenaline.³ Therefore, if patients have a true hypersensitivity to sulphite preservative it is best to avoid local anaesthetic with a vasoconstrictor not because of the adrenaline but because of the metabisulphite added to the formulation.³ Recently, there has been a case report in the literature of a confirmed allergy to ethylenediaminetetraacetic acid (EDTA) in local anaesthetic administered s.c.⁵ Historically, there has been a theoretical but not clinically significant risk of latex allergy due to the latex plunger and diaphragm in the cartridge reported.² Latex allergy is no longer a concern, with administration of local anaesthetic solutions as those available in Australia are now manufactured and packaged as part of a 100% latex-free process.^{6,7}

In cases where a true allergy to the local anaesthetic agent is present, it is most commonly a reaction to the common metabolic product of ester local anaesthetics called para-amino benzoic acid. As this is a common metabolite, cross-reactivity between different esters occurs and an allergy to one ester eliminates the possibility of the use of another.^{3,8} Allergic reactions to amide dental local anaesthetics are exceedingly rare and, in contrast to esters, an allergy to one amide does not necessarily rule out the use of another (Table 1).³

Once an adverse reaction occurs in the dental office, it is important that its cause is thoroughly examined. Although a true allergy to local anaesthetic is rare, thorough investigation and accurate diagnosis can protect the patient from a future severe, potentially life-threatening event.⁸ On the other hand, investigation may also allow for the identification of allergy to preservatives, latex or a physiological/psychogenic manifestation that might have led to the observed reaction.⁸ The following case report presents the diagnosis and management of an allergy to an amide local anaesthetic in a paediatric dental patient.

Case Report

A 16 year old male was referred to the Department of Paediatric Dentistry for comprehensive dental examination and dental involvement in his allergy testing by the Department of Allergy and Clinical Immunology at the Women's and Children's Hospital in North Adelaide. The patient had the chief complaint of a history of reactions following dental treatment on two occasions 3 years prior. The first reaction occurred approximately 10 min following administration of mepivacaine (Scandonest 2% Special; Septodont, Lancaster, PA, USA) local anaesthetic. The patient developed reddening of the face and itching around the neck, elbows and ankles. He waited in the dental surgery waiting room for 15 min post-treatment and recovered uneventfully. The second reaction occurred 2 weeks later following administration of mepivacaine (Scandonest 3% Plain; Septodont). The reaction was

noted to be similar to that described in the first instance but of a more immediate onset. On both occasions, latex gloves were used and a mouthrinse peri-procedurally. The restorative material at the first appointment was amalgam, and a Vitrebond (3M ESPE, St Paul, MN, USA) liner and etchant, bond and composite resin for the second restoration. After the above-mentioned reactions, the patient underwent a number of examinations and cleans with latex gloves, peri-procedure mouthrinse and a restoration without local anaesthetic, Vitrebond lining and a glass ionomer cement restoration, all without event. The patient had been seen by a paediatric allergist and clinical immunologist who reported that although allergy to amide local anaesthetic is exceedingly rare, review of the history identified a temporal relationship and thus the possibility needed to be explored. Additionally, other possibilities including latex and chlorhexidine that were more common would also need to be excluded.

The investigation and allergy testing involved a number of steps to eliminate other possibilities and positively identify the allergen as mepivacaine. Scandonest 2% Special, listed in Table 2, has a number of ingredients: mepivacaine, adrenaline, potassium metabisulphite, sodium hydroxide, hydrochloric acid and disodium edetate. However, the reaction also occurred following the administration of Scandonest 3% Plain which as seen contains fewer potential allergens, containing only the active ingredient mepivacaine and sodium chloride, and sodium hydroxide and water.

A specific immunoglobulin (Ig)E blood test for both chlorhexidine and latex was organized and a medical day unit admission arranged for skin prick test with Scandonest 3% Plain neat followed by intradermal testing with a 1:10 dilution as per the European Network on Drug Allergy (ENDA) and European Academy of Allergy and Clinical Immunology (EAACI) Drug Allergy Interest Group guidelines.⁹ A skin test for chlorhexidine, latex extract and a latex prick through a glove was also arranged. All skin tests were negative; however, there was a positive intradermal test with 1:10 dilution with Scandonest 3% Plain resulting in the development of a greater than 18-mm wheal 20 min after administration. Due to the confirmed reaction, subcutaneous testing did not proceed. There was a lack of reaction to all latex and chlorhexidine tests performed.

Following this testing, discussions were had between the Department of Allergy and Clinical Immunology and Department of Paediatric Dentistry to identify possible alternative local anaesthetics for testing. Allergy to a number of different amide local anaesthetics has been reported in cases of mepivacaine allergy. Currently in Australia, all injectable local anaesthetics commonly used in dentistry are of the

Table 1. Local anaesthetics are classified chemically as either esters or amides

Esters	Amides
Butacaine	Articaine
Benzocaine	Bupivacaine
Chloroprocaine	Dibucaine (cinchocaine)
Cocaine (methylbenzoylcegonine)	Etidocaine
Hexylcaine	Lignocaine (lidocaine)
Piperocaine	Mepivacaine
Procaine	Prilocaine
Propoxycaine	Ropivacaine
Tetracaine (amethocaine)	

Modified from Malamed¹⁰ and Thyssen *et al.*¹⁷

Table 2. Local anaesthetic solutions and adjuvants contained in the formulas utilized in this testing process

Solution	Anaesthetic agent	Adjuvant		
		Adrenaline	Potassium metabisulphite	Disodium edetate (EDTA)
Scandonest 3% Plain	Mepivacaine (amide)	(-)	(-)	(-)
Scandonest 2% Special	Mepivacaine (amide)	(+) 1:100 000	(+)	(-)
Lignocaine 1% neat (supplied by pharmacy)	Lignocaine (amide)	(-)	(-)	(-)
Bupivacaine 0.5% neat (supplied by pharmacy)	Bupivacaine (amide)	(-)	(-)	(-)
Lignospan 2% Special	Lignocaine (amide)	(+) 1:80 000	(+)	(+)
Marcaine adrenaline 0.5%	Bupivacaine (amide)	(+) 1:200 000	(+)	(+)

amide variety. Articaine is unique in its molecular structure as it is the only amide local anaesthetic that contains the thiophene group and is the only widely used amide that also contains an ester group.¹⁰ Testing of each alternative agent required admission to the medical day unit for half a day on separate occasions. To minimize the number of admissions, it was decided that two alternatives that had been tested and shown not to cause a reaction would be sufficient. As our testing was limited, it was decided it would be best from a holistic point of view to test two local anaesthetic agents that are widely available and utilized in a number of surgical settings. Lignocaine and bupivacaine, both of the amide variety, are local anaesthetics commonly used in surgical procedures across a number of dental and general surgical disciplines. Therefore, it was decided that it was most practical to test lignocaine and bupivacaine as potential local anaesthetic alternative options.

Medical day unit admission was arranged for intradermal 1:100 dilution, 1:10 dilution and neat of lignocaine 1% plain and 0.5% bupivacaine plain, and subcutaneous challenge testing of neat lignocaine 1% plain and 0.5% bupivacaine plain. All tests failed to show any evidence of an allergic reaction to either agent. Therefore, the final step was to perform intraoral challenge with both alternative local anaesthetics. Two further medical day unit admissions were arranged to allow for lignocaine and bupivacaine intraoral testing each on separate occasions. It was decided to test the formulations as they would be used in the clinical setting. Thus, on the first occasion 0.1 mL 2% lignocaine with 1:80 000 adrenaline formulation containing lignocaine hydrochloride, adrenaline, sodium chloride, potassium metabisulphite, disodium edetate and sodium hydroxide was tested. The first test involved injection of 0.1 mL in the right maxillary vestibule. The patient was observed for 30 min following this administration and there was no evidence of a reaction. Therefore, the second test which involved injection of 0.5 mL in the left maxillary vestibule, was performed again with no reaction for the following 30 min. Therefore, the third and final lignocaine test was completed which involved injection of 1.5 mL of 2% lignocaine with 1:80 000

adrenaline as an infiltration in the right vestibule. The patient was closely observed in the medical day unit for 3 h post-administration and there were no local or systemic signs or symptoms of an allergic reaction. On a separate occasion 2 weeks following this challenge, the same process was repeated to test 0.5% bupivacaine with 1:200 000 adrenaline, containing bupivacaine hydrochloride, epinephrine bitartrate, sodium metabisulphite, monothioglycerol, ascorbic acid, sodium lactate buffer, edetate calcium disodium, sodium hydroxide and hydrochloric acid, was completed and again no evidence of a reaction was observed. The conclusion of this testing was that both lignocaine and bupivacaine +/- adrenaline formulations were a safe alternative local anaesthetic for this patient.

The patient required four dental restorations; thus, following completion of the allergy testing and successful challenge in the medical day unit, dental restorations were scheduled on three different occasions in the Department of Paediatric Dentistry. These appointments were carried out with 2% lignocaine, 1:80 000 adrenaline administered as maxillary and mandibular buccal infiltrations, and inferior alveolar and lingual block as appropriate. Rubber dam, latex gloves, and amalgam and composite resin restorations were all used without event. The patient was discharged to his local dentist for ongoing general dental management with a detailed handover of his mepivacaine allergy and tolerance to both lignocaine and bupivacaine which are both suitable local anaesthetic alternatives. The patient also wears a medical alert bracelet with details of his allergy.

The above case describes the process of positively identifying an allergen responsible for an allergic reaction in the dental office. It also explains the process of identifying and testing a suitable alternative to allow for the provision of safe routine dental treatment. This process from the point of referral to the outcome and discharge is summarized in Figure 1.

DISCUSSION

The administration of local anaesthetic to facilitate dental treatment is a very common procedure. There

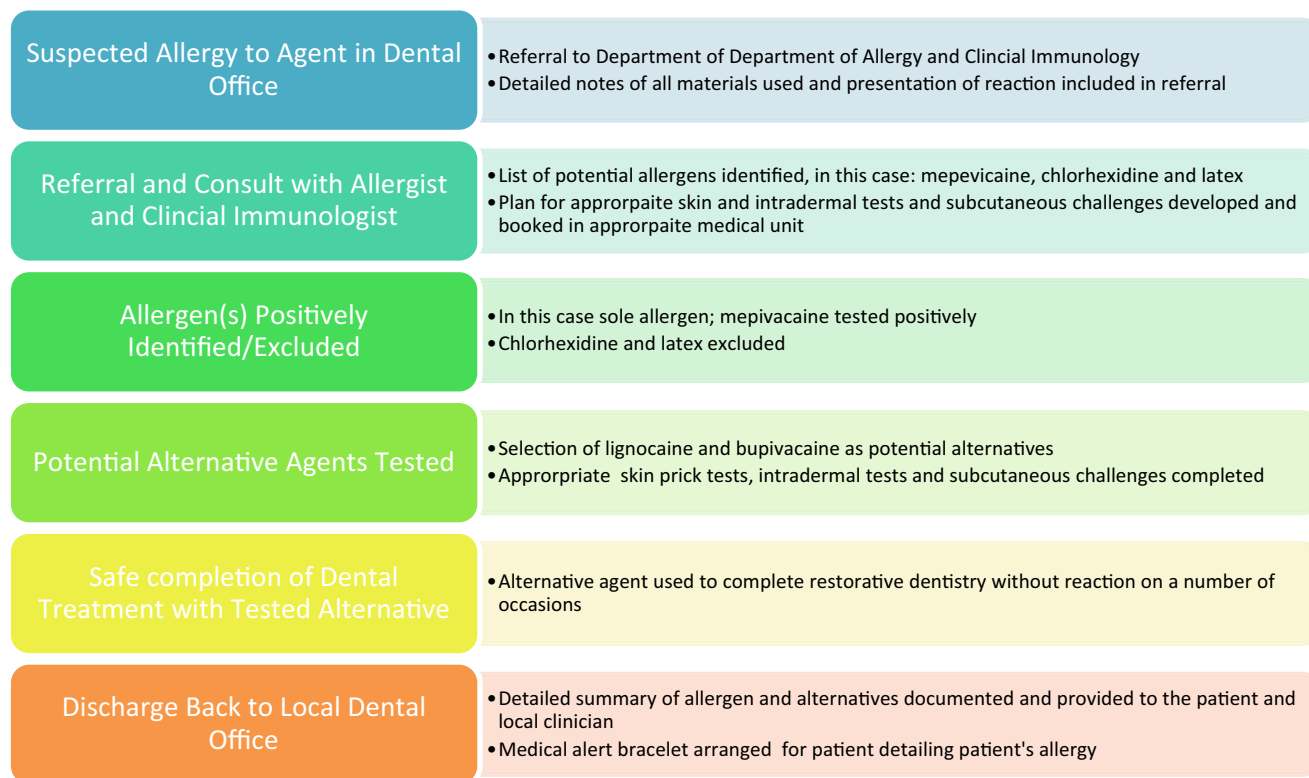


Fig. 1 Flowchart summarising the referral, testing, diagnosis and discharge process for the patient with the confirmed local anaesthetic allergy.

are a number of adverse reactions that can occur somewhat commonly following the administration of local anaesthetic in the dental setting.⁴ However, despite frequent explanations from patients that they are allergic to local anaesthetics, true allergy, particularly to amide local anaesthetics, is exceedingly rare.^{2,4} Rood completed skin and intraoral challenges of 44 adult patients suspected of having a local anaesthetic allergy to conclude that a confirmed allergy was not present in any of the cases but rather most reactions were of a psychogenic origin.⁴ Gall *et al.* also reported on a similar series of patients with assessment of 43 adult patients who had all reported a mepivacaine allergy over a 10-year period being tested with skin, intradermal and challenge testing.¹¹ Only one of these patients had a confirmed mepivacaine allergy in this time period, demonstrating how rare a confirmed allergy to dental local anaesthetic is.¹¹

There are a number of guidelines that can be referred to when looking to confirm or discount a patient's allergy to a local anaesthetic. A Standards of Care Committee of the British Society for Allergy and Clinical Immunology (BSACI) described processes of investigation of suspected anaphylaxis during a general anaesthesia. It is explained that due to the rarity of a true local anaesthetic allergy, it has not been possible to validate skin prick tests and intradermal testing.¹² Therefore, after such tests it is recommended to

proceed to incremental subcutaneous challenge as required/appropriate.¹²

In this case report, skin prick testing with mepivacaine was negative and thus the testing progressed to intradermal skin testing. A negative skin prick test is a common finding in cases of local anaesthetic allergies as reported by Germishuys.¹³ Germishuys observed in a population of 104 patients, 64 of whom had positive diagnosis of contact dermatitis with the caine mix and 12 had positive intradermal skin testing results to local anaesthetics, there were no positive results for skin prick testing. The intradermal skin test was completed at a concentration of 1:10 as recommended by the ENDA and EAACI Drug Allergy Interest Group guidelines.⁹ There is a very low risk of anaphylaxis after i.d. injection at this concentration and 1:10 dilutions of local anaesthetic have been shown to be non-irritant.¹³ The patient had a positive reaction to intradermal testing with mepivacaine and thus there was no subcutaneous testing with this agent. However, during the process of identifying an appropriate alternative, there was incremental subcutaneous challenge completed with 1:100, 1:10 and then neat formulations of the alternative agents. As was done in this case, it is important that neat lignocaine is used because intradermal testing with local anaesthetic containing vasoconstrictors can mask the local wheal and flare reaction. Additionally, a number

of excipients that may be in the local anaesthetics such as bisulphites and EDTA have been reported to cause anaphylaxis.^{5,9}

There are case reports in the literature of a 35 year old woman and 14 year old male who also tested positively to mepivacaine sensitivity but had tolerance to and demonstrated no reaction to lignocaine or bupivacaine.^{14,15} Sharma *et al.* claimed this to be the first paediatric case of an allergy to mepivacaine reported in the literature.¹⁵ The importance of testing for a suitable alternative local anaesthetic is highlighted in a case report of mepivacaine allergy occurring in the presence of reactions to other amide local anaesthetics such as lignocaine and ropivacaine.¹⁶

CONCLUSIONS

Immediate IgE-mediated allergy to local anaesthetic, as was observed in this case, is rare. However, in cases where an allergy is suspected it is important that they are fully investigated due to the risk of the patient developing anaphylaxis.¹⁵ This case highlights the importance of early referral and thorough investigation in cases where an allergy to a local anaesthetic is suspected. The investigative process that eliminates other potential reactions and allergens is discussed through to identifying and testing appropriate alternatives for tolerance to conclude with alternative local anaesthetic options that have been challenged for clinical safety.

REFERENCES

1. Sambrook PJ, Goss AN. Severe adverse reactions to dental local anaesthetics: prolonged, mandibular and lingual nerve anaesthesia. *Aust Dent J* 2011;56:154–159.
2. Sambrook PJ, Smith W, Elijah J, Goss AN. Severe adverse reactions to dental local anaesthetics: systemic reactions. *Aust Dent J* 2011;56:148–153.
3. Hass DA. An update on local anaesthetics in dentistry. *Can Dent Assoc* 2002;68:546–551.
4. Rood JP. Adverse reaction to dental local anaesthetic injection – “allergy” is not the cause. *Br Dent J* 2000;189:380–384.
5. Russo PA, Banovic T, Wiese MD, Whyte AF, Smith WB. Systemic allergy to EDTA in local anaesthetic in radiocontrast media. *J Allergy Clin Immunol* 2014;2:225–230.
6. 3M Australia Pty Limited, 3M Espe Local Anaesthetics. Frequently asked Questions. page 8 Available at: http://www.gunz.com.au/files/documents/Ubistesin%20FAQ%20Booklet%20AU_0.pdf, Accessed 17 January 2017.
7. Septodont Health Care, Categories and Products. Pain Management: Injectable Anaesthetics. Available at: <http://www.septodont.co.uk/products>, Accessed 17 January 2017.
8. Jenerowicz D, Polanska A, Glinska O, Czarnecka-Operacz M, Schwartz RA. Allergy to lidocaine injections: comparison of patient history with skin testing in 5 patients. *Adv Dermatol Allergol* 2014;31:134–138.
9. Brockow K, Garvey LH, Aberer W *et al.* Skin test concentrations for systemically administered drugs – an ENDA/EAAACI drug allergy interest group position paper. *Allergy* 2013;68:702–712.
10. Malamed SF. *Handbook of local anaesthesia*. St. Louis: Elsevier Mosby, 2004.
11. Gall H, Kaufmann R, Kalveram CM. Adverse reactions to local anaesthetics: analysis of 197 cases. *J Allergy Clin Immunol* 1996;97:933–937.
12. Ewan PW, Dugue P, Mirakian R, Dixon TA, Harper JN, Nasser SM. BSACI guidelines for the investigation of suspected anaphylaxis during general anaesthesia. *Clin Exp Allergy* 2009;40:15–31.
13. Germishuys PJ. Intradermal testing of patients with putative allergic reactions to local anaesthetics – analysis of 611 cases. *Curr Aller Clin Immunol* 2004;40:28–31.
14. Prieto A, Herrero T, Rubio M, *et al.* Urticaria due to mepivacaine with tolerance to lidocaine and bupivacaine. *Allergy* 2005;60:261–262.
15. Sharma V, Harper NJN, Garcez T, Arkwright PD. Allergic reaction to mepivacaine in a child. *Br J Anaesth* 2013;110:1059–1060.
16. Gonzalez-Delgado P, Anton R, Soriano V, Zapater P, Niveiro E. Cross-reactivity among amide-type local anaesthetics in a case of allergy to mepivacaine. *J Investig Allergol Clin Immunol* 2006;16:148–153.
17. Thyssen JP, Menne T, Elbering J, Plaschke P, Johanssen JD. Hypersensitivity to local anaesthetics – an update and proposal of evaluation algorithm. *Contact Dermatitis* 2008;59:69–78.

Address for correspondence:

Dr Gabrielle Allen

Dental Fellow

Department of Paediatric Dentistry

72 King William Road

North Adelaide, SA 5006

Australia

Email: gabrielle.j.allen@gmail.com