



Jawaad Ahmed Asif



Paras Ahmad and Tahir Yusuf Noorani

A Sialolith and a Megalith: a Report of Two Cases

Abstract: Sialolithiasis is considered as one of the most frequently encountered diseases of the salivary glands. The most susceptible site is the submandibular gland and its duct. However, megaliths have been sparsely reported in the literature. This article portrays management of a sialolith and a megalith in a 26-year-old and a 59-year-old male patient, respectively. The sialolith in the first case case was 4 mm long, whereas the second case demonstrated a megalith measuring 46 mm at its greatest size. Follow-up revealed normal functioning and a painless gland in the first case, while the second case showed no eventful complications. It is interesting to know that both patients remained relatively pain-free, despite having such longstanding sialolith/megaliths. After removal of the small sialolith, the gland regained its normal functioning swiftly, whereas in the case of the megalith, the gland removal was mandatory because such a longstanding megalith led to irreversible functional injury to the gland.

CPD/Clinical Relevance: A giant sialolith can be easily misdiagnosed as a submandibular infection or neoplasm, especially when the patient presents with a longstanding pain-free swelling. Hence, early and appropriate referral and investigation is necessary for early diagnosis and treatment.

Dent Update 2020; 47: 71–74

Sialolithiasis refers to a pathological condition that arises due to partial or complete obstruction of the salivary gland or its associated duct by a calculus or a stone.¹ These calculi or stones organize and mineralize around a nucleus of debris consisting of bacterial colonies, mucus plugs, shed ductal epithelial cells and foreign bodies.² After mumps, it is the most frequently encountered disease of the major salivary glands.³ The typical presentation of

sialolithiasis is painful swelling of the involved salivary gland, which is intensified during mealtimes. Although salivary flow is constant, it increases 10-fold during meals. This sudden increase in saliva production and flow causes severe pain, even in a partially obstructed salivary gland and/or duct. However, most salivary calculi/stones are painless.¹ The most usual site of their occurrence is Wharton's duct or a submandibular duct due to alkalinity and viscosity of saliva, higher quantity of mineral salts, such as calcium, and a tortuous ductal course. Wharton's duct exhibits the highest incidence of sialolithiasis, followed by Stensen's duct, and the least incidence is seen in Bartholin's duct.⁴ Although sialoliths can be found in any age, the peak incidence is in the 4th to 6th decade of life. Males have a slightly higher predilection than females, with a ratio of 5.5:4.5.¹ Sialoliths measuring 5–10 mm in size are considered normal, whereas sialoliths larger than 10 mm are designated as unusually sized sialoliths. Giant sialoliths or megaliths detected in the Wharton's duct measuring ≥ 3.5 cm have been

categorized as a rare presentation. According to the literature, only 29 such cases have been reported over the past 22 years.^{1,4} The aim of this paper is to report clinical and radiographic presentation of two contrasting cases of sialolithiasis.

Case 1

A 26-year-old male nurse attended the oral and maxillofacial surgery clinic with a history of a stone-like sensation under the left side of his tongue for 7 years. This unpleasant feeling was aggravated by tongue movement. However, there was no complaint of pain, even during meals. He was healthy with no medical illnesses but consumed multivitamins and ginkgo as supplements. Although he was a moderate smoker, he had quit smoking six months prior to his presentation and, more recently, had developed a habit of frequently sipping water while having dry foods due to thick and frothy saliva.

Extra-orally there was no swelling, or any form of abnormality detected. On

Jawaad Ahmed Asif, BDS, MOMS, FRACDS, Senior Lecturer, Oral and Maxillofacial Surgery Unit, **Paras Ahmad**, BDS, MSc, Postgraduate Student, Oral Medicine Unit, **Tahir Yusuf Noorani**, DDS, MResDent, FRACDS, Senior Lecturer, Conservative Dentistry Unit (dentaltahir@yahoo.com), School of Dental Sciences, Universiti Sains Malaysia, Health Campus, 16150 Kubang Kerian, Kota Bharu, Kelantan, Malaysia.

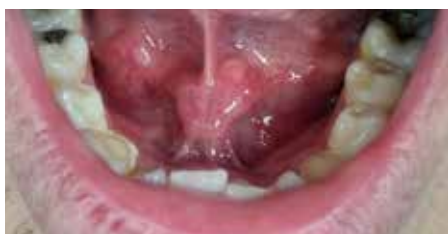

Figure 1. Case 1: A calcified mass immediately adjacent to the lingual frenum on the left side.

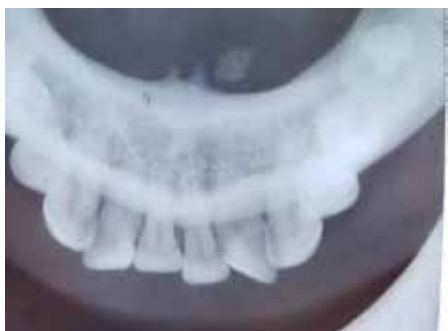

Figure 2. Case 1: A lower occlusal radiograph showed a nodular radio-opacity at the left lingual aspect of anterior mandible.

intra-oral examination, a crenated tongue on the left and right lateral border was noticed. On bi-digital palpation, a calcified mass was felt immediately adjacent to the left side of the lingual frenum (Figure 1). No other abnormality was detected and oral hygiene, as well as dental condition, was fair. A lower occlusal radiograph showed a nodular radio-opacity measuring roughly 1.5 mm × 4 mm at the left lingual aspect of the anterior mandible (Figure 2).

The diagnosis of a left submandibular sialolith was established and the patient was scheduled for removal of the sialolith. On the day of the appointment, written consent was taken after explaining the possible complications, which included bleeding, ductal injury, infection and recurrence. Local anaesthesia (2% mepivacaine with adrenaline) was infiltrated and a Bowman Lacrimal Probe (size 3) was used to access and protect the Wharton's duct. A stay suture was placed around the proximal end of the probe using 3/0 silk. The sialolith was palpated and a superficial incision was made over the sialolith using a BP blade no. 15, followed by blunt dissection, and the sialolith was removed (Figures 3 and 4). The silk suture was removed, and patency of the duct was examined, which appeared to be normal. The extracted sialolith measured 4 mm in length and 1.5 mm in width. Post-operative

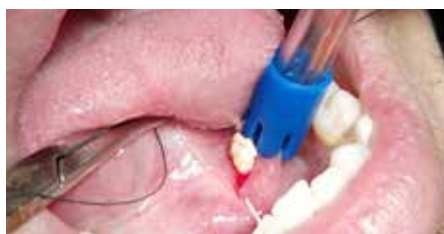

Figure 3. Case 1: Submandibular sialolith being removed.

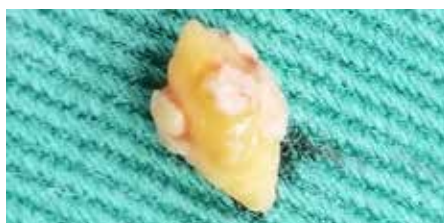

Figure 4. Case 1: Extracted submandibular sialolith measuring 1.5 mm × 4 mm.

instructions were given to the patient. The patient was advised to consume citrus drinks to stimulate salivary flow. Chlorhexidine (0.2%) 15 ml bid 2/52 and Tab Paracetamol 1000 mg PRN 3/7 were prescribed.

Case 2

A 59-year-old male attended the emergency department with a chief complaint of severe pain over the right side of his neck. He was diagnosed with hypertension which was well controlled with medication. He was a chronic smoker (20 cigarettes/day). History revealed that the presenting complaint started as a pea-sized lump on the right side of his neck which persistently increased in size over 8–9 years. Furthermore, the patient noticed a mass in his oral cavity during the last 6 years but did not consult a physician. However, he was alerted when the lump started growing rapidly in a span of two weeks, which aggravated the pain and caused dysphagia. Extra-oral clinical examination revealed a multilobulated mass measuring 5 cm x 6 cm on the right side of the patient's neck, extending from the infra-auricular region to 2 cm above the clavicle, which was hard in consistency. The patient was initially misdiagnosed as having a submandibular infection and was prescribed antibiotics in the emergency department. When the swelling persisted, the patient was referred to the otolaryngology department, where a diagnosis of a submandibular tumour was established before the patient was referred to

the oral and maxillofacial surgery department.

Upon examination by the oral surgeon, intra-orally, a dark cauliflower-like growth measuring 4 × 4 cm was noticed in the retromolar trigone (Figure 5). The mass initially appeared as a necrotic bone. The patient's overall oral hygiene was poor, and discoloration of the soft palate was seen. Further investigation with OPG and CT showed a giant nodular radio-opacity measuring 4.61 cm × 2.53 cm in the aforementioned region (Figures 6 and 7).

A diagnosis of right submandibular sialolithiasis was established and the patient was scheduled for the removal of the giant sialolith or megalith under general anaesthesia. An intra-oral incision posterior to the LR8 was made and a flap was raised using a periosteal elevator. The megalith was gently removed using Allis forceps (Figure 8). Peri-operatively, the right submandibular gland appeared fibrosed and atrophied. The gland was removed via right submandibular incision. All the incisions were sutured appropriately, with a negative pressure drain placed *in situ* (extra-orally), which was removed after 24 hours as there was minimal collection. Post-operative recovery was uneventful. The patient was recalled two weeks post-operatively to assess the surgical site. On check-up, no sign of infection was detected.

Discussion

The cases that are reported in this article are unusual in nature, because they do not coincide with the conventional data present in the literature. Firstly, the novelty of this case report is evident from the fact that sialolithiasis is mostly characterized by painful swelling of the associated gland but, in the aforementioned cases, the patients remained pain-free for over an average period of 6 years. Secondly, pain during mealtimes is one of the touchstones for the establishment of diagnosis of sialolith, however, in Case 1, the patient was pain-free even during mealtimes. Thirdly, the mammoth-sized submandibular sialolith reported in Case 2 is not common in the literature. Only a few studies have reported a sialolith bigger than the sialolith mentioned in Case 2. Fourthly, this case report highlights the importance of proper diagnosis. A dentist/physician can easily confuse a submandibular sialolith with a mandibular torus or osteoma, calcified

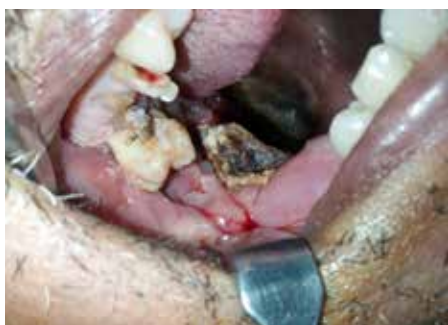

Figure 5. Case 2: A dark cauliflower-like growth appearing as necrotic bone in the retromolar trigone.

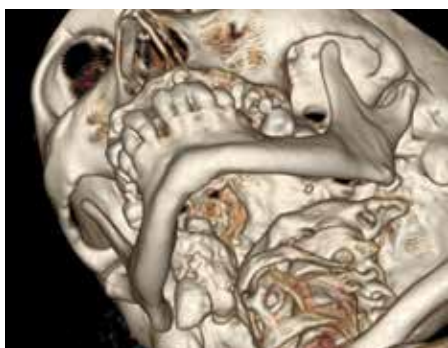


Figure 7. Case 2: A 3D-CT showing a multi-lobulated mass on the right side of the neck extending from infra-auricular region to 2 cm above clavicle.

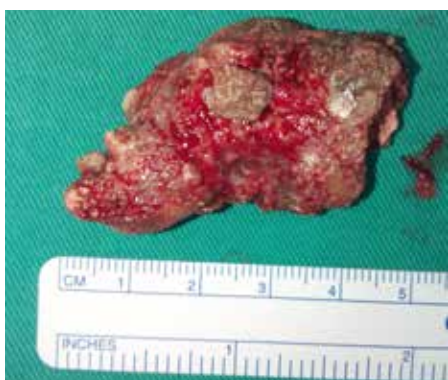

Figure 8. Case 2: Giant submandibular sialolith (megalith) after the removal measuring 4.61 cm x 2.53 cm.

lymph nodes, tuberculosis of salivary gland, myositis ossificans, or metastasis from distinct calcifying neoplasms. In Case 2, the patient was initially misdiagnosed as a submandibular tumour by the otolaryngology department. But, after thorough investigation by an oral and maxillofacial surgeon, final and correct diagnosis was established, ie a submandibular sialolith. This reflects that the role of dentist



Figure 6. Case 2: Orthopantomogram (OPG) showing giant nodular radio-opacity near right angle of mandible.

is as crucial as that of a physician in such cases. Healthcare providers associated with medicine and dentistry should liaise with each other when such cases are reported in hospitals or clinics.

For a patient experiencing pain and swelling of a salivary gland, neoplastic, infectious, granulomatous and inflammatory aetiologies should be considered.⁵ In a 13-year research study, Kenefick concluded that 35% of patients experiencing salivary gland disorders were having sialolithiasis.⁶ Stones may form without any related glandular pathology, but also form in the majority of patients suffering from chronic sialadenitis. The only systemic condition associated with sialolithiasis is gout, in which the calculi are composed of uric acid.⁷ It is imperative for a clinician to rule out other diagnoses that may be present with submandibular calcifications, especially when there is no pain. Among these are phleboliths associated with facial/oral hemangiomas, mandibular osteoma occurring in Gardner's syndrome, and calcified lymph nodes associated with mycobacterial adenitis.⁸

Several imaging techniques play a vital role in successful diagnosis of sialolithiasis. Ultrasonography (US) is regarded as the first-line imaging modality because it is non-invasive, inexpensive and readily available.⁹ Moreover, it does not have any radiation exposure.¹⁰ According to Jäger *et al*,¹¹ the sensitivity of US in the detection of sialolithiasis is 59.1%–93.7%, while having specificity equal to 86.7%–100%. Conventional intra-oral radiography is considered to be more effective than extra-oral X-rays, especially trans-occlusal end-oral radiography. Sialography is also considered an adequate imaging modality that permits the whole duct system to be visualized after injecting either water soluble (like renografin) or fat soluble contrast media (like ethiodol). However, it is contra-indicated if the patient is sensitive to contrast medium or has

an acute infection. Scintigraphy can also be utilized when sialography is contra-indicated, or when glandular ducts are non-permeable. Sialoendoscopy is another technique of directly visualizing intra-ductal calculi, which has largely replaced the old gold standard sialography. However, it is contra-indicated in instances where the ductal system is extremely tortuous.¹² Other modalities, like digital subtraction sialography and high-resolution ultrasonography, have also been recommended for the evaluation of salivary gland disorders. Computerized tomography (CT) is performed only if the stone is large, or if radiological slices need to be visualized in every millimetre. Its limitations include, inability to localize the salivary stone precisely and lack of visualization of the ducts and their anomalies.¹³ In the cases discussed, a lower occlusal radiograph, OPG and CT were used for diagnostic purposes.

Various treatment modalities can be used for the removal of sialoliths, depending on their size and location. They can be removed either by invasive procedures or by minimally invasive techniques. An intra-oral approach is recommended when the calculi can be palpated intra-orally. If the stone is small and located sufficiently forward in the duct, it can be 'milked out' through the duct orifice by bimanual palpation. However, in the case of medium- or large-sized stones, surgical removal becomes mandatory. Newer, minimally invasive treatment methods include intra-corporeal lithotripsy, StoneBreaker or extra-corporeal shockwave lithotripsy, and basket retrieval. These are impressive alternatives to surgical excision for sialoliths smaller than 7 mm. Lithotripsy is the fragmentation of salivary stones into smaller pieces so that they can be easily flushed out from the salivary duct system immediately or after salivation, induced by citric acid or other sialagogues.

Extra-corporeal Shock Wave Lithotripsy (ESWL) is regularly used for fragmentation of kidney stones. This method is now implemented in the fragmentation of salivary gland sialoliths. It uses electromagnetic waves with a pulse frequency of 0.5–2 Hz, which create acoustic radiation and cause fragmentation of the sialolith.¹⁴ However, it is relatively contra-indicated in ductal stenosis and pregnancy. It is absolutely contra-indicated in patients with cardiac pacemakers.¹⁴ The basket retrieval technique is another method which is usually utilized when the stone is less than 5 mm. This technique can be used in conjunction with ultrasound¹⁵ or sialoendoscopy.¹⁶ Sialoendoscopy is helpful in the detection and treatment of ductal pathologies using 0.9–1.6 mm diameter semi-rigid endoscopes. These endoscopes have the provision for various attachments, such as grasping forceps, micro-drills and a flexible wire basket. Micro-drills are used for the fragmentation of larger sialoliths. Alternatively, a wire basket is carefully pushed past the stone under endoscopic monitoring and then opened (as an umbrella) which engulfs the stone and assists in the safe retrieval of the stone. Endoscopically-controlled, intra-corporeal lithotripsy includes:

- Intra-corporeal electro-hydraulic lithotripsy;
- Electro-kinetic lithotripsy;
- Intra-corporeal laser lithotripsy; and
- Pneumatic lithotripsy.¹⁴

Most of these techniques use a kinetic or ballistic approach, which imposes a high risk of tissue trauma or perforation. However, for megaliths, trans-oral sialolithotomy with sialadenectomy or sialodochoplasty remains the backbone of management.¹

Intra-glandular sialoliths and longstanding obstructions can cause severe damage to the gland, resulting in a decrease or complete absence of salivary flow. This leads to recurrent infections which mandates complete removal of the gland along with the sialolith,^{17,18} as was undertaken in Case 2.

Conclusion

Clinicians should evaluate painless as well as painful swellings in the submandibular area, including sialolithiasis as a possible diagnosis. Once diagnosis is established, the best possible approach for removal should be used to avoid post-operative complications. Early identification and removal of sialoliths is essential to prevent permanent damage and

to re-instate function of the salivary glands.

Acknowledgements

The authors would like to thank the management of the Hospital Universiti Sains Malaysia (HUSM), Kubang Kerian, Kelantan for allowing the use of space and assets belonging to the Hospital during the treatment of the presented case.

Compliance with Ethical Standards

Conflict of Interest: The authors declare that they have no conflict of interest.

Informed Consent: Informed consent was obtained from all individual participants included in the article.

References

1. Saluja H, Kasat VO, Mahindra U. Giant sialolith in the Wharton's duct causing sialo-oral fistula: a case report and review of literature. *J Orofac Sci* 2012; **4**: 137–142.
2. Huang T, Dalton J, Monsour F, Savage N. Multiple, large sialoliths of the submandibular gland duct: a case report. *Aust Dent J* 2009; **54**: 61–65.
3. Rai AJ, Hegde P, Roy S, Sharma J. Submandibular gland sialolithiasis – a case report. *Indian J Appl Res* 2018; **6**: 5–51.
4. Mubashir MM, Negi AK, Sharma VK, Sharma P. A case report of submandibular duct calculus. *Int J Recent Sci Res* 2018; **9**: 28878–28880.
5. Pollack CV, Severance HW. Sialolithiasis: case studies and review. *J Emerg Med* 1990; **8**: 561–565.
6. Kenefick J. Some aspects of salivary gland disorders. *Proc R Soc Med* 1975; **68**: 283–285.
7. Siddiqui S. Sialolithiasis: an unusually large submandibular salivary stone. *Br Dent J* 2002; **193**: 89–91.
8. Karaca Erdoğan N, Altay C, Özenler N et al. Magnetic resonance sialography findings of submandibular ducts imaging. *Biomed Res Int* 2013; **2013**: 417052.
9. Rzymaska-Grala I, Stopa Z, Grala B et al. Salivary gland calculi – contemporary methods of imaging. *Pol J Radiol* 2010; **75**: 25–37.
10. Terraz S, Poletti PA, Dulguerov P et al. How reliable is sonography in the assessment of sialolithiasis? *Am J*

Roentgenol 2013; **201**: W104–W109.

11. Jäger L, Menauer F, Holzknecht N, Scholz V, Grevers G, Reiser M. Sialolithiasis: MR sialography of the submandibular duct – an alternative to conventional sialography and US? *Radiology* 2000; **216**: 665–671.
12. Oteri G, Procopio RM, Cicciù M. Giant salivary gland calculi (GSGC): report of two cases. *Open Dent J* 2011; **5**: 90–95.
13. Marchal F, Dulguerov P. Sialolithiasis management: the state of the art. *Arch Otolaryngol Head Neck Surg* 2003; **129**: 951–956.
14. Capaccio P, Torretta S, Pignataro L, Koch M. Salivary lithotripsy in the era of sialendoscopy. *Acta Otorhinolaryngol Ital* 2017; **37**: 113–121.
15. Drage NA, McAuliffe NJ. Ultrasound-guided basket retrieval of salivary stones: a new technique. *Br J Oral Maxillofac Surg* 2005; **43**: 246–248.
16. Nahlieli O, Shacham R, Bar T, Eliav E. Endoscopic mechanical retrieval of sialoliths. *Oral Surg Oral Med Oral Pathol Oral Radiol Endod* 2003; **95**: 396–402.
17. Mamat MSN, Ibrahim R, Abdullah B. Preservation of lingual nerve in excision of bilateral submandibular sialolith via intraoral approach: a case report. *Int J Human Health Sci* 2018; **2**: 161–163.
18. Yazdani J, Mehr AA, Hashemi M, Abdolahi T, Ahmadpour F. Intraoral surgical management of the multiple giant submandibular sialolithiasis. *Adv Biosci Clin Med* 2018; **6**: 25–28.

Erratum

An Update on Non-Surgical Management of Periodontal Diseases
I Midwood and P Hodge
Dent Update 2019; **46**: 942–951

Table 3 should read:

Step 5. Root surface debridement
Bullet point 7: *After care advice: advise the patient to use pain relief as necessary, and try to clean the teeth as normal after treatment; it may be uncomfortable to use interdental cleaning aids until the following day. For patients who have full mouth treatment in one day, 0.2% chlorhexidine mouthwash (twice per day) may be prescribed until the patient can clean normally.*