

# Submandibular Salivary Stones: Current Management Modalities

Harold D. Baurmash, DDS\*

Salivary calculi are usually unilateral in occurrence and round to oblong, have an irregular (majority) or smooth surface, vary in size from a small grain to the size of a peach pit, and are usually yellow.<sup>1</sup> The stones may occur in the duct or gland, with multiple stones not uncommon. They are found more often in adults, although they also occur in children.<sup>2</sup> The classic symptoms are that of obstruction manifested by pain and swelling of the involved gland during eating (Fig 1). Since obstruction is rarely complete, the gland swelling will subside to some degree during rest periods. In as much as chronic gland obstruction will invariably result in inflammation and fibrosis, some swelling and induration may persist even after stone removal.

Stones apparently develop as a result of an initial organic nidus followed by the deposition of inorganic material, both of which are derived from the salivary fluid. The filamentous stroma or nidus is not bacterial in nature but rather precipitated mucoids and possibly salivary proteins.<sup>3,4</sup> The popular explanation of a precipitation of salts when pH, calcium, and phosphate are sufficiently elevated does not agree with the prevailing concepts of calcification elsewhere in the body. The concentration of calcium in saliva is not high enough to precipitate spontaneously, but as Mandel<sup>3</sup> stated, "The matrix provides the architectural template or geometric configuration of the initial apatite crystal." It is therefore clear that salivary stasis and salivary viscosity, rather than the calcium content of the individual salivary gland secretion, play the significant role in its development.

Submandibular sialoliths are more common than those of the parotid for a number of reasons. Anatomically, the submandibular duct is longer than the parotid, traversing upward and forward from the gland to the oral floor, whereas Stensen's duct moves in a

horizontal direction. In addition, there is diminution in the calibre of Wharton's duct with a corresponding decrease in wall thickness compared with the parotid.<sup>5</sup> One might also expect that the overlying muscles of facial expression would aid, to some extent, parotid salivary flow. Salivary stasis is also facilitated by the fact that the orifice of Wharton's duct is much narrower than that of Stensen's duct (Fig 2A). There is one other region in the submandibular duct that is conducive to salivary stasis, and the "comma area," where the duct takes a radical turn inferiorly behind the posterior border of the mylohyoid muscle as it approaches the hilus of the gland (Fig 2B). Regarding salivary viscosity, submandibular saliva is more than twice that of the parotid because of its mucus content.

## Submandibular Sialoliths

### RADIOGRAPHIC EXAMINATION

The occlusal radiograph is the most reliable method of viewing the submandibular sialolith, but the surgeon should be aware that with the standard view (Fig 3A), the region visualized is limited posteriorly to the second molar. The posterior fourth of the duct, which includes the comma area to the hilus and body of the gland, can be visualized only by placing the x-ray cone posterior to the gland and directing it in an upward, anterior, and slightly medial direction (Fig 3B). The two views are mandatory because the conventional view may miss a stone in the posterior region (Fig 3C) and at times multiple stones may be portrayed as single stones, one on each radiographic view (Fig 3D).

Lateral plate radiographs are effective only with stones in the submandibular gland that project below the inferior border of the mandible (Fig 4). The problem with small to medium-sized stones is that if they are poorly calcified, they will be masked by the bone's density, and if they are well calcified, they may be mistaken for bone whorls or enostoses. This limitation also applies to panoramic radiographs but with an additional problem. A single large sialolith in the anterior portion of the duct may mistakenly appear as bilateral stones (Figs 5A, B).

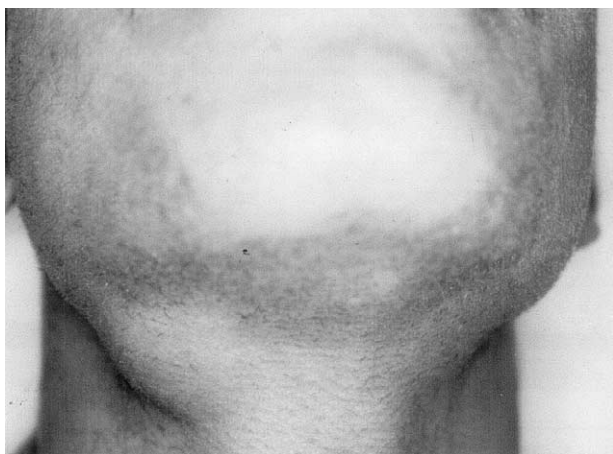
\*Retired Clinical Professor, Columbia University, School of Dental and Oral Surgery, New York, NY.

Address correspondence and reprint requests to Dr Baurmash: 4666 Hazleton Lane, Lake Worth, FL 33467; e-mail: HaLi2533@aol.com

© 2004 American Association of Oral and Maxillofacial Surgeons

0278-2391/04/6203-0014\$30.00/0

doi:10.1016/j.joms.2003.05.011



**FIGURE 1.** A large submandibular salivary gland swelling resulting from obstruction by a small sialolith at the orifice of Wharton's duct.

The 2 occlusal radiographs will provide the best diagnostic views of the complete duct and gland system, but one must be aware that some situations may act to restrict stone visualization. Small anterior stones may be hidden by the superimposition of lingual surface of the mandible, and an alteration of the angle of the x-ray cone may be necessary. Some stones may be masked by accumulations of pus intraductally (Figs 6A, B), and by the same token inflammation around the ductal orifice may simulate a poorly calcified stone. In addition, poorly calcified stones may be masked by the tongue musculature. If palpation of the area is unsatisfactory, a sialogram may be necessary.

On occasion, a calcified submandibular lymph node may be confused with a sialolith; the sialogram will clearly differentiate the two (Fig 7). Furthermore, because the lymph nodes are anterior to the submandibular salivary gland, one should be suspicious when a calcification is projected significantly anterior when using the posterior/anterior view occlusal radiograph. The surgeon should also be aware of another situation

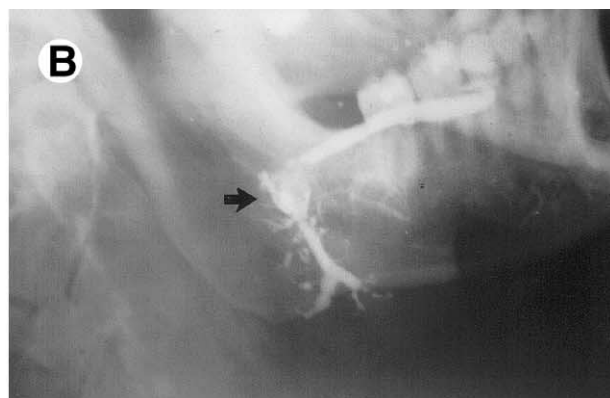
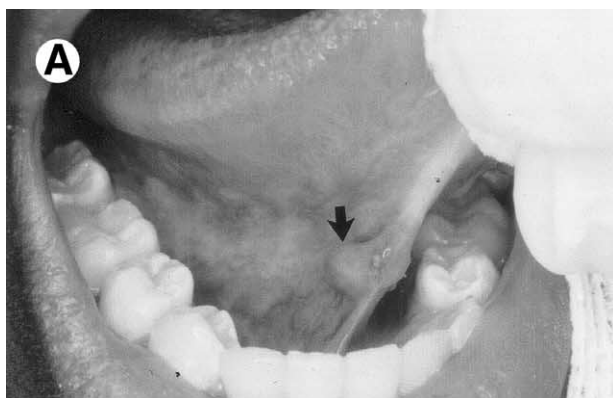
that may be confused with sialoliths—phleboliths. The presence of a soft swelling with or without a purplish discoloration should suggest the possibility of a vascular malformation. Again, the sialogram will provide a positive answer.

#### SUBMANDIBULAR DUCT AND GLAND SIALOLITHOTOMY

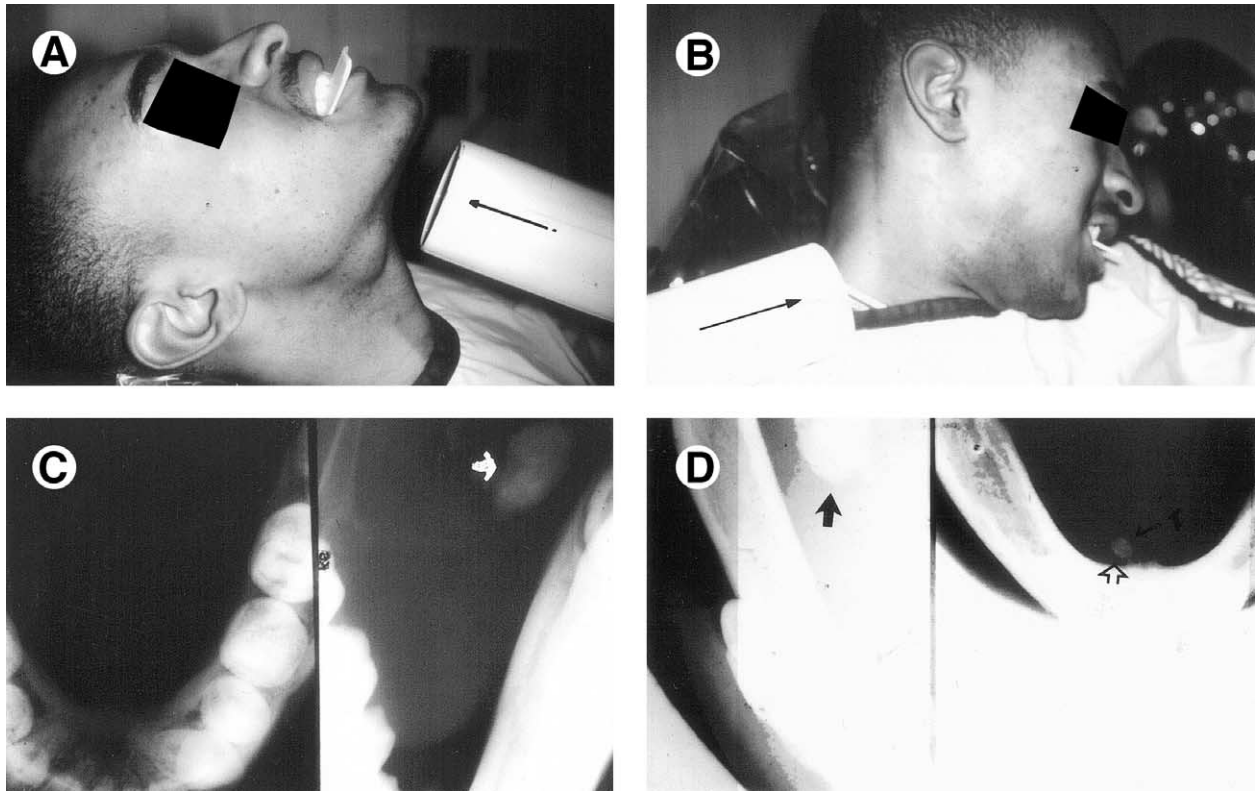
The majority of stones develop and enlarge in size but remain fixed in their original position. This occurs because of the irregularly shaped surface, combined with the inflammation and fibrosis of the duct wall surrounding it. However, the practitioner should be aware that at times he or she will encounter moveable stones, which may present a problem during sialolithotomy. These sialoliths are smooth surfaced and have the appearance of a kernel of corn. With stones in a relatively anterior location, the placement of a duct-ligating suture posterior to it can be helpful (Fig 8).

In the vast majority of cases, there is one cardinal rule to be followed when considering the removal of stones from Wharton's duct. Because the calculus is intraductal, it can never be lost if the duct is first located and sufficiently isolated before any attempt at its removal is made. The direct cut-down on stones, regardless of their size, in the longitudinal portion of the duct is ill advised for several reasons. The duct may be macerated to such a degree that repair or dochoplasty would be impossible, resulting in possible postoperative salivary leakage or stenosis. There also is the possibility that portions of the calcified material may separate from the stone or that the stone itself, if it is small, could be lost into the surrounding tissues, resulting in a foreign body reaction or infection.

There are two situations where cut-down procedures are not only acceptable but also recommended. When a sialolith is present at the ductal orifice, an incision over the stone will lead to its extirpation and



**FIGURE 2.** A, Stone at the orifice of Wharton's duct causing the swelling (arrow). B, Stone located at the "comma area" of Wharton's duct (arrow).



**FIGURE 3.** A, Standard view of the occlusal x-ray. This view is limited posteriorly to the second molar. B, Note the position of the head and x-ray cone, which allows visualization of the gland and posterior fourth of Wharton's duct. C, Standard anterior view (*left*) is negative for a sialolith, whereas the posteroanterior view (*right*) shows the presence of a large stone (*arrow*). D, Standard anterior occlusal x-ray view reveals a stone at the opening of the duct (*arrow*), and the posterior view shows a stone in the "comma area" or hilus of the gland (*arrow*).

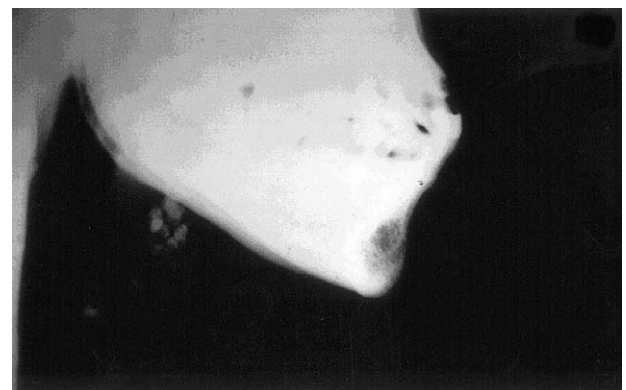
at the same time will allow for a sialodochoplasty. This is accomplished by suturing the exposed duct walls to their respective adjacent mucosa after the insertion of a lacrimal probe into the duct lumen (Fig 9). Second, when there is a large stone in the submandibular gland (Fig 10), pushing the gland upward and anteriorly will result in the projection of the stone prominence intraorally. Incision through the overlying mucosa will result in the exit of the stone. Because the gland is probably grossly fibrotic and non-functioning, no other treatment is likely to be necessary.

**TECHNIQUE**

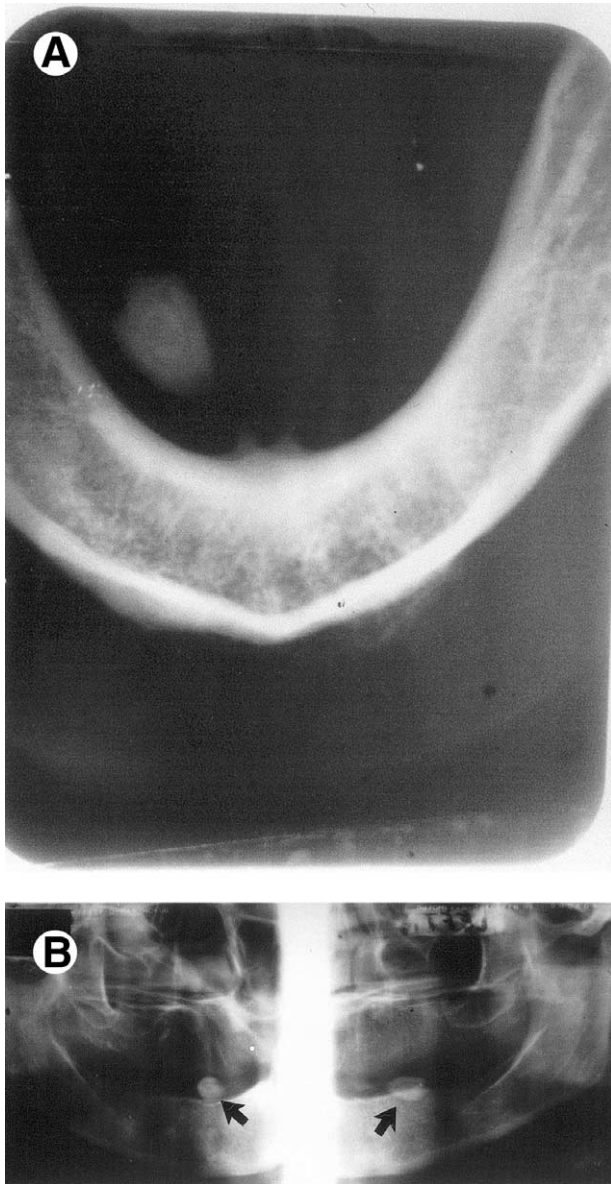With the primary aim of identifying and isolating Wharton's duct, an examination of the significant anatomic structures is appropriate. As the submandibular duct approaches its orifice, it moves anteriorly and superiorly so that its anterior third is relatively close to the surface mucosa. Therefore, regardless of where the stone is located in the duct, the initial mucosal incision is made anteriorly. During its anterior course through the oral floor, the duct lies adjacent to the medial surface of the sublingual gland whose superior projection is manifested by the raised plica sublingualis. As a consequence, a 2-cm incision

is made medial and parallel to the plica extending from the cuspid to the second bicuspid region (Fig 11A). If made laterally, the dissection to locate the duct would perforate and injure the sublingual gland, increasing the risk of an iatrogenically induced oral ranula. Attention needs to be given medial to the second molar in the midportion of the duct to the crossing of the lingual nerve.

With stones in the posterior two thirds of the duct, the preincision insertion of a lacrimal probe into



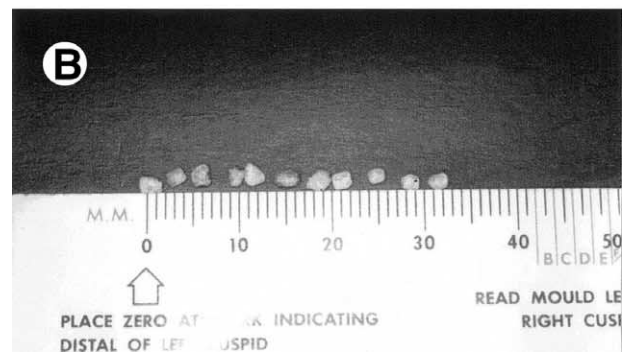
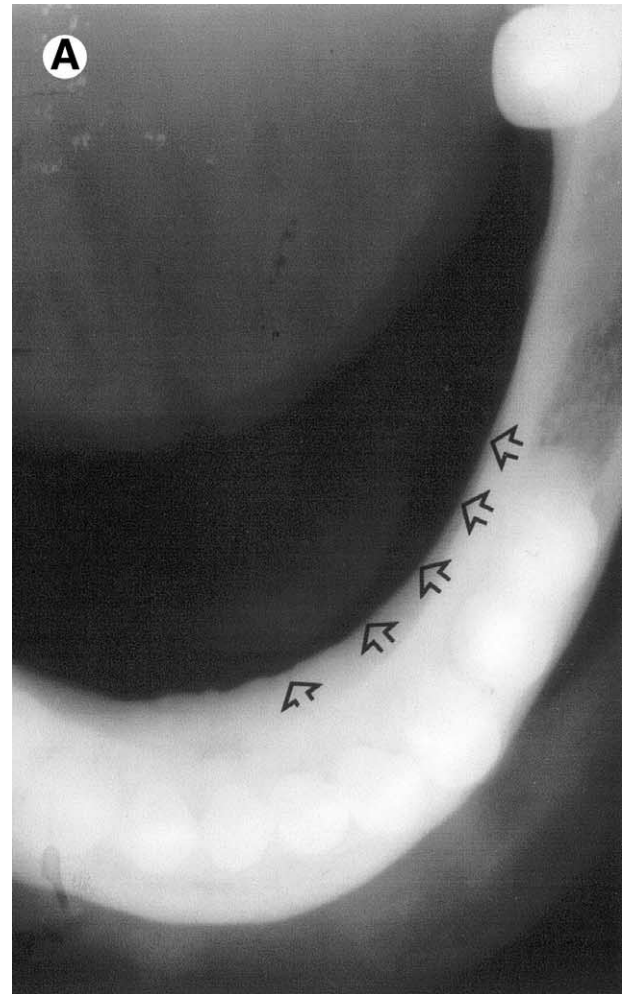
**FIGURE 4.** Lateral radiograph shows multiple stones in the submandibular gland.



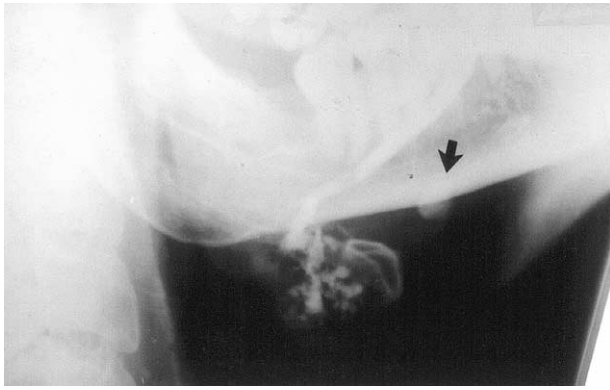
**FIGURE 5.** A, Single, large sialolith located in the anterior portion of Wharton's duct. B, Single stone appears as two stones (arrows) on the panoramic radiograph.

Wharton's duct will assist in more readily locating the duct; otherwise, a careful blunt dissection of the tissues with a curved mosquito hemostat will be successful. The key is to carry the dissection inferiorly with only slight deviations medially or laterally. Once identified and isolated, a retraction suture is placed around the duct, which is then gently retracted anteriorly (Fig 11B). To improve visualization of the operative site, several retraction sutures can be placed through the lateral aspect of the incised mucosal tissues and tied to the adjacent teeth. There is no need for this lingually because the tongue is generally reflected with a mouth mirror or a tongue retractor. If the stone is more posteriorly situated than the initial

incision, the mucosal incision is extended posteriorly and the duct exposed until a bulge is observed, signifying the stone's location (Fig 11C). In most cases, the prominence has a yellowish discoloration. When stones are at or near the comma area, by following the duct posteriorly in this fashion, it will be possible to identify and protect the lingual nerve as it crosses



**FIGURE 6.** A, Multiple stones in the anterior half of the duct are masked by the accumulation of pus in the duct (arrows). Also note the density of the tongue musculature. B, Eleven masked calcified sialoliths were removed from the duct of this patient.

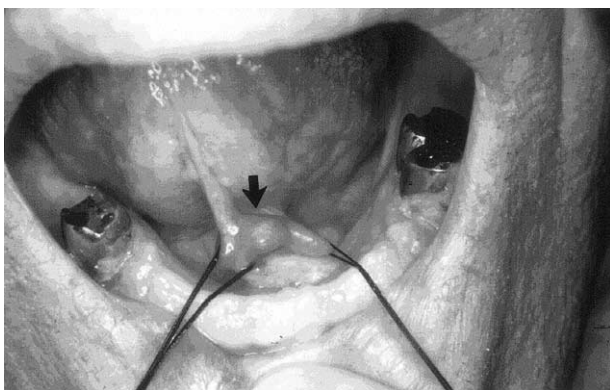


**FIGURE 7.** Presence of a calcified submandibular lymph node (arrow) distant from the gland and duct as visualized on the sialogram.

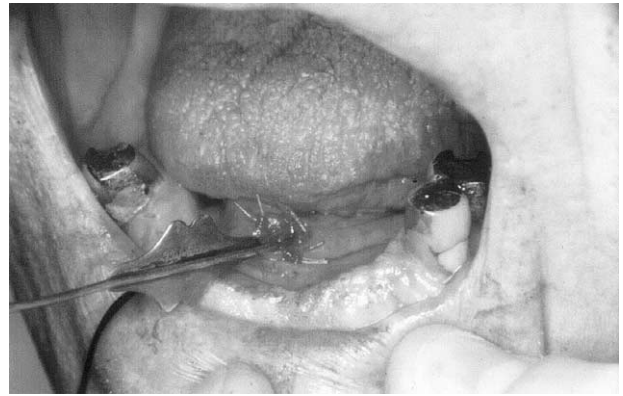
under Wharton's duct. Once the stone is isolated and the duct is stabilized by placing an elevator or a curved hemostat inferior to it, a longitudinal incision through the superior duct wall overlying the sialolith will result in its evacuation. The patency of the duct posterior to the stone is checked by the insertion of a good sized lacrimal probe, which is then followed with a saline intraductal irrigation and milking of the involved gland to remove any small residual stone fragments and/or mucus plugs.

Regarding the completion of the procedure, there are two offered recommendations: primary closure or sialodochoplasty (new duct opening).

If primary closure is performed, never suture the incised duct wall, because this will increase the risk of stenosis. To reduce the extent of oral floor swelling from salivary leakage and postsurgical edema, a tight mucosal closure is contraindicated and surgical drains are mandatory. This approach has a definite risk because the precondition of salivary stasis, which led to the initial sialolith development, may become more severe because further duct wall damage may follow sialolithotomy surgery. Thus, the risk of recurrence in future years may be markedly increased (Fig 12A).

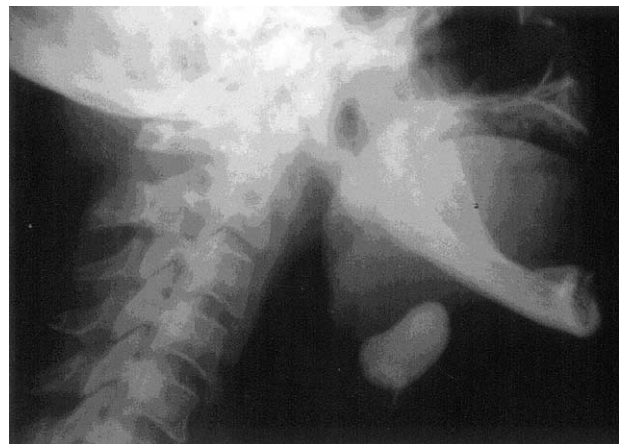

**FIGURE 8.** Duct-ligating suture is placed posterior to the possibly moving stone, immobilizing it.



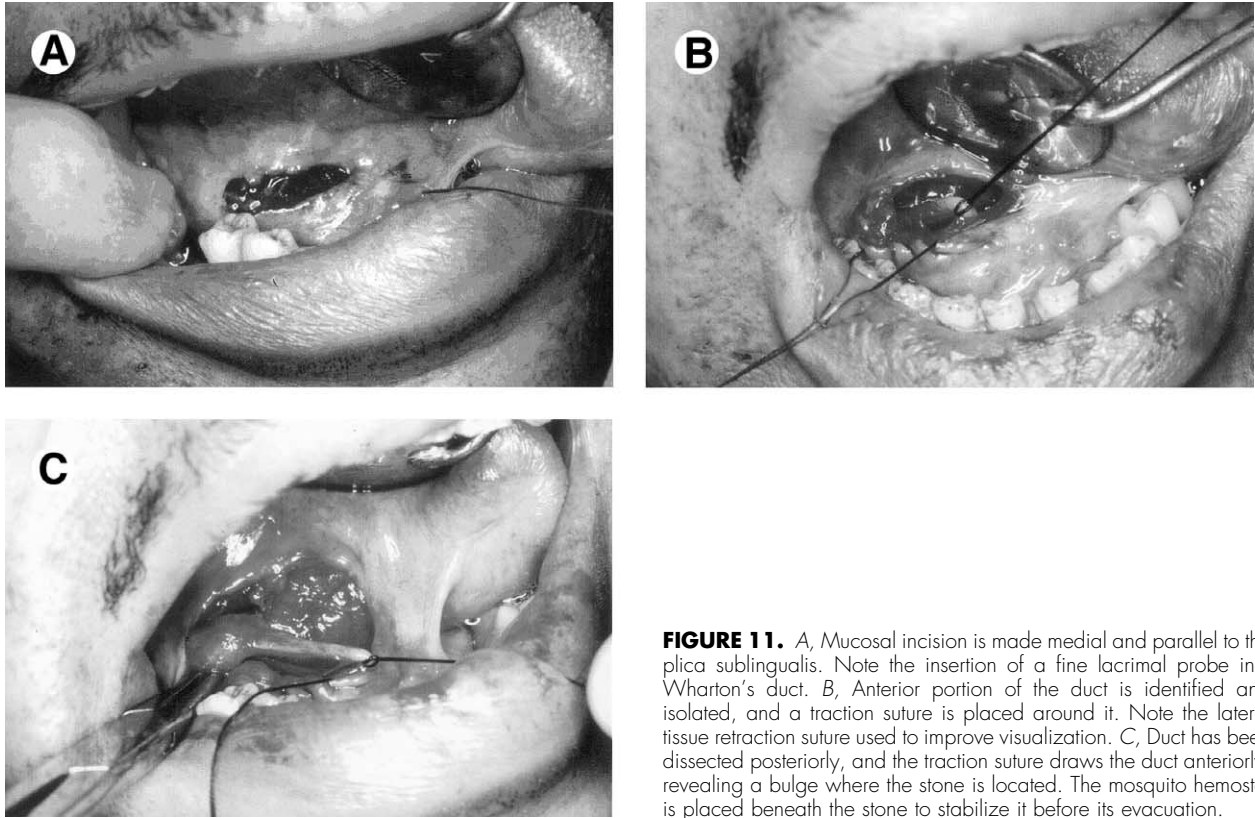
**FIGURE 9.** Direct cut-down on the stone in the region of the duct orifice permits sialodochoplasty to guarantee a patent duct opening. Note the insertion of a large lacrimal probe into the lumen of Wharton's duct.

Therefore, a new fabricated ductal opening is recommended at any location in the horizontal portion of the duct as long as it is posterior to the removed sialolith. There is no need to fear the possibility of any ascending infective organisms through the new, wider opening because both the cleansing action of salivary flow and the antimicrobial components of the saliva such as lysozyme, lactoferrin, and the salivary immunoglobulins appear to provide the necessary protection.<sup>6</sup> The longitudinal superior ductal incision is lengthened posteriorly, the margins of the incised duct wall are spread laterally, and each side is sutured to their adjacent mucosa with two absorbable fine sutures. If possible, a single suture is then placed through the superior wall of the duct at the proximal end of the longitudinal ductal incision to engage the overlying mucosa (Fig 12B). Ligation of the duct anterior to the dochoplasty to force salivary flow through the new opening is optional. Sialogogue-



**FIGURE 10.** Large sialolith involving the entire submandibular salivary gland.





**FIGURE 11.** A, Mucosal incision is made medial and parallel to the plica sublingualis. Note the insertion of a fine lacrimal probe into Wharton's duct. B, Anterior portion of the duct is identified and isolated, and a traction suture is placed around it. Note the lateral tissue retraction suture used to improve visualization. C, Duct has been dissected posteriorly, and the traction suture draws the duct anteriorly, revealing a bulge where the stone is located. The mosquito hemostat is placed beneath the stone to stabilize it before its evacuation.

activating foods and periodic duct dilation will ensure a new ductal opening (Fig 12C).

#### MANAGEMENT OF ACUTE INFLAMMATION SECONDARY TO SIALOLITHS

Fortunately, acute inflammation with suppuration is not a common occurrence as a consequence of obstructive sialadenitis secondary to sialoliths. When it does occur, the degree of suppuration and obstruction will determine the severity of symptoms. Unlike the standard symptoms of obstruction with gland enlargement and discomfort associated with eating, when there is acute inflammation, the swelling persists with more severe pain but without any relation to eating.

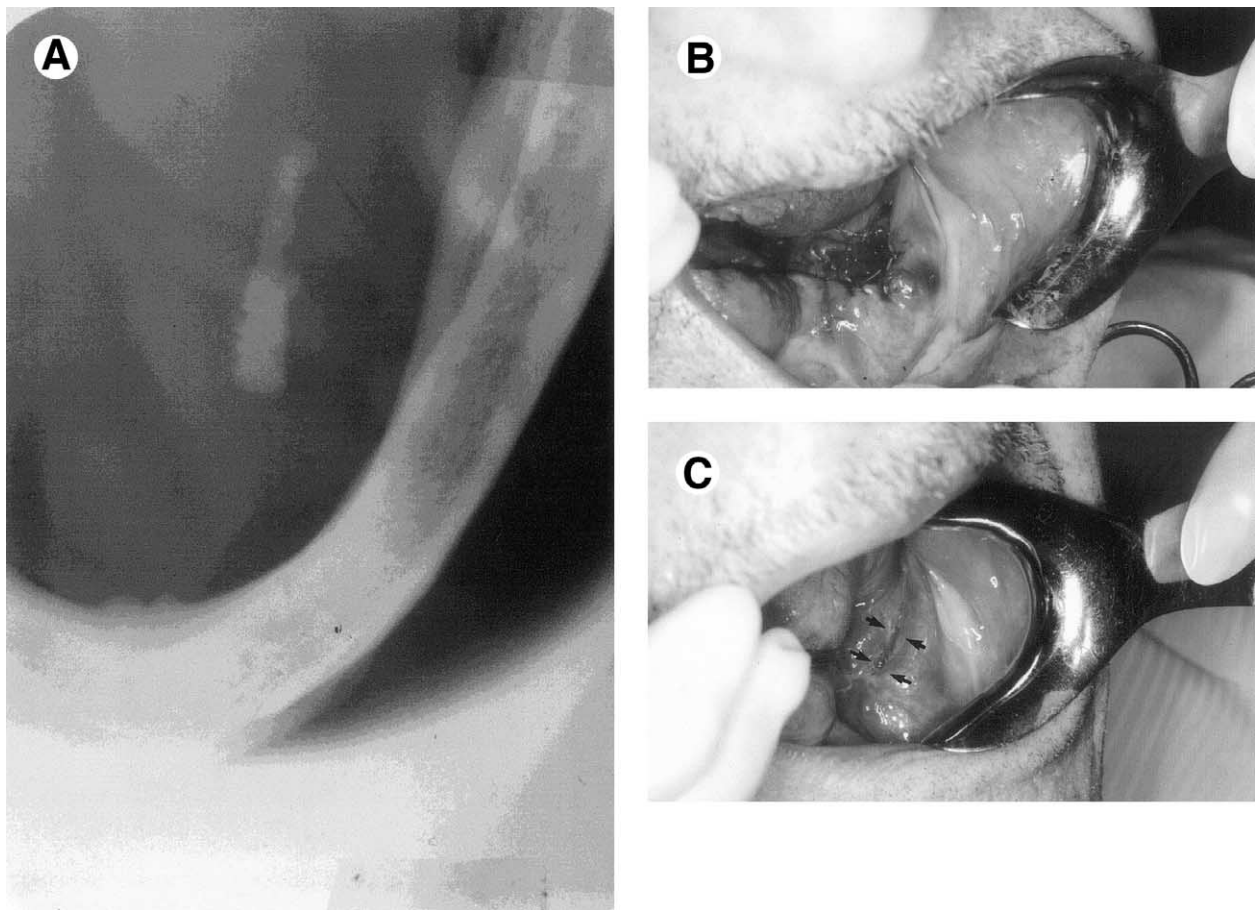
When pus is found exiting from Wharton's duct, the involved gland will show moderate enlargement with some discomfort. In those cases, we are generally dealing with small stones not far from the ductal orifice, and removal with the standard technique is a relatively simple matter because there is minimal tissue edema with little anatomic tissue distortion. This local acute inflammation may, at times, result in the spontaneous exfoliation of the stone (Fig 13).

When obstruction is more complete, there will be no pus observed and discomfort and gland swelling will be greater. Here, too, the standard technique of

sialolithotomy can be used to expose and incise the duct (Fig 14A). Following stone removal, there will be a free flow of pus (Fig 14B). A standard sialodochoplasty can then be performed after thorough irrigation of the area with sterile saline.

On occasion, the suppurative sialadenitis may be massive, involving the submandibular, submental, and sublingual spaces with gross distortion of the oral floor anatomy and extremely severe painful symptoms (Figs 15A, B). In these cases, the stones are usually relatively large and located in the more posterior ductal region. In as much as the pus is confined within duct and gland, with its impervious capsule, the standard incision and drainage would be both ineffective and probably damaging.

Surgical treatment must be directed toward locating and isolating the submandibular duct. With the edematous floor of the mouth, the caruncular and plica sublingualis are no longer clearcut structures, requiring the operator to estimate their location and direction before commencing the anterior placed mucosal incision. Because there is no possibility of inserting a lacrimal probe into the duct as an aid, careful blunt dissection must be performed to locate the superficially positioned duct. Once accomplished, the standard technique is used to reach and evacuate the stone and obstructed suppuration. The submandibu-



**FIGURE 12.** A, Recurrent submandibular sialolith at 15 years after a previous stone removal. Oblong stones are described as "date stones." B, After removal of the recurrent sialolith, a large sialodochoplasty was performed. C, Three weeks after stone removal, the new opening is patent and functioning (arrow).

lar gland is gently massaged to aid in the elimination of any residual pus and then the operative site is thoroughly irrigated with sterile saline. Unfortunately, the extensive edema does not favor the fabrication of a new duct opening. The wound is loosely closed with interrupted sutures, and a minimum of 2 or 3 drains are lightly placed. By the third postoperative day, all of the drains are removed. Antibiotics are prescribed in all 3 situations described, with the dosage and length of time of therapy directly related to the severity of symptoms. With careful surgical technique, clinical improvement is rapid (Figs 15C, D).

#### LITHOTRIPSY AS AN ALTERNATIVE METHOD OF SUBMANDIBULAR STONE MANAGEMENT

Shock wave lithotripsy, using a piezoelectric lithotripter, has been proposed primarily for the treatment of submandibular salivary gland stones.<sup>7,8</sup> Iro et al<sup>7</sup> treated 35 such stones using ultrasound to identify and localize the sialolith to be fragmented. As a result of this treatment, all stones were fragmented but only 40% showed complete stone clearance, whereas 85% were symptom free after 20 weeks. With only

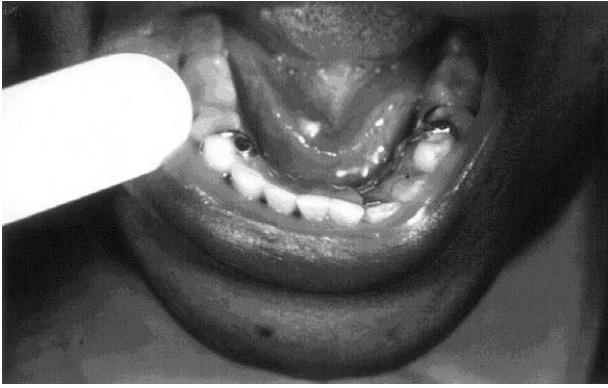
9-month follow-up, no conclusion could be reached regarding the incidence of symptomatic reobstruction (recurrence) with these cases.

Yoshizaki et al<sup>8</sup> treated 14 patients with submandibular gland stones and 3 submandibular duct stones in similar fashion. None of the submandibular duct stones could be disintegrated into sludge, and transductal ductotomy was performed. The results for submandibular gland stones were similar to that of Iro et al, and they also could not discuss the rate of recurrence following this treatment.

With the need for such advanced armamentarium and the poor results of this treatment, lithotripsy does not appear to be a viable routine method of management for submandibular sialoliths.

#### LASER SIALOLITHECTOMY AS AN ALTERNATIVE METHOD OF SALIVARY STONE MANAGEMENT

Azaz et al<sup>9</sup> reported on sialolithectomy using the Sharplan CO<sub>2</sub> laser on 47 patients with submandibular duct stones, of which 42 were in the horizontal portion of the duct. Only 27 patients returned for follow-up after 1 year, at which time 12 patients had



**FIGURE 13.** Small sialolith in the process of spontaneous exfoliation with associated suppuration.

normal flow of saliva, 7 had diminished flow, and 8 had complete cessation of the salivary flow. Their conclusion was that this treatment: "Yields excellent results, with almost no bleeding, minimal scarring, and little discomfort through the healing period." In addition, it permits surgery in the outpatient clinic under local anesthesia even during the acute stage.

Except for the questionable advantage of possibly being fast, there seems to be no other benefit over the standard recommended surgical treatment. However, there are questions relating to such a blind procedure because it is only after the beam encounters the sialolith that "it sparkles" and indicates its exact location. How much tissue destruction is there before "it sparkles," especially with stones in the vicinity of the lingual nerve? Furthermore, in view of the 15 of 27 patients with abnormal salivary flow, what is the sta-

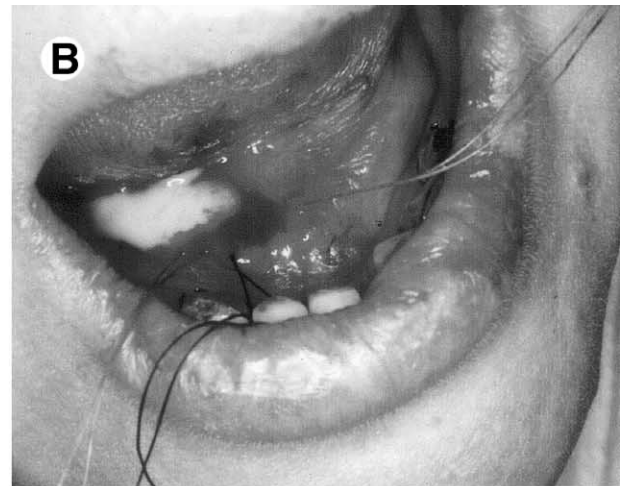
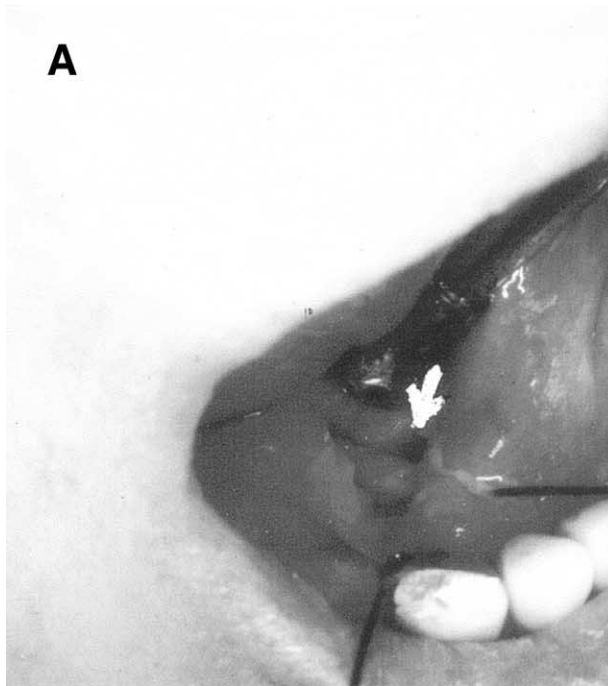
tus of the ductal openings after this surgery and what is the susceptibility for recurrence? Certainly, sialodochoplasty to ensure unimpeded salivary flow is not possible with CO<sub>2</sub> laser surgery. With the absence of clear benefit and with the possibility of deleterious effects, is this technique, which requires specialized equipment, warranted?

#### DUCTAL STENOSIS REPAIR TECHNIQUE

On occasion, stenosis of the duct may be encountered with characteristic symptoms of recurrent obstructive sialadenitis. This may occur as a consequence of a previous sialolithotomy, ranula or sublingual gland removal, or direct trauma to Wharton's duct. Because standard radiology and ultrasonography results will be negative for this condition, only the sialogram can provide a positive diagnosis. The technique prescribed is the same as that of stone removal as far as the location and isolation of the submandibular duct are concerned, followed by the previously described sialodochoplasty. If possible, the insertion of a lacrimal probe into the original ductal orifice will identify the location of the stenosis and the new ductal opening is constructed posterior to it.

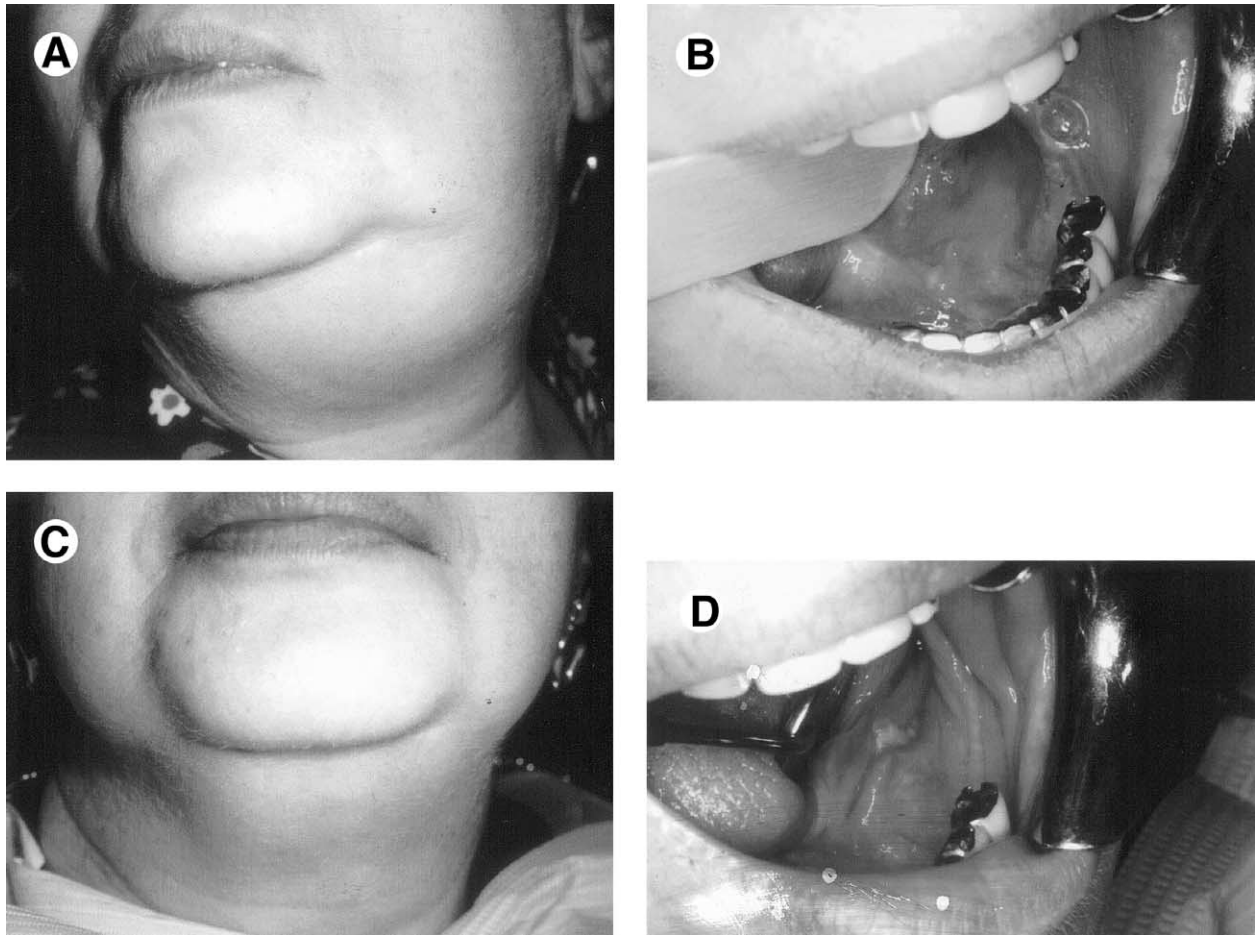
#### INDICATION FOR SUBMANDIBULAR GLAND REMOVAL

Long-standing submandibular obstructive sialadenitis, whether due to sialoliths or stenosis, naturally leads to chronic gland inflammation with some parenchymal destruction. However, after the elimination of the obstruction, the apparent resiliency of the sub-



**FIGURE 14.** A, With symptoms of acute sialadenitis and no obvious suppuration, the duct is exposed (arrow) using the standard technique. B, After incision of the duct and evacuation of the stone, there was a free flow of pus.



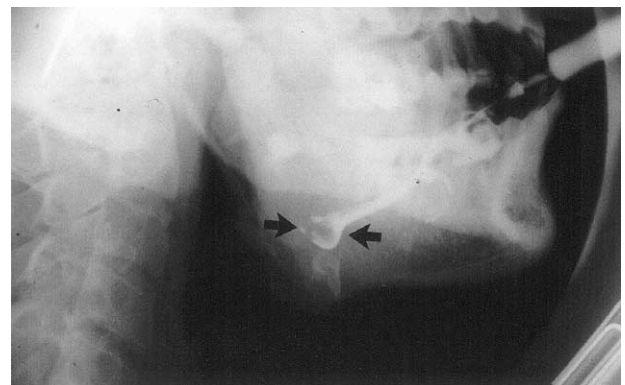


**FIGURE 15.** A, Extraorally, there was a large acute swelling involving the submandibular and submental spaces. B, Intraorally, the entire oral floor was swollen with the absence of all surface landmarks. C, At 1 week postoperatively, there was significant reduction of the extraoral swelling. D, At 1 week postoperatively, the swelling in the floor of the mouth was markedly reduced and the plica sublingualis could be visualized.

mandibular gland usually results in no adverse symptoms. Yoshimura et al,<sup>10</sup> in their scintigraphic evaluation of 13 cases of submandibular duct sialolithiasis, found only 3 cases with no function after sialolithectomy. They failed to mention whether any of those showed any postoperative symptoms. Therefore, gland removal in the majority of these cases is unnecessary. Certainly gland extirpation as a substitute for sialolithotomy with stones in the proximal portion of the duct is to be condemned because it does not solve the immediate problem and because symptoms of swelling, discomfort, and suppuration can be expected (Fig 16). Gland removal is indicated only when small stones are present in the vertical portion of the duct from the comma area to the hilus or within the gland itself that are not surgically accessible intraorally and produce obstructive symptoms. Nahlieli and Baruchin,<sup>11</sup> in describing their technique of sialoendoscopy, reported successful results in the removal of stones in this region. When available for use, gland extirpation may not be necessary. Another significant benefit of their technique is its ability to view

the duct lumen postoperatively to detect and remove residual stones and to treat potential areas of stenosis.

With greater availability of sialoendoscopic armamentarium and more trained operatives of the technique,



**FIGURE 16.** A residual sialolith at the "comma area" (arrow) after removal of the submandibular salivary gland 2 years earlier. The patient experienced intermittent pain, suppuration, and swelling in the floor of the mouth.

one should expect more accurate diagnoses of small or poorly calcified sialoliths, mucous plugs, ductal stenosis, and polyps without the need for the often difficult sialogram. And as a consequence, the management of submandibular gland obstructive disease will become even more effective. Obstructive disease not associated with intraductal plugs, stenosis, or sialoliths may be due to neoplasia, which should always be considered in the differential diagnosis of salivary gland disease.

## References

1. Mason DK, Chisholm DM: Obstructive and traumatic lesions, *in* Salivary Glands in Health and Disease. Philadelphia, PA, Saunders, 1975, p 107
2. Nahlieli O, Eliav E, Hasson O, et al: Pediatric sialolithiasis. *Oral Surg Oral Med Oral Pathol Oral Radiol Endod* 6:709, 2000
3. Mandel ID: Histochemical and biochemical aspects of calculus formation. *J Am Soc Periodont* 1:43, 1963
4. Tandler B: Electron microscopical observations on early sialoliths in a human salivary gland. *Arch Oral Biol* 10:509, 1965
5. Mason DK, Chisholm DM: Embryology, applied anatomy, and innervation, *in* Salivary Glands in Health and Disease. Philadelphia, PA, Saunders, 1975, p 10
6. Mason DK, Chisholm DM: Saliva, *in* Salivary Glands in Health and Disease. Philadelphia, PA, Saunders, 1975, p 56
7. Iro H, Schneider HT, Fodra C, et al: Shockwave lithotripsy of salivary duct stones. *Lancet* 339:1333, 1992
8. Yoshizaki T, Maruyama Y, Motoi I, et al: Clinical evaluation of extra corporeal shock wave lithotripsy for salivary stones. *Ann Otol Rhinol Laryngol* 105:63, 1996
9. Azaz B, Regev E, Casap N, et al: Sialolithectomy done with a CO<sub>2</sub> laser: Clinical and scintigraphic results. *J Oral Maxillofac Surg* 54:685, 1996
10. Yoshimura Y, Morishita T, Sugihara T: Salivary gland function after sialolithiasis: Scintigraphic examination of submandibular glands with 99m Tc-perchnetate. *J Oral Maxillofac Surg* 47:704, 1989
11. Nahlieli O, Baruchin AM: Sialoendoscopy: Three years experience as a diagnostic and treatment modality. *J Oral Maxillofac Surg* 55:912, 1997