

Case Report

Gingival hyperplasia being the first sign of Wegener's granulomatosis

Víctor Aravena¹, Víctor Beltrán², Mario Cantín^{3,4}, Ramón Fuentes²

¹Department of Adult Dentistry, Faculty of Medicine and Dentistry, Universidad de Antofagasta, Antofagasta, Chile; ²Department of Adult Dentistry, CIMOFIR Research Center, Faculty of Dentistry, Universidad de La Frontera, Temuco, Chile; ³Doctoral Program in Morphological Sciences, CIMA Research Center, Faculty of Dentistry, Universidad de La Frontera, Temuco, Chile; ⁴Center of Research in Biomedical Sciences, Universidad Autónoma de Chile, Temuco, Chile

Received June 15, 2014; Accepted July 27, 2014; Epub August 15, 2014; Published August 30, 2014

Abstract: Wegener's granulomatosis (WG) is a multisystemic granulomatous vasculitis that predominantly affects the airways and the kidneys, but may affect any organ. Otorhinolaryngological manifestations may be gingival swelling, oral ulcer or septal perforations that can cause saddle nose deformities, rhinitis, sinusitis and hearing loss. We report a case of WG that was first diagnosed on oral gingival mucosa. A 54-year old woman was referred to a specialized dentist because of consistent irritative buccal gingival hyperplasia that did not react to conservative and microbial treatment. The lesion was biopsied and the diagnosis was suggestive for WG. Patient was further referred to the Unit of Rheumatology and the diagnose of WG was confirmed and treated. This case emphasizes the importance to recognize the oral manifestation of WG to get proper medication as soon as possible and avoid serious systemic tissue damage.

Keywords: Wegener's granulomatosis, granulomatous disease, hyperplastic gingivitis, vasculitis

Introduction

Wegener's granulomatosis (WG) is an autoimmune multisystem disease of unknown etiology, characterized by necrotizing granulomatous vasculitis that primarily affects the upper and lower respiratory tract and kidneys, but can affect any area of the body (Hoffman 1992), including the oral cavity [1-3]. The GW untreated can have a fatal course [3], where kidney damage causes most deaths, between 9% and 36% of cases [4]. Renal involvement is characterized by focal and segmental glomerulosclerosis, and determines the evolution. The diagnosis is made by clinical symptoms and signs, the presence of c-ANCA and a positive biopsy. The anatomic pathology is characterized by vasculitis, granulomatous inflammation with multinuclear giant cells and necrosis. The prognosis has improved as a result of treatment with immunosuppressants associated with corticosteroids [2].

Currently, the prognosis of this disease has improved with early diagnosis and immunosup-

pressive treatment [5]. However, the wide spectrum of clinical symptoms, similar to other diseases, such as mucocutaneous lesions include palpable purpura, necrotic ulcerations, papules, nodules, superficial erosions and petechiae, blisters and erythema, presentations appropriate differential diagnosis make necessary, which is mainly hindered by the non-specific symptoms [6], mainly hindered by the non-specific symptoms.

For this reason, the recognition of a distinctive sign aid early diagnosis [1, 2]. According to the American College of Rheumatology for a proper diagnosis must meet at least two of the following criteria: 1) ulcerative lesions in the oral mucosa or nasal bleeding or swelling, 2) nodules, infiltrates or cavities on chest radiograph, 3) abnormal urinary sediment and 4) granulomatous inflammation on biopsy [7].

Current medical evidence has reported the presence of an inflammatory manifestación in the oral cavity, called granular hyperplastic gingivitis or "strawberry gingivitis" [1, 3, 7-11], rec-

Gingival manifestation in Wegener's granulomatosis

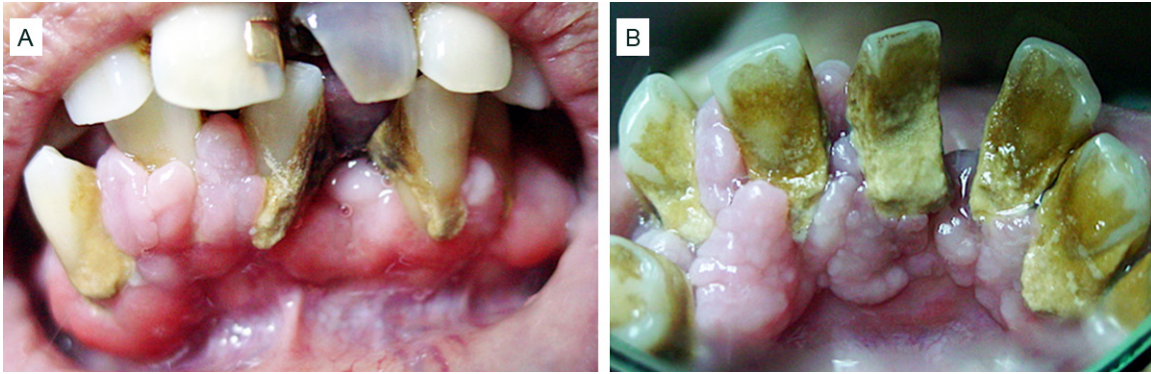


Figure 1. The intraoral examination shows alterations in gingival volume without the presence of petechiae on the buccal and lingual gingiva between teeth 33 and 43, being clinically diagnosed as hyperplastic gingivitis.

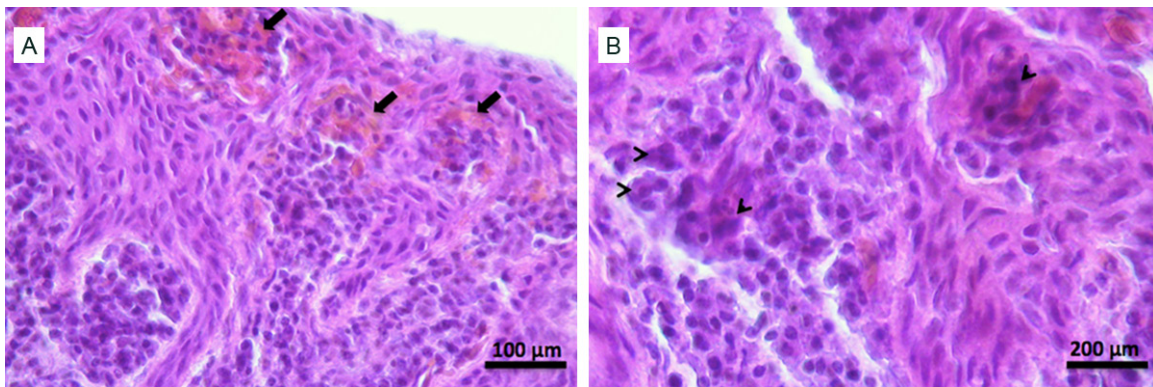


Figure 2. A. Gingival tissue biopsy where decreased thickness epithelium, with loss of cell polarity and morphological changes consistent with dysplasia was observed. Also in the connective tissue, inflammatory infiltrate with lymphocytes and plasma cells (autoimmune response), foci of extravasation as microhaemorrhage foci (arrows) were observed. B. At higher magnification some multinucleated giant cells (arrowheads) are observed. Hematoxylin-eosin staining.

ognized as pathodiagnostic parameters or initial manifestation of a systemic granulomatous vasculitis [1, 3, 7, 9-12], observed in about 5-10% of patients with WG [3, 8], recognized as a valuable diagnostic aid [13].

We present the case of a 54-year-old patient with granular hyperplastic gingivitis without association to drugs, which led us to suspect WG.

Case report

A 54-year-old female patient was referred to the Department of Dentistry in the Universidad de Antofagasta. The patient was first diagnosed with hyperplastic gingivitis by her family dentist and was treated by non-surgical periodontal therapy and antibiotics. The treatment had no beneficial effect. In the clinical examination,

the patient reported a history of bruise on lower limbs, plus a clinical picture of arthritis, severe in hands, and undiagnosed skin disorders.

In the intraoral examination, manifestations of periodontal disease were observed, with lots of tartar, associated with alterations in gingival volume without the presence of petechiae on the buccal and lingual gingiva between teeth 33 and 43, being clinically diagnosed as chronic periodontal disease, with areas of hyperplastic gingiva; the latter with strawberry-like appearance (**Figure 1**).

Radiographic examination showed severe bone resorption in the anterior region of the jaw, with teeth that had poor periodontal prognosis, so it was decided to make their extractions and take a biopsy of the buccal gingival tissue of tooth 41.

Gingival manifestation in Wegener's granulomatosis

The biopsy was sent to the laboratory for routine histopathological study. The histological sections showed two different areas. An area showing a normal appearance consisting of stratified squamous epithelium without alteration, which is supported by a connective tissue without inflammatory infiltration.

The contiguous zone of mucosal epithelium has decreased in thickness, with loss of cell polarity and morphological changes consistent with dysplasia.

Corium of this area, an intense inflammatory infiltrate consisting of lymphocytes and plasma cells, indicating the presence of a reaction that has an immune component was observed, also some multinucleated giant cells were observed in the deeper regions of connective tissue with the presence of blood extravasation foci as microhemorrhagic foci, reaching the diagnosis of epithelial dysplasia with lymphoplasmacytic inflammation process and microhemorrhage, compatible with the characteristic granulomatous vasculitis characteristic of GW (**Figure 2**). The patient was referred to internal medicine Antofagasta Regional Hospital where the diagnosis of GW was confirmed and immunosuppressive therapy was initiated.

Discussion

Various theories have been proposed regarding the etiology of the GW, where autoimmunity, hypersensitivity or infection are a precipitating factor for the disease [6]. The bacterial infection has been associated with the occurrence and onset of the disease [5]. However, the disease has a low prevalence and few cases are diagnosed at the right time. In Santiago de Chile, of 173 patients diagnosed with primary systemic vasculitis identified during the period 1990-2001, 58 were for Wegener granulomatosis [14].

Oral lesions may be seen in 10 to 62 percent of patients [7, 8] and may be the initial sign in the 5-6 percent of patients [7]. The most characteristic initial lesion is edematous or hyperplastic gingivitis with red interdental papillae covered with hyperplastic diffuse purple petechiae. The lesion usually shows an appearance of "pebbles" or granular and often referred to as "strawberry gingivitis". Initial swelling of affected gum can be joined to produce a generalized pattern across the buccal and lingual gingiva,

even extending to or beyond the mucogingival junction [1, 7, 9, 11, 15].

Other oral manifestations may include tooth mobility, poor healing after extraction, cranial nerve palsies and alterations of the parotid gland [7, 8, 12], and has reported the appearance unusual oral ulcers and rapidly progressive periodontitis in a pediatric patient [16]. Because the gingival condition, like others [17-19], may remain localized for long periods before multiorgan involvement occurs, early diagnosis is essential to prevent serious or fatal consequences [3, 7, 20]. Ruokonen et al. [3] reported a case where the first and unique symptom to diagnose GW was the gingival exophytic growth with strawberry type extensions and petechiae, similar to that reported in our case.

Manchanda et al. [1] also reported gingival hyperplasia as the main sign on the gingiva in patients with WG, associated with gingival bleeding. The gums were swollen with a red, friable, and granular appearance. The gingival biopsy revealed a dense neutrophilic subepithelial infiltration. However, differential diagnosis must be performed with gingival enlargement caused by medications such as phenytoin, cyclosporine, and some oral contraceptives causing altered collagen metabolism of human gingival fibroblasts [3].

In this sense, when the classic triad of necrotizing granulomatous lesions of the respiratory tract, generalized vasculitis and necrotizing glomerulonephritis are absent, the diagnosis of Wegener's granulomatosis is difficult. It has been suggested that a thorough assessment oral mucosa and skin are valuable diagnostic aids in medical equipment [8]. Histopathological criteria for diagnosis of GW include vasculitis, granulomatous inflammation, multinucleated giant cells, and necrosis. In most cases, however, the histological findings of gingival lesions are less specific, but they demonstrate the acute or chronic inflammation, multinucleated giant cells and pseudoepitheliomatous hyperplasia. While these findings can not be considered as diagnostics, should be considered to support a diagnosis of presence of GW hyperplastic gingivitis or strawberry gingivitis [7].

The dentist may initially suspect GW from the clinical history and oral presentation. Clinical suspicion should be followed by oral biopsy [7]

Gingival manifestation in Wegener's granulomatosis

and referral to a specialist, allowing therapeutic intervention at an earlier stage if the disease has not been diagnosed.

Disclosure of conflict of interest

None.

Address correspondence to: Víctor Beltrán, Department of Adult Dentistry, CIMOFIR Research Center, Dental School, Universidad de La Frontera, Manuel Montt 112, Temuco, Chile. E-mail: victor.beltran@ufrontera.cl

References

- [1] Manchada Y, Tejasvi T, Handa R, Ramam M. Strawberry gingiva: A distinctive sign in Wegener's granulomatosis. *J Am Acad Dermatol* 2003; 49: 335-7.
- [2] Reboll-Ferrer RM, Zapater-Latorre E, Calabuig-Crespo C, Basterra-Alegría J. Wegener's granulomatosis: Description of a case with oral manifestation. *Med Oral Patol Oral Cir Bucal* 2010; 15: 601-4.
- [3] Ruokonen H, Helve T, Arola J, Hietanen J, Lindqvist C, Hagstrom J. "Strawberry like" gingivitis being the first sign of Wegener's granulomatosis. *Eur J Intern Med* 2009; 20: 651-3.
- [4] Sproson EL, Jones NS, Al-Deiri M, Lanyon P. Lessons learnt in the management of Wegener's Granulomatosis: long-term follow-up of 60 patients. *Rhinology* 2007; 45: 63-7.
- [5] Popa ER, Stegeman CA, Kallengberg CG, Tervaert JW. Staphylococcus aureus and Wegener's granulomatosis. *Arthritis Res* 2002; 4: 77-9.
- [6] Burlacoff SG, Wong FS. Wegener's granulomatosis. The great masquerade: a clinical presentation and literature review. *J Otolaryngol* 1993; 22: 94-105.
- [7] Steward C, Cohen D, Bhattacharyya I, Scheitler L, Riley S, Calamia K, Migliorati C, Baughman R, Langford P, Katz J. Oral manifestations of Wegener's granulomatosis: a report of three cases and a literature review. *J Am Dent Assoc* 2007; 138: 338-48.
- [8] Patten SF, Tomecki KJ. Wegener's granulomatosis: cutaneous and oral mucosal disease. *J Am Acad Dermatol* 1993; 28: 710-8.
- [9] Cohen RE, Cardoza TT, Drinnan AJ, Aquirre A, Neiders ME. Gingival manifestations of Wegener's granulomatosis. *J Periodontol* 1990; 61: 705-9.
- [10] Napier SS, Allen JA, Irwin CR, McCluskey DR. 'Strawberry gums'-a case of Wegener's granulomatosis. *Br Dent J* 1993; 175: 327-9.
- [11] Napier S, Allen J, Irwin C, McCluskey D. Strawberry gums: a clinicopathological manifestation diagnostic of Wegener's granulomatosis? *J Clin Pathol* 1993; 46: 709-12.
- [12] Eufinger H, Machtens E, Akuamo-Boateng E. Oral manifestations of Wegener's granulomatosis. Review of the literature and report of a case. *Int J Oral and Maxillofac Surg* 1992; 21: 50-3.
- [13] Marzano A, Fanoni D. Oral and cutaneous findings are valuable diagnostic aids in Wegener's granulomatosis. *Eur J Intern Med* 2010; 21: 49.
- [14] Cisternas M, Soto L, Jacobelli S, Marinovic MA, Vargas A, Sobarzo E, Saavedra J, Chauan K, Meléndez G, Foster C, Pacheco D, Wainstein E, Grupo de estudio de las vasculitis, Sociedad Chilena de Reumatología. Clinical features of Wegener granulomatosis and microscopic polyangiitis in Chilean patients. *Rev Med Chil* 2005; 133: 273-8.
- [15] Liam CK. Hyperplastic gingivitis: an oral manifestation of Wegener's granulomatosis. *Postgrad Med J* 1993; 69: 754.
- [16] Xing X, Zhang T, Wang X. Pediatric Wegener's granulomatosis with oral ulcers and progressive periodontitis: a case report. *Oral Surg Oral Med Oral Pathol Oral Radiol Endod* 2011; 112: e1-5.
- [17] Calefi PL, Sorgini DB, Borie E, Toniollo MB, Barros LAB, Pedrazzi V. Periodontal Surgical Treatment in Aesthetic Oral Rehabilitation: A Clinical Case Report. *Int J Odontostomat* 2012; 6: 363-8.
- [18] Velasco I, Aguilar L, PASTRIAN J, Mebus C, Martínez B. Gingival metastasis from a testicular choriocarcinoma: an unusual case report and review of the literature. *Int J Morphol* 2013; 31: 140-3.
- [19] Beltrán V, Silva M, Padilla M, Aillapan E, Sanhueza A, Cantín M, Fuentes R. Morphological Patterns of Gingival Recession in Adult Chilean Population. *Int J Morphol* 2013; 31: 1365-70.
- [20] Siar CH, Yeo KB, Nakano K, Nagatsuka H, Tsujigiwa H, Tomida M, Ng KH, Kawakami T. Strawberry gingivitis as the first presenting sign of Wegener's granulomatosis: report of a case. *Eur J Med Res* 2011; 16: 331-4.