



Maxillary Sinus Functions and Complications with Lateral Window and Osteotome Sinus Floor Elevation Procedures Followed by Dental Implants Placement: A Retrospective Study in 60 Patients

Saad Al-Almaie, Abdul Majeed Kavarodi, Abdullah Al Faidhi

ABSTRACT

Aim: The aim of the study was to evaluate retrospectively maxillary sinus functions and complications by using generally accepted diagnostic criteria with lateral window and osteotome sinus floor elevation (OSFE) procedures followed by dental implants placement.

Materials and methods: A group of 60 patients in whom a SFE with the two procedures (lateral window and OSFE) followed by dental implants placement had been performed were evaluated retrospectively for sinus functions and complications from the time of procedure up to 24 months using a questionnaire, conventional clinical and radiographic examination.

Results: Number of patients suffered dizziness accompanied by nausea immediately after OSFE was more than the lateral window procedure and the symptoms disappeared within 2 to 4 weeks. Maxillary sinus membrane perforations occurred and small for 4 out of 79 procedures, two cases for OSFE and two for lateral window procedure had been repaired. No more complications had been detected for all the patients up to 24 months.

Conclusion: Based on the results of this study, SFE with lateral window and osteotome procedures followed by dental implants placement did not interfere with maxillary sinus function and no obvious complications had been detected up to 24 months.

Clinical significance: The clinician performs SFE with either lateral window or osteotome procedures needs to understand the difficulties and morbidity arising in the event of complications and must be able to correctly judge the individual risk and the presence of modifying factors that may cause these complications.

Keywords: Lateral window, Osteotome, Benign paroxysmal positional vertigo, Schneiderian membrane, Sinus floor elevation, Dizziness, Nausea, Perforations.

How to cite this article: Al-Almaie S, Kavarodi AM, Al Faidhi A. Maxillary Sinus Functions and Complications with Lateral Window and Osteotome Sinus Floor Elevation Procedures Followed by Dental Implants Placement: A Retrospective Study in 60 Patients. *J Contemp Dent Pract* 2013;14(3):405-413.

Source of support: Nil

Conflict of interest: None declared

INTRODUCTION

The maxillary posterior edentulous area of the mouth presents unique concerns and considerations for implant reconstruction. Typically, periodontal disease and bone resorption after tooth loss result in loss of alveolar bone height. There is usually an initial decrease in bone width secondary to buccal bone plate resorption. This occurs in the posterior maxilla at a more rapid rate than in other areas of the mouth.¹ In addition, with the passage of time, this is accompanied by a significant decrease in bone density as a result of the presence of fewer trabeculae. This combination provides less implant stability and bone contact. Finally, occlusal forces generated in the posterior area of the mouth are greater than in anterior areas.

The sinus floor elevation (SFE, augmentation) procedure first introduced by Tatum,² Boyne, and James³ and later modified by many others has resulted in predictable implant placement with long-term success in the posterior maxilla. A less invasive alternative for SFE with concurrent grafting and immediate implant placement was introduced by Summers in 1994.⁴ The osteotome sinus floor elevation (OSFE) is generally used in moderately resorbed posterior maxilla to graft the maxillary sinus in combination with immediate implant placement.⁵ This technique requires striking the bone with a surgical mallet until the desired depth is reached. During the installation of maxillary dental implants using the OSFE, the surgical trauma induced by percussion with the surgical mallet, along with hyperextension of the neck during the operation, can

displace otoliths and result in the appearance of benign paroxysmal positional vertigo (BPPV).⁶ BPPV is a common vestibular end organ disorder characterized by short, often recurrent episodes of vertigo that are triggered by certain head movements in the plane of the posterior semicircular canals.⁷ Although the incidence of OSFE-induced BPPV was less than 3% (4 in 146 patients) and commonly resolves itself within a month without treatment,⁵ the symptoms involved are very unpleasant.⁷ The symptoms are sufficiently severe to significantly hinder patients from carrying out normal daily activities if not identified correctly and managed properly. In fact, the SFE (augmentation) procedure is a relatively simple, highly predictable surgical technique,⁸ generally considered to be a safe surgical procedure with a low prevalence of complications,^{9,10} if proper treatment planning, careful surgical technique, adequate experience, and patient cooperation are in place. The SFE (augmentation) procedure, however, as is true with any surgery, is not without complications. Although the overall complication rate is relatively low, one of the more common complications is membrane perforation. The purpose of this study was to evaluate retrospectively maxillary sinus functions and complications in 60 patients by using generally accepted diagnostic criteria after sinus lift with lateral window and osteotome approaches followed by dental implant placement from the time of procedure up to 24 months.

MATERIALS AND METHODS

Patients Selection

From January 2006 to January 2008 (an interval of 24 months), 60 patients were recorded for this retrospective study (27 males and 33 females). Patients who showed any uncontrolled systemic disease, ongoing chemo- or radiotherapy or a history of maxillary sinus diseases were excluded before starting the surgical procedures. Before treatment, all patients were clinically and radiographically examined (by periapical and panoramic radiography). A total of 113 ITI dental implants were simultaneously placed according to the procedure that performed for each case. The types of procedures were selected based on residual subsinus alveolar bone height (RSBH) in the areas of interest. The cases with pre-existing available bone height were closed to 3 mm, the sinus elevation augmentation procedures with lateral window were performed, and the cases with available bone height were more than 4 mm, the OSFE were performed without grafting materials. Preceding the surgical procedure, all patients were asked about a history of maxillary sinusitis-related symptoms. Upon sitting up after surgery, a questionnaire on the patient's experienced

intense vertigo with nausea, especially when they changed the position of their heads had been completed, and radiographic examinations were performed. Perforations of the Schneiderian membrane during SFE for both procedures were noted. Complication of the surgical procedure such as: infection of maxillary sinus, loos of bone particles through the nose, wound dehiscence, poor primary stability of implant, bleeding from injured vessels, implant migration within the sinus, graft migration within the sinus, and nerve exposure or injuries were recorded.

Surgical Technique

All the procedures were performed under local anesthesia. Prophylactic oral antibiotics were used routinely (amoxicillin 500-1,000 mg), beginning 8 hours before the procedure and continued for 7 days. Lateral window procedure allows direct vision of the elevated sinus membrane. The implants are placed either simultaneously with the graft (one-stage lateral antrostomy) or after a delayed period of up to 9 months to allow for graft maturation (two-stages lateral antrostomy). An example of the surgical procedures of lateral window procedure for the two methods were performed are visible in (Figs 1A to G) and (Figs 2A to G). The initial bone thickness at the alveolar ridge seems to be a reliable indicator in deciding between these two methods. The maxillary sinus function and complications for both procedures were recorded.

The sinus augmentation procedure followed the technique described by Tatum² et al.^{11,12} Care was taken not to perforate the sinus membrane. When a membrane perforation was discovered, the membrane surrounding the perforation was delicately dissected with a blunt instrument, in an attempt to relieve the pressure, at the perforated area.

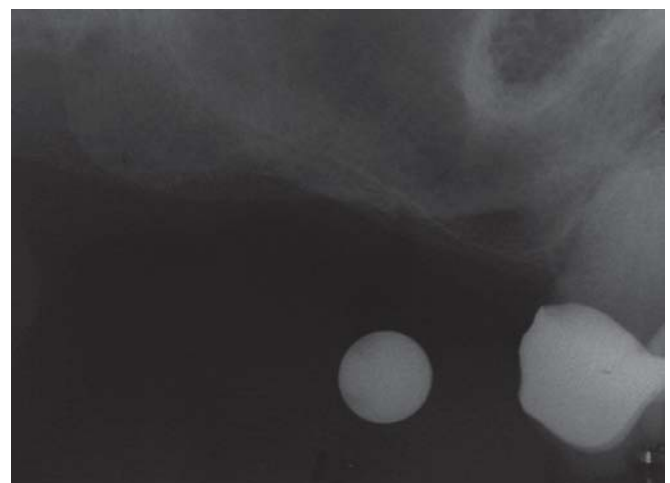

Fig. 1A: Lateral window SFE with two stages: preoperative radiograph (including a 5 mm steel ball for calibration) revealing 1 to 2 mm of subantral bone height

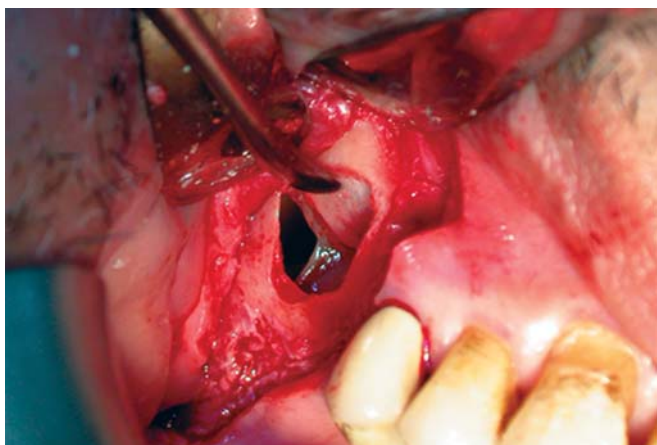


Fig. 1B: Membrane perforation of the lateral window SFE

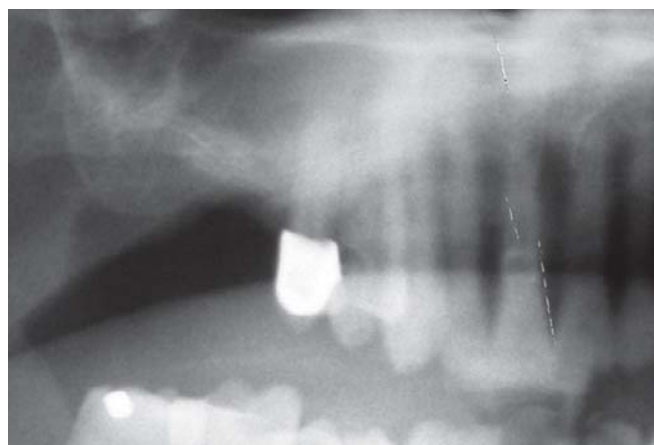

Fig. 1E: Postoperative radiograph for the 1st stage of lateral window SFE

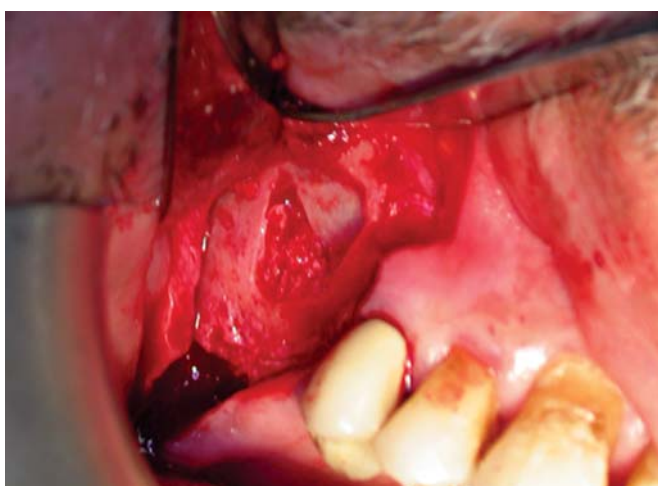


Fig. 1C: The composite graft is applied in the created defect following elevation and repair of the Schneiderian membrane

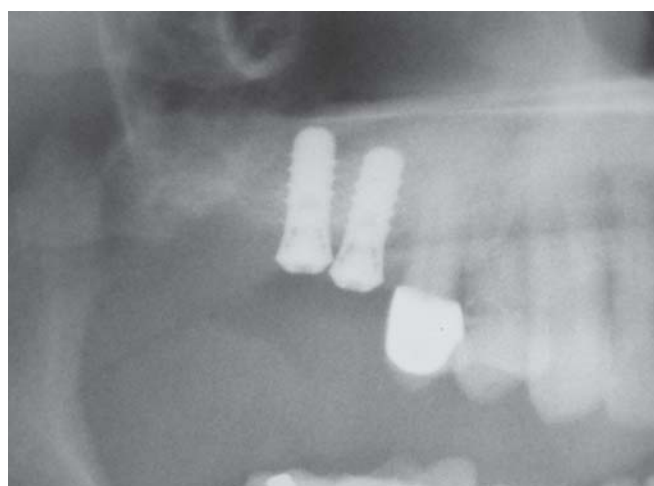

Fig. 1F: Postoperative radiograph for the 2nd stage of lateral window SFE immediately after implants placement

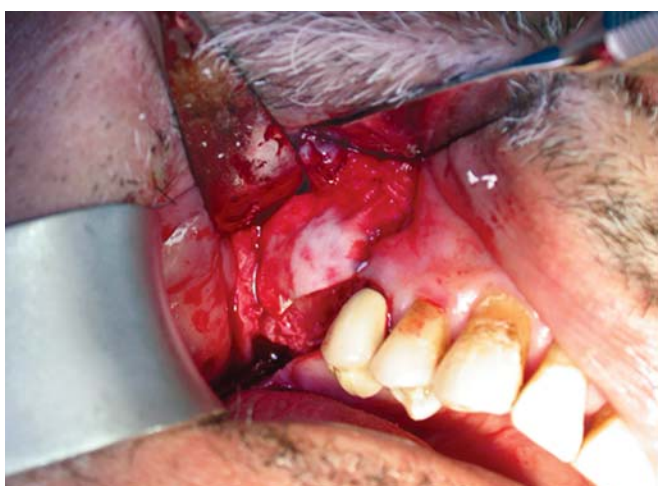

Fig. 1D: Bio-Oss granules were placed over the composite graft as a second layer for contour augmentation and covered with two layers of a collagen membrane

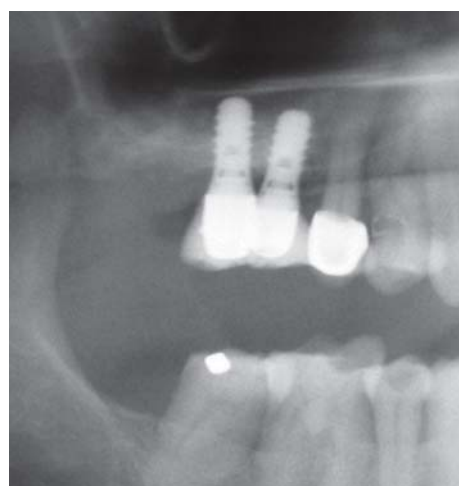


Fig. 1G: Radiograph showing a stable clinical situation 2 years after treatment and substantial increase in bone volume compared to the initial situation

A number of techniques that are commonly used for membrane perforation repair have been reported in the literature. For small membrane tears, a collagen membrane (Colla Tape, Sulzer Calcitek, Carlsbad, CA) is usually

used,¹³⁻¹⁷ or overlap of the elevated membrane can be adequate in itself.¹³ Once the resulting space had been examined and injuries to the membrane were repaired, the implants sites were prepared. Preparation of the fixture sites

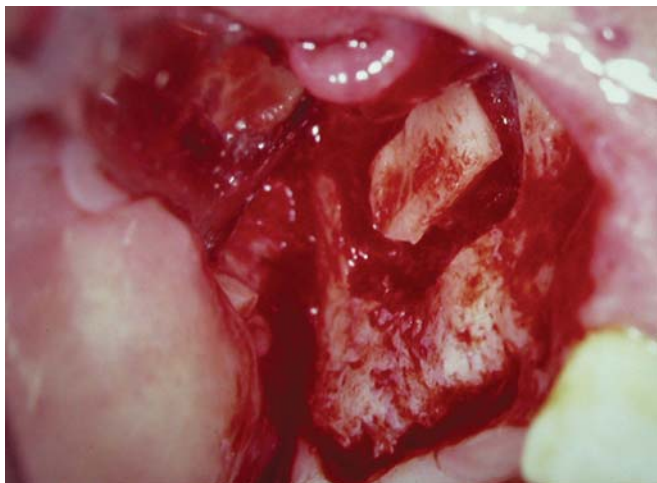


Fig. 2A: Lateral window SFE with one stage: preparation to elevate the sinus floor

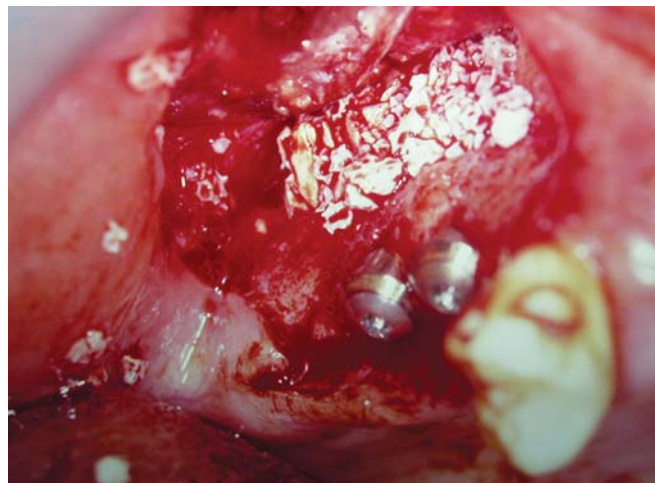


Fig. 2D: The fenestration defect was repaired by Bio-Oss granules which were placed over the implant surface for contour augmentation

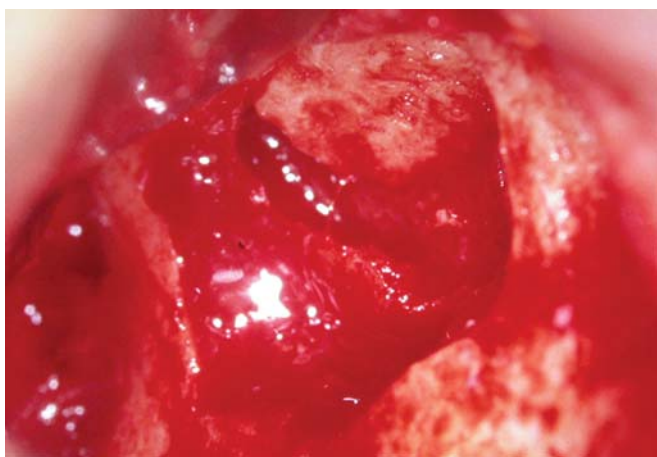


Fig. 2B: Elevation of the trap door and sinus membrane. Window size and condition are determined in accordance with anatomic condition

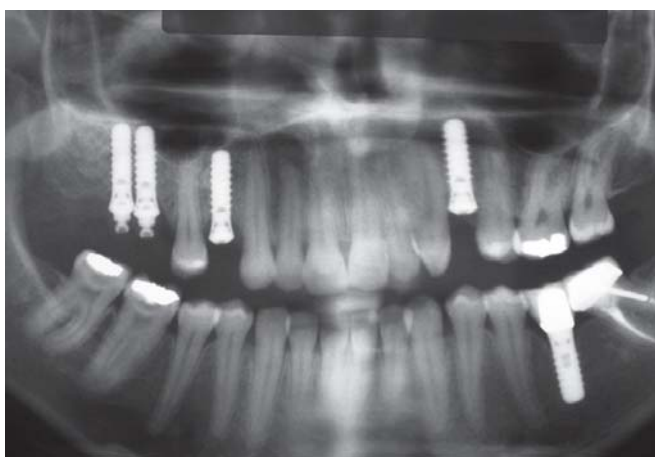

Fig. 2E: Panoramic radiographs 3 months after surgery for the right maxillary site demonstrating stable peri-implant condition

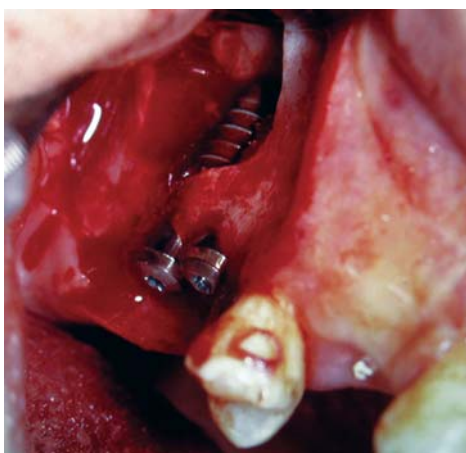


Fig. 2C: Both implants were placed with good primary stability for one stage lateral window SFE

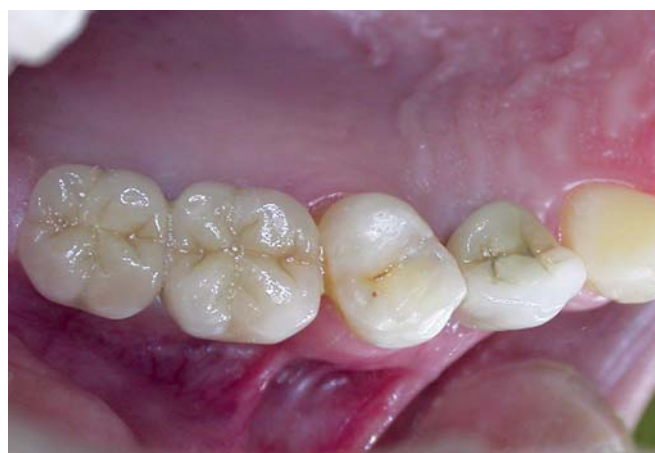

Fig. 2F: Occlusal view after cementation of the metal ceramic crowns

was undertaken using surgical guides based on waxup models and according to the standard clinical procedures for the implant system. All implants placed at the sinus lift procedures were considered to be clinically stable. At this

stage, the graft was placed. The posterior part of the cavity was grafted first, followed by the anterior portion and finally the central area. Filling material consisted of inorganic bovine bone mineral (Bio-Oss; Geistlich) mixed with

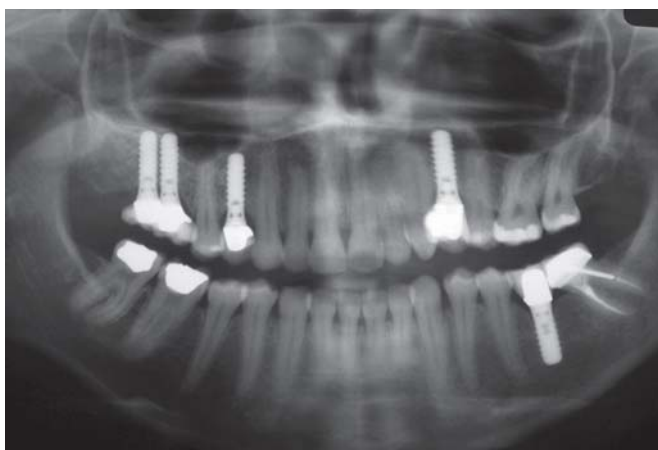


Fig. 2G: Orthopantomograph showing a stable clinical situation 2 years after treatment. A dome-shaped structure was apparent at maxillary right molars areas, indicating a substantial increase in bone volume. The dome was surrounded by a new cortical bone plate

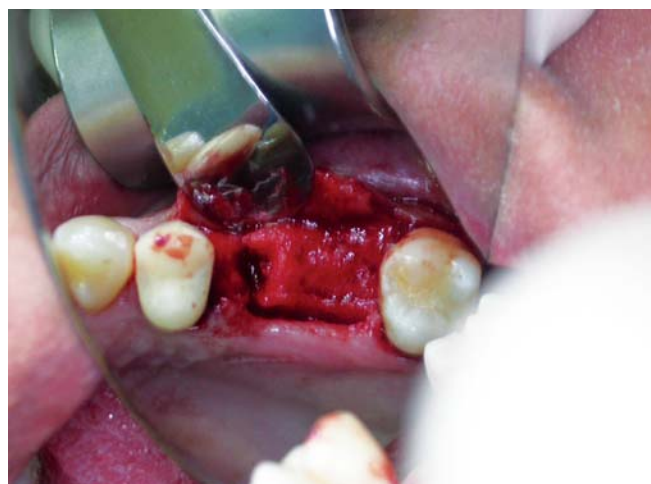

Fig. 3B: The site following the extraction of maxillary 2nd premolar

autologous bone collected from implant drilling. This grafting protocol was used in all patients. The amount of grafting material used at each site varied according to the extent of maxillary bone resorption and sinus anatomy. Care was taken not to obstruct the middle nasal meatus to allow free sinus drainage. After graft placement and packing, the mucoperiosteal flap was repositioned and sutured with monofilament sutures. For the osteotome SFE followed technique introduced by summer,⁴ was initiated, an example of the surgical procedures of OSFE procedure were performed and are visible in Figures 3A to E. The surgery lasted about 40 minutes. Upon sitting up after surgery, the patients' experienced intense vertigo with nausea, especially when they changed the position of their heads. They sat in the dental chairs and rested for 30 minutes. For osteotome approach, valsalva test to check patency of the Schneiderian membrane was noted.

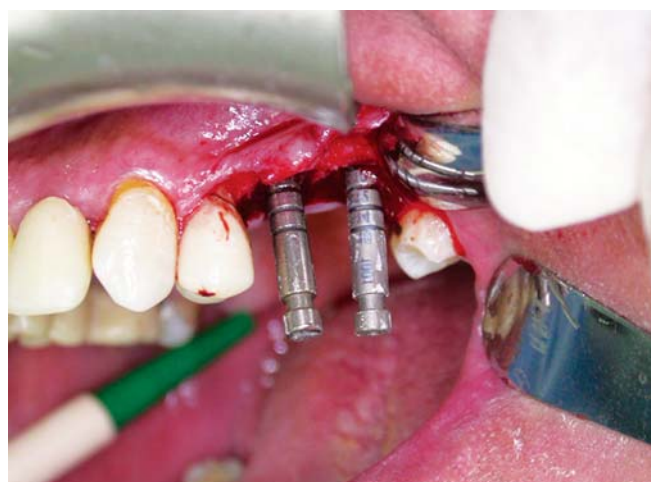


Fig. 3C: Depth gauges were used to determine the correct implants alignment, and check the integrity of the Schneiderian membrane, together with a nose-blowing test. Available space for an implant 10 mm in length is verified

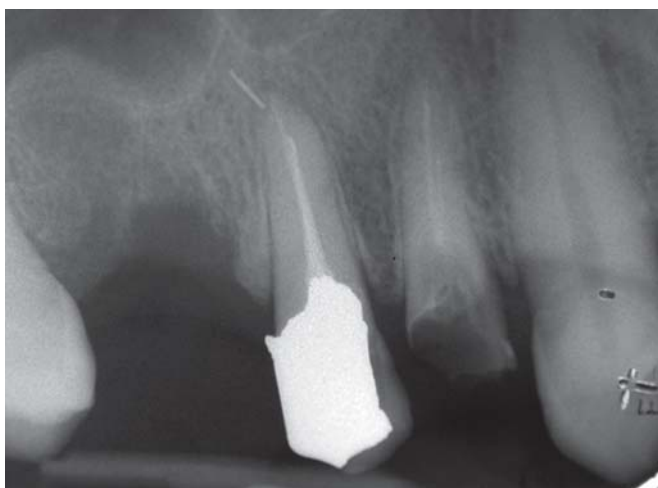

Fig. 3A: Osteotome SFE periapical radiograph of maxillary 2nd premolar indicated for extraction (broken endodontic file)

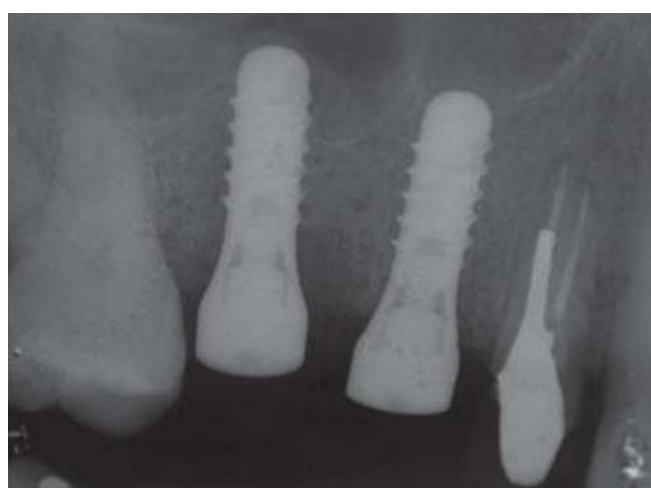

Fig. 3D: Periapical radiograph after immediate implants placement following osteotome SFE with both implants appropriately positioned and inclined

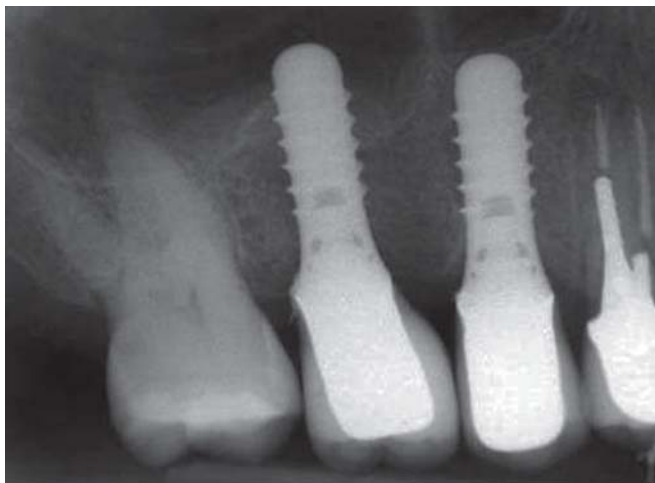

Fig. 3E: Periapical radiograph after 2 years of prosthetic loading showing stable condition at SFE site

Postoperative Care

Patients were advised to place ice bag on the maxillonasal region for 2 hours after the intervention. Patients were also advised not to blow their noses and to sneeze with an open mouth for 1 week after surgery. Patients were also instructed not to wear their dentures for 2 weeks postoperatively. In addition to standard self-performed hygiene included chlorhexidine gluconate 0.1% twice daily for the first 3 weeks after implant surgery. Since bone substitutes had been used, the patients were also placed on antibiotics for the first week.

Prosthetic Procedures

At the time of prosthodontic part for all the cases, periapical radiographs were taken to check the clinical and radiographic situation of the implants before starting the prosthetic parts. The cover screws were removed and healing caps inserted. Two weeks later, the solid abutments were

attached to the implants at the posterior sites with a torque of 35 Ncm. Impressions were taken in polyether materials (Impregum penta; 3M ESPE, seefeld, Germany) using impression baskets and position cylinders. The restorations were fabricated in the laboratory based on the master casts. Implant-supported single PFM crowns and fixed partial dentures were cemented as final reconstructions. Periapical and panoramic radiographs were taken to check the clinical and radiographic situation for these cases every 3 months for about 2 years, and to record any clinical or radiographic complications within 2 years and after treatments.

RESULTS

A total of 79 SFE procedures were performed in 60 patients (27 males and 33 females) followed with 113 ITI dental implants placements, with average age of 41.2 years (range: 29-57 years). Descriptions of SFE procedures for 60 patients were documented (Table 1).

In all cases the postoperation period were free of major complications. Complications for both procedures such as maxillary sinus perforation, and bleeding from injured vessels were reported with rate of occurrence 3.2 to 5.1%. Complications with SFE procedures were recorded (Table 2).

Vertigo was reported for all patients with osteotome approach. All the implants were presented with correct osseointegration and received single crowns or fixed prostheses. All the implants successfully fulfilled the Alberktsson et al criteria.¹⁸ By using the questionnaires; all the patients with OSFE procedures suffered dizziness accompanied with nausea immediately after sinus lift procedure and disappear within 2 to 4 weeks. No patients with lateral window approach suffered dizziness accompanied with nausea after sinus lift procedures.

Table 1: Description of SFE procedure for 60 patients

Category	Number of patients and implants
Unilateral sinus lift with lateral window	15 patients 21 implants
Unilateral sinus floor elevation with osteotome	19 patients 26 implants
Bilateral sinus lift with lateral window	09 patients 18 implants
Bilateral sinus floor elevation with osteotome	11 patients 24 implants
Bilateral combined approaches (split mouth cases)	07 patients 24 implants
Sinus lift with lateral window approach	31 procedures
Sinus lift with lateral window (one stage)	18 procedures
Sinus lift with lateral window (two stages)	13 procedures
Osteotome sinus floor elevation	48 procedures
Total sinus lift procedures	79 procedures
Total implants	113 implants

Table 2: Complications with SFE procedures

	Complications	Reported rates of occurrence
Lateral window SFE	1. Membrane perforation	2 out of 31 cases = 6.45%
	2. Poor primary stability of implant	–
	3. Bleeding from injured vessels	1 out of 31 cases = 3.2%
	4. Implant migration within the sinus	–
	5. Graft migration within the sinus	–
	6. Nerve exposure or injuries	–
Osteotome SFE	1. Sinus membrane perforation	2 out of 48 cases = 4.16%
	2. Bleeding caused by blood vessel injuries	–
	3. Poor primary stability of implant	–
	4. Dizziness accompanied with nausea immediately after the procedure (disappear after 2-4 weeks).	100%

Maxillary sinus membrane perforations occurred and small for 4 out of 79 procedures, two cases for each procedure, and had been repaired. The perforation for the lateral window procedure considered as small perforation and had been managed by leaving the membrane folding over itself when lifting; thus obviating the need for repair.^{12,19} Sinus membrane perforations for OSFE procedure were checked by having the patient blow through their nose, any air bubbles in the socket was a sign of sinus perforation (Valsalva test to check patency of the Schneiderian membrane), and managed by installing the implants into the prepared implant bed which were enough to block the small perforated site.

Radiographically, the apical elevation of the sinus floor for both procedures were observed together, with the presence of radiopaque material with greater density than the bone for lateral window procedure and radiopaque line above the apical border of the implant for OSFE procedure.

Clinically, no complication of the surgical procedure such as: infection of maxillary sinus, loss of bone particles through the nose, wound dehiscence, poor primary stability of implant, bleeding from injured vessels, implant migration within the sinus, graft migration within the sinus, and nerve exposure or injuries were noted.

No records of bone resorption at implant sites, implant failures and swelling or pain at any area close to the surgical side were noted.

DISCUSSION

With osseous atrophy in the posterior zones of the upper maxilla, due to the great predictability of the procedure and little complications encountered; currently two main approaches to the maxillary SFE procedure can be found in the literature. The first approach, lateral antrostomy, is the classic and more commonly performed technique originally described by Tatum.² More recently, Summers advocated a second approach: the crestal approach, using osteotomes.⁴ The crestal approach is considered to be a more conservative method for SFE. The most common complication during

SFE is perforations of the Schneiderian membrane,²⁰ with an incidence of 23.6 to 44%.^{9,20-23} Reported complication rates vary considerably. Perforations occur in the presence of thin membranes, septum, or sharp bony ledges as well as poor surgical management during lateral window preparation. Some perforations may require no repair as the overlap of the membrane may 'seal off' following completion of membrane elevation. They start at 12%,²⁴ in a study with 965 SFEs reviewed retrospectively. Common rates from a meta-analysis indicate 18.4%.²⁵

Two other studies described values of six perforations in 30 operations (20%) and 51 out of 216 cases (23.6%).²⁶ The highest value in the literature is 36/81 (44%).²⁰ The complications in our study showed the lower end of the reported rates, however it is all the more important to evaluate the outcome after the perforation of Schneiderian membrane and other complications.

The sinus membrane is important to avoid displacement of particular graft materials into the sinus cavity.²⁰ We used bone chips and bone substitutes (hydroxylapatite). Even small nonobserved perforations that are contingently to be overseen during surgery can pose a risk if left untreated. They should be followed and treated thoroughly, although they can fold together,^{20,26,27} and virtually disappear.

As a comparison between one or two stages for lateral window procedure, immediate implant insertion was performed only if the residual bone was stable and high enough to ascertain high primary stability as one stage procedure. When this was not possible, the implants were inserted late as two stage procedure.

Preparation of the implant beds with osteotomes and a surgical mallet transmits percussive forces capable of detaching heavy, inorganic particles (otoliths) from the otoconia layer of the utricular macula.^{5,7,28} Moreover, during surgical positioning of the patient face up and his head in hyperextension favor the displacement of otoliths into the posterior semicircular canal,^{5-7,28,29} (canalithiasis; i.e. that which is free floating from the macula and gravitates into the endolymph of the semicircular canal). Then the otoliths

float around in the gravity-sensitive endolymph system, causing vertigo.²⁸ These disturbances are almost in the plane of the posterior semicircular canal, although in some cases the other semicircular canal is affected.⁶ The diagnosis of BPPV is established by inducing a rapid change from the sitting position to the left or right head-hanging position.^{5,30,31} Patients with BPPV experience vertigo when moved rapidly into a supine position with the head turned so that the affected ear is 30 to 45° below the horizontal plane.^{2,3,10} The vertigo occurs with a latency of 1 to 40 seconds after the patient has been placed in the provoked position (usually after 1 to 5 seconds).^{5,31,32} Although BPPV is a 'self-limiting' disorder and commonly resolves itself within a month,³¹ the symptoms involved are very unpleasant for the patient. Therefore, implant surgeons must resolve this condition quickly with appropriate treatment. The symptoms of vertigo due to many different underlying etiologies are commonly treated with medications.³³ Clinicians may prescribe pharmacological management to either reduce the spinning sensation of vertigo and/or to reduce the accompanying motion sickness symptoms. The most commonly used are benzodiazepines and antihistamines. Benzodiazepines, such as diazepam, and clonazepam, have anxiolytic, sedative, muscle relaxant, and anticonvulsant properties derived from potentiating the inhibitory effect of the gamma-amino butyric acid system. Antihistamines, on the other hand, appear to have a suppressive effect on the central emetic center which relieves the nausea and vomiting associated with motion sickness. Common examples of antihistamines used to treat symptoms of vertigo and/or associated motion sickness include meclizine and diphenhydramine. Motion sickness medications are sometimes helpful in controlling the nausea, but are generally not very beneficial.^{28,33} The clinician should know about and expect BPPV after the osteotome technique. To prevent this complication, gentle malleting and a careful approach should be taken during the osteotome technique.

CONCLUSION

Based on the results of this study, SFE surgery is a safe and effective method of increasing vertical height in the posterior maxilla. Up to 24 months, though complications have not been shown to have an adverse effect on maxillary sinus function nor implant survival, it may be possible that successful resolution of these problems mitigate their influence on implant survival. Therefore, identification and management of potential complications are necessary and important to the success, long-term maxillary sinus function and stability of dental implants.

CLINICAL SIGNIFICANCE

The clinician performs SFE with either lateral window or osteotome procedures needs to understand the difficulties and morbidity arising in the event of complications and must be able to correctly judge the individual risk and the presence of modifying factors that may cause these complications.

REFERENCES

1. Pietrokovski J. The bony residual ridge in man. *J Prosthet Dent* 1975;34:456-462.
2. Tatum H. Maxillary and sinus implant reconstructions. *Dent Clin North Am* 1986;30:207-229.
3. Boyne PJ, James RA. Grafting of the maxillary sinus floor with autologous marrow and bone. *J Oral Surg* 1980;38:613-616.
4. Summers RB. The osteotome technique: Part 3: less invasive methods of elevating the sinus floor. *Compendium* 1994;15:698-708.
5. Su GN, Tai PW, Su PT, Chien HH. Protracted benign paroxysmal positional vertigo following osteotome sinus floor elevation: a case report. *Int J Oral Maxillofac Implants* 2008;23:955-959.
6. Penarrocha M, Rambla J, Perez V, Perez H. Benign paroxysmal vertigo secondary to placement of maxillary implants using the alveolar expansion technique with osteotomes: a study of 4 cases. *Int J Oral Maxillofac Implants* 2008;23:129-132.
7. Penarrocha M, Perez H, Garcia A, Guarinos J. Benign paroxysmal positional vertigo as a complication of osteotome expansion of the maxillary alveolar ridge. *J Oral Maxillofac Surg* 2001;59:106-107.
8. Torrella F, Pitarch J, Cabanes G, Anitua E. Ultrasonic osteotomy for the surgical approach of the maxillary sinus: a technical note. *Int J Oral Maxillofac Implants* 1998;13:697-700.
9. Barone A, Santini S, Sbordone L, Crespi R, Covani U. A clinical study of the outcomes and complications associated with maxillary sinus augmentation. *Int J Oral Maxillofac Implants* 2006;21:81-85.
10. Sorní M, Guarinós J, García O, Peñarrocha M. Implant rehabilitation of the atrophic upper jaw: a review of the literature since 1999. *Med Oral Patol Oral Cir Bucal* 2005;10(Suppl 1): E45-56.
11. Chanavaz, M. Maxillary sinus: anatomy, physiology, surgery, and bone grafting related to implantology – eleven years of surgical experience (1979-1990). *J Oral Implantol* 1990;16:199-209.
12. Betts NJ, Miloro M. Modification of the sinus lift procedure for septa in the maxillary antrum. *J Oral Maxillofac Surg* 1994;52: 332-333.
13. Misch CE. Maxillary sinus lift and elevation with subantral augmentation. *Contemp Implant Dent* 1993;25:545-574.
14. Wheeler SW. Six-year clinical and histologic study of sinus-lift grafts. *Int J Oral Surg* 1996;11(1):26-34.
15. Vassos DM, Petrik PK. The sinus lift procedure: An alternative to the maxillary subperiosteal implant. *Pract Periodontic Aesthet Dent* 1992;4:14-19.
16. Smiler DG. The sinus lift graft: basic technique and variations. *Pract Periodontic Aesthet Dent* 1997;9:885-893.
17. Block MS, Kent JN. Maxillary sinus bone grafting. *Atlas Oral Maxillofac Clin North Am* 1994;2:63-76.
18. Albrektsson T, Zarb G, Worthington P, Eriksson AR. The long-

- term efficacy of currently used dental implants: a review and proposed criteria of success. *Int J Oral Maxillofac Implants* 1986 Summer;1(1):11-25.
19. Van den Bergh JP, ten Bruggenkate CM, Disch FJ, Tuinzing DB. Anatomical aspects of sinus floor elevations. *Clin Oral Implants Res* 2000a;11:256-265.
 20. Schwartz-Arad D, Herzberg R, Dolev E. The prevalence of surgical complications of the sinus graft procedure and their impact on implant survival. *J Periodontol* 2004;75:511-516.
 21. Khoury F. Augmentation of the sinus floor with mandibular bone block and simultaneous implantation: a 6-year clinical investigation. *Int J Oral Maxillofac Implants* 1999;14:557-564.
 22. Jensen OT, Shulman LB, Block MS, Iacono VJ. Report of the Sinus Consensus Conference of 1996. *Int J Oral Maxillofac Implants* 1998;13:11-45.
 23. Becker ST, Terheyden H, Steinriede A, Behrens E, Springer I, Wiltfang J. Prospective observation of 41 perforations of the Schneiderian membrane during sinus floor elevation. *Clin Oral Implant Res* 2008;19(12):1285-1289.
 24. Szabo G, Toth CH. Komplikationshäufigkeiten beim sinus-lift. *Z Zahnärztl Implantol* 2001;17:132-134.
 25. Kreisler M, Moritz O, Weihe CH, d'Hoedt B. Die externe sinusbodenelevation vor dem hintergrund der evidenzbasierten medizinen. *Z Zahnärztl Implantol* 2007;23:68-86.
 26. Van den Bergh JP, ten Bruggenkate CM, Krekeler G, Tuinzing DB. Maxillary sinus floor elevation and grafting with human demineralized freeze dried bone. *Clin Oral Implants Res* 2000b;11:487-493.
 27. Aimetti M, Romagnoli R, Ricci G, Massei G. Maxillary sinus elevation: the effect of macrolacerations and microlacerations of the sinus membrane as determined by endoscopy. *Int J Periodontics Restorative Dent* 2001;21:581-589.
 28. Saker M, Ogle O. Benign paroxysmal positional vertigo subsequent to sinus lift via closed technique. *J Oral Maxillofac Surg* 2005;63:1385-1387.
 29. Di Girolamo M, Napolitano B, Arullani CA, Bruno E, Di Girolamo S. Paroxysmal positional vertigo as a complication of osteotome sinus floor elevation. *Eur Arch Otorhinolaryngol* 2005;262:631-633.
 30. Kaplan DM, Attal U, Kraus M. Bilateral benign paroxysmal positional vertigo following a tooth implantation. *J Laryngol Otol* 2003;117:312-313.
 31. Dix MR, Hallpike CS. The pathology symptomatology and diagnosis of certain common disorders of the vestibular system. *Proc R Soc Med* 1952;45:341-354.
 32. Herdman SJ. Treatment of benign paroxysmal positional vertigo. *Phys Ther* 1990;70:381-388.
 33. Bhattacharyya N, Baugh RF, Orvidas L, Barrs D, Bronston LJ, Cass S, et al. Clinical practice guideline: benign paroxysmal positional vertigo. *Otolaryngol Head Neck Surg* 2008;139: S47-81.

ABOUT THE AUTHORS

Saad Al-Almaie (Corresponding Author)

Consultant Prosthodontist, Implantologist and Chairman of Supervising Committee, SBARD Board Program, Eastern Province Program Director for SSC-Prosthodontic Board Program, KFMMC Department of Dental Surgery, Military Medical Complex Eastern Dhahran, Saudi Arabia, e-mail: stsralmaie@yahoo.com

Abdul Majeed Kavarodi

Consultant, Maxillofacial Surgeon, King Fahd Military Medical Complex, Dhahran, Saudi Arabia

Abdullah Al Faidhi

Consultant, Plastic and Craniomaxillofacial Surgeon, King Fahd Armed Forces Hospital, Jeddah, Saudi Arabia